

Acute pancreatitis due to intragastric balloon

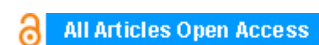
Orlando Jorge Martins Torres, Jose Maria Assunção Moraes-Junior, Camila Cristina S. Torres, Everardo de Almeida Nunes

ABSTRACT


Introduction: Intragastric balloon therapy is an option for treatment of obesity. Some complications have been reported but acute pancreatitis due to compression of the pancreas is a rare event. The aim of this study is report a case of acute pancreatitis due to intragastric balloon insertion.

Case Report: In a 33-year-old male with BMI of 43.4 kg/m², intragastric balloon was inserted in the gastric fundus, the follow-up was uneventful. After four months, the patient had acute abdominal pain, nausea, vomiting and abdominal distension. Laboratory tests showed serum amylase 618 U/l and serum lipase 906 U/l. A CT scan showed that the tail of the pancreas was heterogeneous, minimal fluid and inflammation of peripancreatic fat. The intragastric balloon was observed causing compression at the transition from the body to the pancreatic tail. The intragastric balloon was removed and the patient underwent laparoscopic cholecystectomy. The inspection of the gallbladder was normal and the histology showed no signs of microlithiasis. The patient was discharged asymptomatic.

Conclusion: Intragastric balloon is a common procedure in obese patients and pancreas compression due to the balloon should be included as cause of acute pancreatitis in these patients.



International Journal of Case Reports and Images (IJCRI)



International Journal of Case Reports and Images (IJCRI) is an international, peer reviewed, monthly, open access, online journal, publishing high-quality, articles in all areas of basic medical sciences and clinical specialties.

Aim of IJCRI is to encourage the publication of new information by providing a platform for reporting of unique, unusual and rare cases which enhance understanding of disease process, its diagnosis, management and clinico-pathologic correlations.

IJCRI publishes Review Articles, Case Series, Case Reports, Case in Images, Clinical Images and Letters to Editor.

Website: www.ijcasereportsandimages.com

Acute pancreatitis due to intragastric balloon

Orlando Jorge Martins Torres, Jose Maria Assunção Moraes-Junior,
Camila Cristina S. Torres, Everardo de Almeida Nunes

ABSTRACT

Introduction: Intragastric balloon therapy is an option for treatment of obesity. Some complications have been reported but acute pancreatitis due to compression of the pancreas is a rare event. The aim of this study is report a case of acute pancreatitis due to intragastric balloon insertion. **Case Report:** In a 33-year-old male with BMI of 43.4 kg/m², intragastric balloon was inserted in the gastric fundus, the follow-up was uneventful. After four months, the patient had acute abdominal pain, nausea, vomiting and abdominal distension. Laboratory tests showed serum amylase 618 U/l and serum lipase 906 U/l. A CT scan showed that the tail of the pancreas was heterogeneous, minimal fluid and inflammation of peripancreatic fat. The intragastric balloon was observed causing compression at the transition from the body to the pancreatic tail. The intragastric balloon was removed and the patient underwent laparoscopic cholecystectomy. The inspection of the gallbladder was normal and the histology

showed no signs of microlithiasis. The patient was discharged asymptomatic. **Conclusion:** Intragastric balloon is a common procedure in obese patients and pancreas compression due to the balloon should be included as cause of acute pancreatitis in these patients.

Keywords: Acute pancreatitis, Intragastric balloon, Obesity, Pancreatitis

How to cite this article

Torres OJM, Moraes-Junior JMA, Torres CCS, Nunes EA. Acute pancreatitis due to intragastric balloon. Int J Case Rep Images 2016;7(8):499–502.

Article ID: Z01201608CR10675OT

doi:10.5348/ijcri-201687-CR-10675

Orlando Jorge Martins Torres¹, Jose Maria Assunção Moraes-Junior², Camila Cristina S. Torres¹, Everardo de Almeida Nunes²

Affiliations: ¹MD, Department of Gastrointestinal Surgery, Federal University of Maranhão, Brazil; ²MD, Department of Endoscopy - UDI Hospital, São Luis, MA, Brazil.

Corresponding Author: Orlando Jorge M. Torres, Full Professor and Chairman, Department of Gastrointestinal Surgery – Address: Rua dos Bicudos 14/600.Ed. Aspen. 65075-090 – São Luís-MA. Brazil; Email: o.torres@uol.com.br

Received: 18 February 2016

Accepted: 20 April 2016

Published: 01 August 2016

INTRODUCTION

Obesity is considered an epidemic disease, a serious public health problem and associated with morbidity, mortality and quality of life. In addition, obesity is an independent risk factor for death. Obesity treatment options include medical treatment, endoscopic and surgery. Medication has been reported to be ineffective in the long-term treatment, and intragastric balloon and bariatric surgery have been shown to result in substantial weight reduction. Intragastric balloon therapy is indicated for temporary use and has been established as a part of a multidisciplinary weight management program. The application is easy and has low morbidity and mortality

[1]. Some common complications included abdominal pain, nausea, vomiting and discomfort. There are also a few reported cases of esophagitis, gastritis, small bowel obstruction, antral impaction and gastric perforation. Compression of the pancreas by intra-gastric balloon leading to acute pancreatitis has been a rare event [2, 3]. The aim of this study is to present a rare complication of acute pancreatitis due to intragastric balloon used for treatment of obesity.

CASE REPORT

A 33-year-old male, clinical doctor, was referred from the Department of endocrinology to the Department of Gastroenterology and Digestive Endoscopy for management of obesity. His BMI was 43.4 kg/m² (weight 127 kg and height 171 cm). The intragastric balloon was inserted in the gastric fundus, uneventful and the procedure was tolerated very well. Within four months, he lost approximately 22 kg. From this date, the patient began to have abdominal pain, nausea and vomiting of moderate intensity. One week later, he presented sudden acute abdominal pain, nausea, vomiting and abdominal distension. The patient was taken to the emergency department and treated initially with symptomatic. The patient had no history of alcohol consumption. Laboratory tests showed leukocytosis and normal renal function. Serum amylase was 618 U/l, serum lipase was 906 U/l. Total bilirubin was 0.8 mg/dl, alanine aminotransferase (ALT), aspartate aminotransferase (AST), alkaline phosphatase (ALP), and gamma-glutamyl transpeptidase (GGT), were all normal. Transabdominal ultrasonography revealed a normal gallbladder without stones or biliary sludge and the bile duct diameter was 4 mm. A computed tomography scan of the abdomen was performed and showed that the tail of the pancreas was heterogeneously enhanced, with indistinct margins due to inflammation of peripancreatic fat. Some stranding and minimal fluid was also present. The intragastric balloon was also observed causing compression at the transition from the body to the pancreatic tail (Figures 1 and 2). A systematic investigation for other causes of acute pancreatitis was conducted. The diagnosis of acute pancreatitis due to compression by intragastric balloon was made.

An upper gastrointestinal endoscopy was performed, and the intragastric balloon was removed. A week later, the patient underwent laparoscopic cholecystectomy. The inspection of the mucosa of the gallbladder was normal and there was no gallstone or biliary sludge. The histopathologic study showed no signs of microlithiasis or cholecystitis. The postoperative course was uneventful, the amylase and lipase levels came back to normal and the patient was discharged asymptomatic.

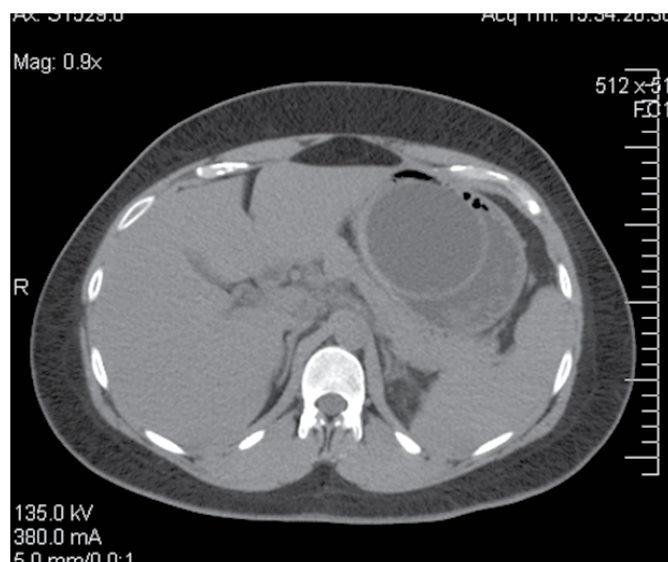


Figure 1: Computed tomography scan of the abdomen showing compression of the pancreas by the intragastric balloon.

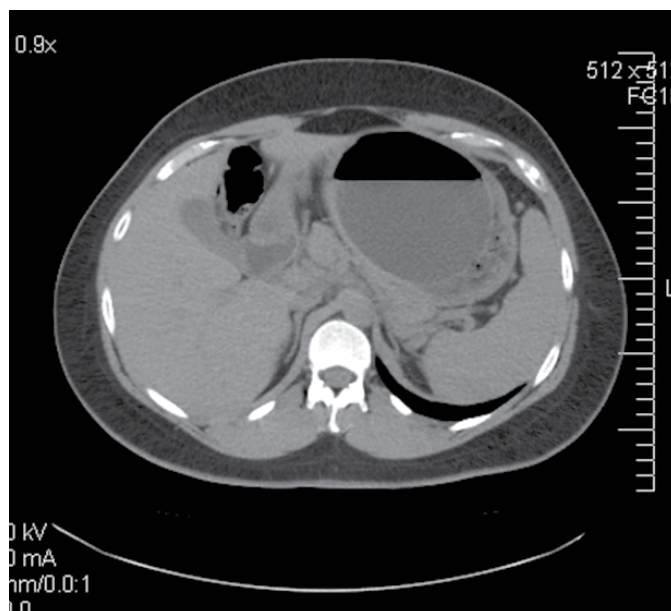


Figure 2: Computed tomography scan of the abdomen showing edema in the tail of the pancreas.

DISCUSSION

Acute pancreatitis is defined by Atlanta classification as abdominal pain that suggest pancreatitis, levels of serum amylase and lipase three or more times the normal value and imaging with characteristics findings. The process of acute pancreatitis can evolve the whole pancreas and cause reactions in many others organs. A variety of conditions can cause acute pancreatitis, but gallstones are implicated in the majority of cases. Others causes are alcohol abuse, hyperlipidemia, drugs

and endoscopic retrograde cholangiopancreatography. Mechanical causes of acute pancreatitis occur due to obstruction of the pancreatic duct or by direct trauma to the pancreas. Although the mechanism is not well defined, the nature and severity of the obstruction appear to influence the course of the disease. Acute pancreatitis with slow ductal obstruction due to pancreatic cancer is rare [2].

Pancreatic trauma may cause acute pancreatitis by a crash injury, transection of the pancreas or can result in injury of ductal structures. The diagnosis is suspected based on the clinical findings, although sometimes a blunt trauma may confuse the pancreas where it crosses the spine [2–4]. In this case, compression of the pancreas and its duct by the inflated balloon was responsible for acute pancreatitis, but we have to rule out others causes of acute pancreatitis like gallstones.

Normally, the balloon is located at the fundus of the stomach, without relation to the pancreas. In this case, on the contrary, the balloon was in contact with the pancreas leading to compression of the pancreatic duct and pancreatitis. Intra-gastric balloon is a common procedure in obese patients and pancreas compression due to the balloon should be included as cause of acute pancreatitis in these patients as observed by Mohammed et al. [3–6]. Others common complications of intra-gastric balloon are pain, nausea, vomiting and discomfort. Uncommon complications have been reported as esophagitis, gastritis and gastric perforation. After the diagnosis is confirmed, the intra-gastric balloon must be removed [3, 5, 6].

CONCLUSION

Intra-gastric balloon is a common procedure in obese patients and pancreas compression due to the balloon should be included as cause of acute pancreatitis in these patients.

Author Contributions

Orlando Jorge Martins Torres – Substantial contributions to conception and design, Acquisition of data, Analysis and interpretation of data, Drafting the article, Revising it critically for important intellectual content, Final approval of the version to be published

Jose Maria Assunção Moraes-Junior – Acquisition of data, Analysis and interpretation of data, Revising it critically for important intellectual content, Final approval of the version to be published

Camila Cristina S. Torres – Acquisition of data, Analysis and interpretation of data, Revising it critically for important intellectual content, Final approval of the version to be published

Everardo de Almeida Nunes – Acquisition of data, Analysis and interpretation of data, Revising it critically

for important intellectual content, Final approval of the version to be published

Guarantor

The corresponding author is the guarantor of submission.

Conflict of Interest

Authors declare no conflict of interest.

Copyright

© 2016 Orlando Jorge Martins Torres et al. This article is distributed under the terms of Creative Commons Attribution License which permits unrestricted use, distribution and reproduction in any medium provided the original author(s) and original publisher are properly credited. Please see the copyright policy on the journal website for more information.

REFERENCES

1. Machytka E, Klvana P, Kornbluth A, et al. Adjustable intra-gastric balloons: a 12-month pilot trial in endoscopic weight loss management. *Obes Surg* 2011 Oct;21(10):1499–507.
2. Banks PA, Bollen TL, Dervenis C, et al. Classification of acute pancreatitis--2012: revision of the Atlanta classification and definitions by international consensus. *Gut* 2013 Jan;62(1):102–11.
3. Mohammed AE, Benmoussa A. Acute pancreatitis complicating intra-gastric balloon insertion. *Case Rep Gastroenterol* 2008 Sep 20;2(3):291–5.
4. Vongsuvan R, Pleass H, van der Poorten D. Acute necrotizing pancreatitis, gastric ischemia, and portal venous gas complicating intra-gastric balloon placement. *Endoscopy* 2012;44 Suppl 2 UCTN:E383–4.
5. Genco A, López-Nava G, Wahlen C, et al. Multi-centre European experience with intra-gastric balloon in overweight populations: 13 years of experience. *Obes Surg* 2013 Apr;23(4):515–21.
6. Hegade VS, Sood R, Douds AC. Small bowel obstruction induced by spontaneous partial deflation of an intra-gastric balloon. *Ann R Coll Surg Engl* 2012 May;94(4):e171–3.

Access full text article on
other devices



Access PDF of article on
other devices



Edorium Journals: An introduction

Edorium Journals Team

About Edorium Journals

Edorium Journals is a publisher of high-quality, open access, international scholarly journals covering subjects in basic sciences and clinical specialties and subspecialties.

Invitation for article submission

We sincerely invite you to submit your valuable research for publication to Edorium Journals.

But why should you publish with Edorium Journals?

In less than 10 words - we give you what no one does.

Vision of being the best

We have the vision of making our journals the best and the most authoritative journals in their respective specialties. We are working towards this goal every day of every week of every month of every year.

Exceptional services

We care for you, your work and your time. Our efficient, personalized and courteous services are a testimony to this.

Editorial Review

All manuscripts submitted to Edorium Journals undergo pre-processing review, first editorial review, peer review, second editorial review and finally third editorial review.

Peer Review

All manuscripts submitted to Edorium Journals undergo anonymous, double-blind, external peer review.

Early View version

Early View version of your manuscript will be published in the journal within 72 hours of final acceptance.

Manuscript status

From submission to publication of your article you will get regular updates (minimum six times) about status of your manuscripts directly in your email.

Our Commitment

Six weeks

You will get first decision on your manuscript within six weeks (42 days) of submission. If we fail to honor this by even one day, we will publish your manuscript free of charge.*

Four weeks

After we receive page proofs, your manuscript will be published in the journal within four weeks (31 days). If we fail to honor this by even one day, we will publish your manuscript free of charge and refund you the full article publication charges you paid for your manuscript.*

Favored Author program

One email is all it takes to become our favored author. You will not only get fee waivers but also get information and insights about scholarly publishing.

Institutional Membership program

Join our Institutional Memberships program and help scholars from your institute make their research accessible to all and save thousands of dollars in fees make their research accessible to all.

Our presence

We have some of the best designed publication formats. Our websites are very user friendly and enable you to do your work very easily with no hassle.

Something more...

We request you to have a look at our website to know more about us and our services.

* Terms and condition apply. Please see Edorium Journals website for more information.

We welcome you to interact with us, share with us, join us and of course publish with us.



Edorium Journals: On Web



Browse Journals

CONNECT WITH US

