



Contents lists available at ScienceDirect

International Journal of Surgery Case Reports

journal homepage: www.casereports.com

The ALPPS procedure for hepatocellular carcinoma larger than 10 centimeters



Orlando Jorge M. Torres*, Rodrigo Rodrigues Vasques, Thiago Henrique S. Silva, Miguel Eugenio L. Castelo-Branco, Camila Cristina S. Torres

Department of Digestive Surgery, Federal University of Maranhão, São Luiz, MA, Brazil

ARTICLE INFO

Article history:

Received 10 June 2016

Received in revised form 2 July 2016

Accepted 22 July 2016

Available online 28 July 2016

ABSTRACT

INTRODUCTION: The only means of achieving long-term survival in hepatocellular carcinoma is complete tumor resection or liver transplantation. Patients with large hepatocellular carcinomas are currently not considered for liver transplantation. Associating liver partition and portal vein ligation for staged hepatectomy (ALPPS) is indicated in selected patients. We present the case of a patient with a huge hepatocellular carcinoma who underwent an ALPPS procedure. **PRESENTATION OF CASE:** A 57-year-old man initially presented with a tumor measuring 19 cm × 10 cm in the right lobe of the liver. The liver function was normal and there was no evidence of portal hypertension. The first part of the procedure was performed without mobilizing the liver. The middle hepatic vein was divided during parenchymal transection. The second procedure was performed after 15 days. During that procedure the right hepatic artery, right bile duct, and the right hepatic vein were ligated and divided. Liver segments 4–8 with the tumor were removed. The patient developed moderate ascites but recovered after ten days. After 90 days, the patient is doing well with no signs of recurrence.

DISCUSSION: Hepatocellular carcinoma is a complicated disease and ALPPS is not considered an optimal treatment option. However, patients with large tumors are not considered for liver transplantation or chemotherapy. Patients with Child-Pugh A liver disease without portal hypertension can benefit from surgical treatment for hepatocellular carcinoma; in some situations, surgery may be considerably better than other forms of treatment.

CONCLUSION: ALPPS should be considered in selected patients with large hepatocellular carcinomas.

© 2016 The Author(s). Published by Elsevier Ltd on behalf of IJS Publishing Group Ltd. This is an open access article under the CC BY-NC-ND license (<http://creativecommons.org/licenses/by-nc-nd/4.0/>).

1. Introduction

Hepatocellular carcinoma (HCC) is one of the most common cancers worldwide, and occurs mainly in chronic liver disease or cirrhosis [1].

The only means of achieving chances to obtain long-term survival is complete tumor resection or liver transplantation. According to tumor size, HCC larger than 10 cm is defined as very large. The prognosis is poor and is associated with satellite nodules, macroscopic vascular invasion, and extra hepatic metastasis. Surgical resection is indicated in case of a single tumor of any size, Child-Pugh class A, without portal hypertension or extra hepatic disease [1,2].

Associating liver partition and portal vein ligation for staged hepatectomy (ALPPS) is an important procedure to induce rapid liver hypertrophy. The main indications for ALPPS are extensive

bilobar colorectal liver metastases with a future liver remnant <25% [3,4]. According to the first international consensus meeting on ALPPS, the procedure is indicated in selected patients with HCC [5]. We present the case of a patient with HCC larger than 10 centimeters who underwent an ALPPS procedure.

2. Presentation of case

A 57-year-old man presented with epigastric discomfort and weight loss. He had a history of heavy alcohol consumption, but no history of hepatitis virus infection. Contrast-enhanced computed tomography (CT) was performed which revealed a large tumor measuring 19 cm × 10 cm in segments 4–8, right portal vein thrombosis, and no signs of liver cirrhosis (Fig. 1). Liver function evaluation revealed albumin 3.8 g/dL, creatinine 1.2 mg/dL, international normalized ratio (INR) 1.0, and serum bilirubin 1.1 mg/dL; he had, no ascites, no encephalopathy, a Child-Pugh score of A5, Model for End-stage Liver Disease (MELD) score of 9, and a platelet count of $123 \times 10^3/\text{mm}^3$. The alpha-fetoprotein (AFP) level was 508 ng/mL. The case was discussed in a multidisciplinary meeting and ALPPS was indicated.

* Corresponding author.

E-mail addresses: o.torres@uol.com.br, orlando.torres@huufma.br (O.J.M. Torres).

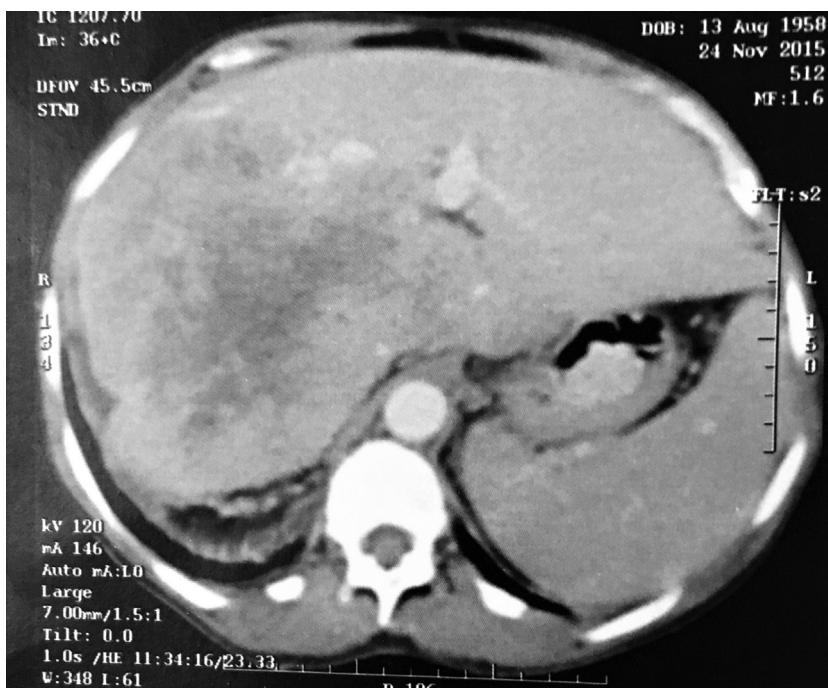


Fig. 1. CT with huge HCC.

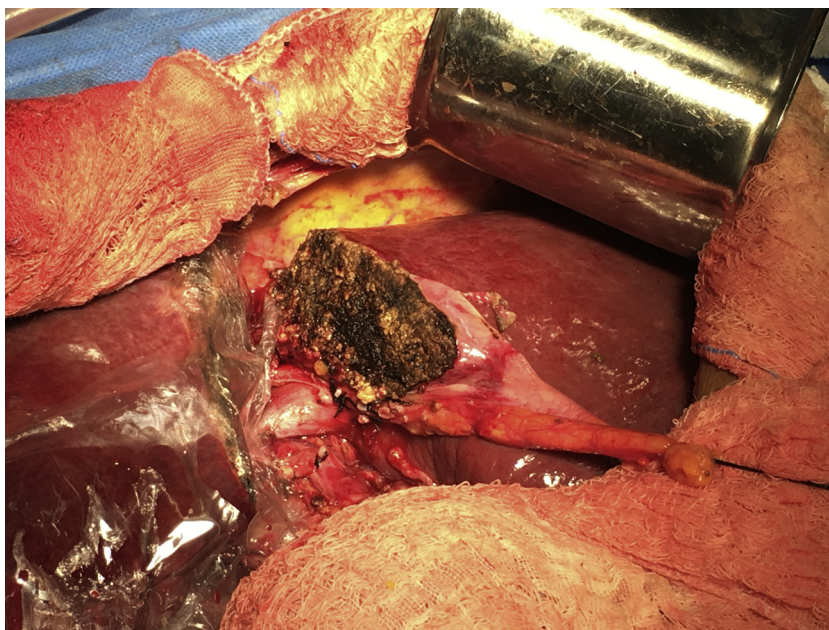


Fig. 2. ALPPS first procedure with plastic bag.

After preoperative evaluation the patient underwent surgery. A modified Makuuchi incision was used. A thorough exploration of the abdomen was performed to assess and stage the liver tumors. During the first procedure, the liver was not mobilized in order to avoid adhesions in the second operation. The right portal vein was dissected and doubly ligated with a 2.0 silk tie and was not divided. Pedicles to segment 4 were ligated and divided. The transection of the liver parenchyma was performed at 1 cm on the right side of the falciform ligament using bipolar coagulation irrigated with saline solution. The anterior approach was performed in order to avoid tumor manipulation. An intermittent Pringle maneuver was performed during the parenchymal transection. The middle hepatic

vein was divided during the transection, preserving the left hepatic vein. The cut surface of the right liver was protected with a sterile plastic bag for laparoscopy (Esterili-Med[®]) fixed with 3.0 prolene, and a hemostatic sponge (Surgicel[®], Ethicon) was used on the left side (Fig. 2). A silicone drain was placed on the transection line of the liver and the abdomen was closed. The operating time was 175 min, the blood loss was 600 mL, and no blood transfusion was necessary after this procedure.

After 15 days, abdominal CT was performed and showed significant hypertrophy of the left lobe (Fig. 3).

The second operation started with the same incision and mobilization of the right liver from the vena cava. The plastic bag was

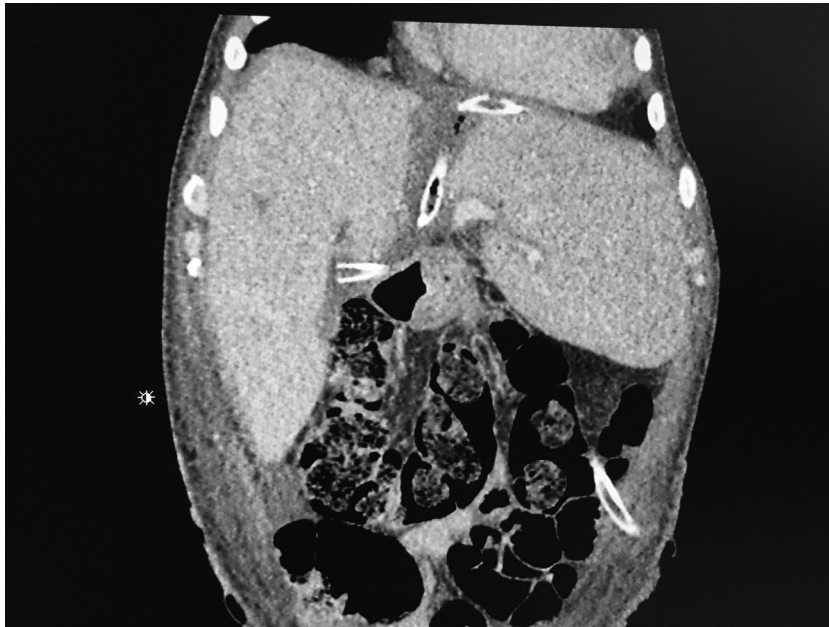

Fig. 3. CT 15 days after the first procedure.

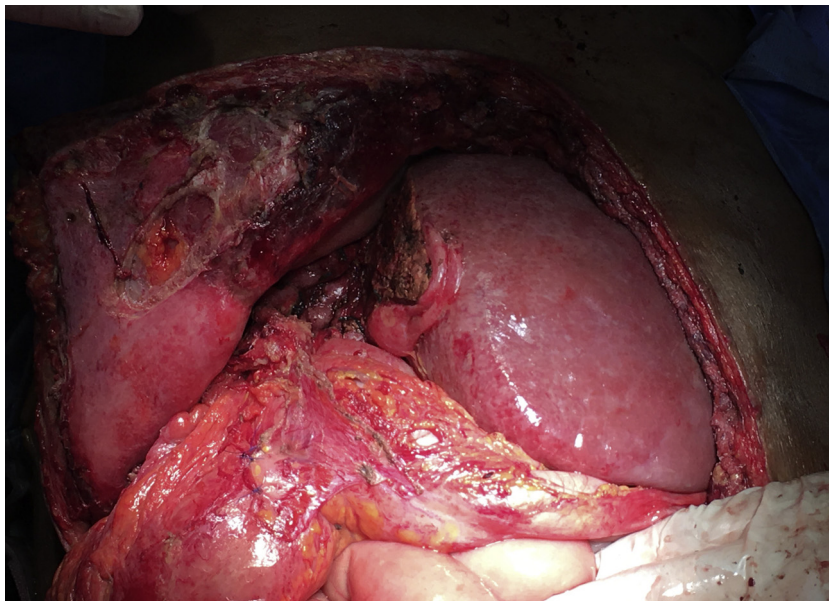


Fig. 4. Final aspect of the liver remnant.

removed from the right extended lobe. The right hepatic artery, the right bile duct, and the right hepatic vein were ligated and divided. Liver segments 4–8 with the tumor were removed (Figs. 4 and 5). Two silicone drains were placed and the abdomen closed. The patient was sent to the intensive care unit, and an oral diet was started on the second postoperative day. The operating time was 246 min, the blood loss was 1200 mL and two units of blood were transfused after this procedure. After the second procedure, the patient developed moderate ascites that was clinically treated. No bile leak was observed and his liver function recovered well after ten days.

Histopathology confirmed a 19.4 cm × 10.5 cm HCC, steatosis, tumor necrosis, and presence of microscopic vascular invasion. The resection margins were clear and the normal liver parenchyma showed chronic hepatitis. The postoperative course was unevent-

ful and the patient was discharged 28 days after the first procedure. After 90 days of follow-up, the patient is well, with no signs of recurrence.

3. Discussion

HCC is a complicated and heterogeneous disease. Liver resection is indicated in early-stage patients without cirrhosis or who have well-preserved liver function and an anticipated liver remnant of at least 25%. This is possible in fewer than 5% of patients. Liver transplantation is indicated in patients with a single nodule up to 5 cm in size or up to three nodules up to 3 cm in size each [1,2]. In this case, the patient was not a candidate for liver transplantation, as he had a 19 cm tumor.

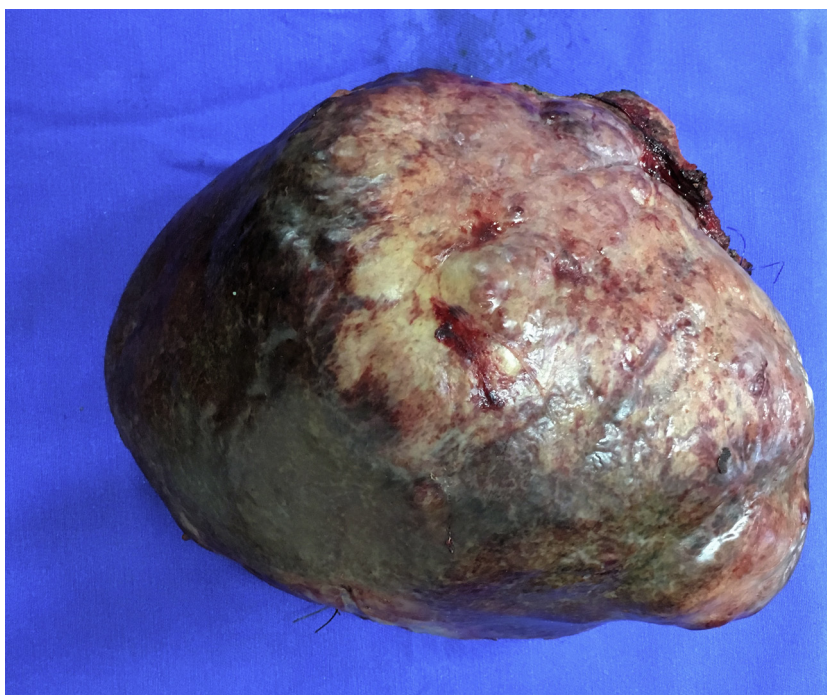


Fig. 5. Specimen of HCC.

The ALPPS procedure has been employed to improve resection, when a small liver remnant is expected. It is a controversial procedure in liver surgery and is still being debated in surgical meetings around the world. A hepato-pancreatobiliary surgeon who performs ALPPS has to know that not all patients with HCC are suitable for this procedure and has to weigh the benefit of achieving complete resection against the risk of complications of this extensive procedure [6–8]. Remarkable hypertrophy is observed in ALPPS, even in patients with low-grade fibrosis, even greater than that after portal vein embolization [7,8,10].

A high rate of mortality and complications seem to be associated more with HCC than with colorectal liver metastases [4,6]. In the present case the patient was classified as Child-Pugh class A, with no portal hypertension and excellent status performance. The procedure was very useful as the patient had portal vein thrombosis and no opportunity to perform portal vein embolization.

The strict selection of patients enables some groups to perform ALPPS with low mortality [6]. According to Schadde et al., among 15 patients with HCC who underwent ALPPS, incomplete resection was not observed, disease-free survival at one year was 87%, Clavien-Dindo complications \geq IIIb were 25% (colorectal liver metastasis 21%, $p > 0.05$), and 90-day mortality was 12% [5]. During the transection, the anterior approach can result in minor intraoperative blood loss and the need for perioperative blood transfusions. This procedure results in reduced morbidity and mortality [8–10]. In the present case, we performed an anterior approach to minimize complications.

Bjornsson et al. reported no 90-day mortality or severe complications (grade \geq 3B) in patients who underwent ALPPS for primary hepatobiliary malignancies. The postoperative hospital stay after the stage 2 operation was 13.5 days [9].

ALPPS is an aggressive surgical approach for tumors unresectable in a single stage, and an accepted alternative for a huge HCC. However, it should be reserved for patients who are not candidates for portal vein embolization due to previous invasion of the portal vein branch, or with failed portal vein embolization or ligation. The choice of treatment with ALPPS is influenced by factors such as availability of resources and expertise. The progn-

osis of a huge HCC treated with aggressive surgery is significantly better than that treated with transarterial chemoembolization or sorafenib [9,10].

4. Conclusion

ALPPS seems to be feasible and should be performed in patients with a huge HCC. This strategy represents a chance of cure for patients who are candidates for palliative treatment. A careful selection of patients with the lowest perioperative risk is necessary. However, this procedure should be performed in centers with expertise in hepato-biliary surgery.

Conflict of interest

The authors declare that they have no conflict of interest.

Ethical standards

Ethical approval was not required and patient identifying information was not presented in this report.

Funding

No funding.

Consent

Written informed consent was obtained from the patient for publication of this case report and accompanying images. A copy of the written consent is available for review by the Editor-in-Chief of this journal on request.

Author contributions

Orlando Jorge M Torres—Study concept, design, data collection, data analysis, interpretation, written. Rodrigo Rodrigues

Vasques—Data collection, data analysis, interpretation. Thiago Henrique S Silva—Data collection, data analysis. Miguel Eugenio Castelo Branco—Data collection, data analysis. Camila Cristina S Torres—Design, data collection, data analysis, interpretation, written.

Guarantor

I accept full responsibility for the work and for financial issues.

References

- [1] F.J. Carrilho, A.A. Mattos, A.F. Vianey, D.C.P. Vezozzo, F. Marinho, F.J. Souto, Brazilian society of hepatology recommendations for the diagnosis and treatment of hepatocellular carcinoma, *Arq. Gastroenterol.* 52 (2015) 2–14.
- [2] C. Lim, P. Compagnon, M. Sebah, C. Salloum, J. Calderaro, A. Luciani, Hepatectomy for hepatocellular carcinoma larger than 10 cm: preoperative risk stratification to prevent futile surgery, *HPB* 17 (2015) 611–623.
- [3] A.A. Schnitzbauer, S.A. Lang, H. Goessmann, S. Nadalin, J. Baumgart, S.A. Farkas, Right portal vein ligation combined with in situ splitting induces rapid left lateral liver lobe hypertrophy enabling 2-staged extended right hepatic resection in small-for-size settings, *Ann. Surg.* 255 (2012) 405–414.
- [4] E. Schadde, V. Ardiles, R. Robles-Campos, M. Malago, M. Machado, R. Hernandez-Alejandro, Early survival and safety of ALPPS: first report of the international ALPPS registry, *Ann. Surg.* 260 (2014) 829–838.
- [5] O.J. Torres, E.S.M. Fernandes, P. Herman, ALPPS: past, present and future, *Arq. Bras. Cir. Dig.* 28 (2015) 155–156.
- [6] P. Herman, J.A.P. Krüger, M.V. Perini, F.F. Coelho, I. Cecconello, High mortality rates after ALPPS: the devil is the indication, *J. Gastrointest. Cancer* 46 (2015) 190–194.
- [7] O.J. Torres, J.M. Moraes-Junior, N.C.L. Lima, A.M. Moraes, Associating liver partition and portal vein ligation for staged hepatectomy (ALPPS): a new approach in liver resections, *Arq. Bras. Cir. Dig.* 25 (2012) 290–292.
- [8] O.J. Torres, E.S.M. Fernandes, C.V. Oliveira, C.X. Lima, F.L. Waechter, J.M. Moraes-Junior, Associating liver partition and portal vein ligation for staged hepatectomy (ALPPS): the Brazilian experience, *Arq. Bras. Cir. Dig.* 26 (2013) 40–43.
- [9] B. Björnsson, E. Sparrelid, K. Hasselgren, Associating liver partition and portal vein ligation for primary hepatobiliary malignancies and non-colorectal liver metastases, *Scand. J. Surg.* (2016).
- [10] G. Vennarecci, A. Laurenzi, S. Santoro, M. Colasanti, P. Lepiane, G.M. Ettore, The ALPPS procedure: a surgical option for hepatocellular carcinoma with major vascular invasion, *World J. Surg.* 38 (2014) 1498–1503.

Open Access

This article is published Open Access at scimedirect.com. It is distributed under the [IJSCR Supplemental terms and conditions](#), which permits unrestricted non commercial use, distribution, and reproduction in any medium, provided the original authors and source are credited.