XII SBAD
12ª Semana Brasileira do Aparelho Digestivo

24 a 27 DE NOVEMBRO 2013 GOIÂNIA

Tumores benignos do fígado

Orlando Jorge M. Torres
Professor Titular e Chefe do Serviço de Cirurgia do Aparelho Digestivo
Universidade Federal do Maranhão - UFMA

Lesões benignas do fígado

Tumores Epiteliais

Hepatocelular
- Hiperplasia nodular focal
- Hiperplasia nodular regenerativa
- Adenoma hepatocelular

Colangiocelular
- Adenoma do ducto biliar
- Cistoadenoma biliar

Tumores Mesenquimais

Tecido adiposo
- Lipoma
- Mielolipoma
- Angiomiolipoma

Tecido muscular
- Leiomioma

Vasos sanguineos
- Hemangioma
- Hemangioendotelioma

Tumores Epitelial-Mesenquimal (mistos)

Hamartoma mesenquimal
Teratoma benigno

Outros

Pseudotumor inflamatório
Alteração gordurosa focal
Lesões infecciosas
Abscesso hepático

Lesões císticas

Cisto hepático simples
Cisto hidático
Cisto de colédoco
Cistoadenoma biliar
Doença de Caroli
Doença hepática policística
Pielose hepática

Gibbs JF, et al. Surg Clin N Am 84:463-480, 2004

Adenoma hepatocelular

- Doença benigna
- Incomum
- Mulher em idade reprodutiva
- Uso contraceptivo oral

Também:

- Homens em uso de esteroides
- Armazenamento de Glicogênio
- Distúrbios de sobrecarga de ferro

- Incidência aumentada - 4/100.000
- Ruptura espontânea (hemorragia)

uso de hormônio recente

aumento de tamanho

Karkar AM, et al. HPB 2013;15:235-43

Adenomatose

- Pelo menos 10 lesões
- Mais comum em homens
- Maior risco

  Transformação maligna

  Hemorragia

Deneve JL, et al. Ann Surg Oncol 2009;16:640

Adenoma hepatocelular

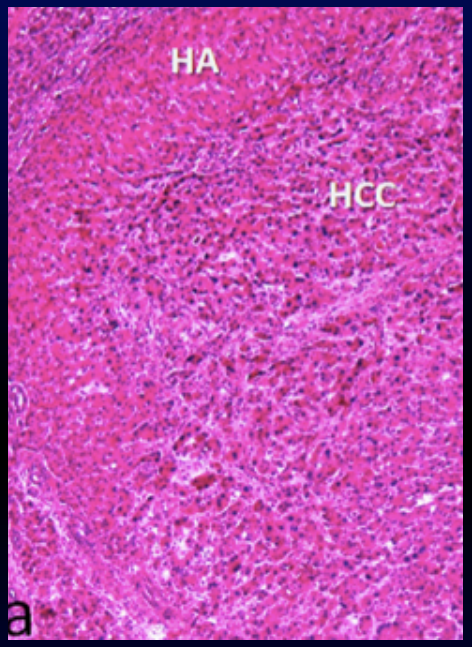

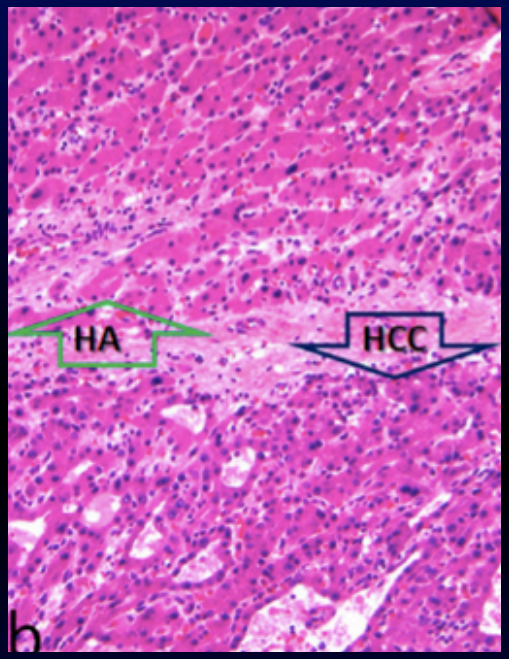

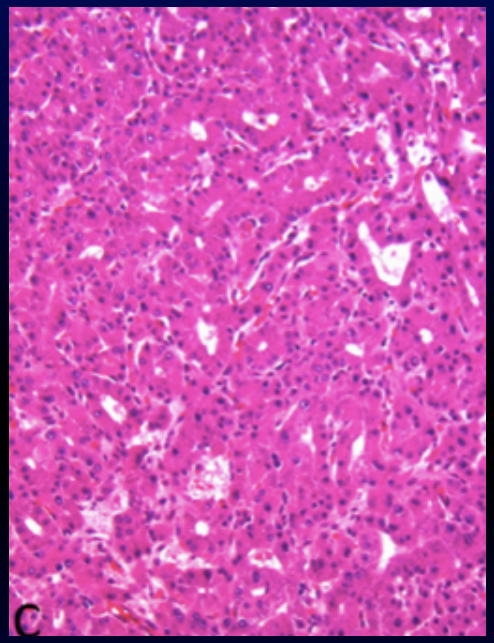

Adenoma/Carcinoma

HCC com atipia

HCC bem diferenciado

Karkar AM, et al. HPB 2013;15:235-43

Table 3 Types of HCAs and their immunohistochemical markers

HCA type	Frequency (%)	Malignant transformation	Markers
β-catenin activated	10–15	Yes	β-catenin+/GS+
HNF1α inactivated	30–50	Rarely	LFABP–
Inflammatory	35	No	SAA+/CRP+
Unclassified	5–10	No	None

CRP, C-reactive protein; GS, glutamine synthetase; HCA, hepatocellular adenoma; HNF1α, hepatocyte nuclear factor 1α; LFABP, liver-fatty acid binding protein; SAA, serum amyloid A; +, positive; –, negative.

Adenoma hepatocelular

Classificação de Bordeaux :

- 1. Com mutação do gene HNF1α

  30-50% dos adenomas < 5% dos HCC

- 2. Com mutação do gene β-catenina

  10-15% dos adenomas - lesões borderline para HCC

- 3. Sem mutação dos genes (β–catenina e HNF1α) e com características inflamatórias

  35% dos adenomas - sem transformação maligna

- 4. Sem mutação dos genes (β–catenina e HNF1α) e sem características específicas

  5-10% dos casos - sem transformação maligna

Bioulac-Sage P, et al. World J Gastroenterol 2007;13:2649-54

Classificação de Bordeaux :

Tipo I

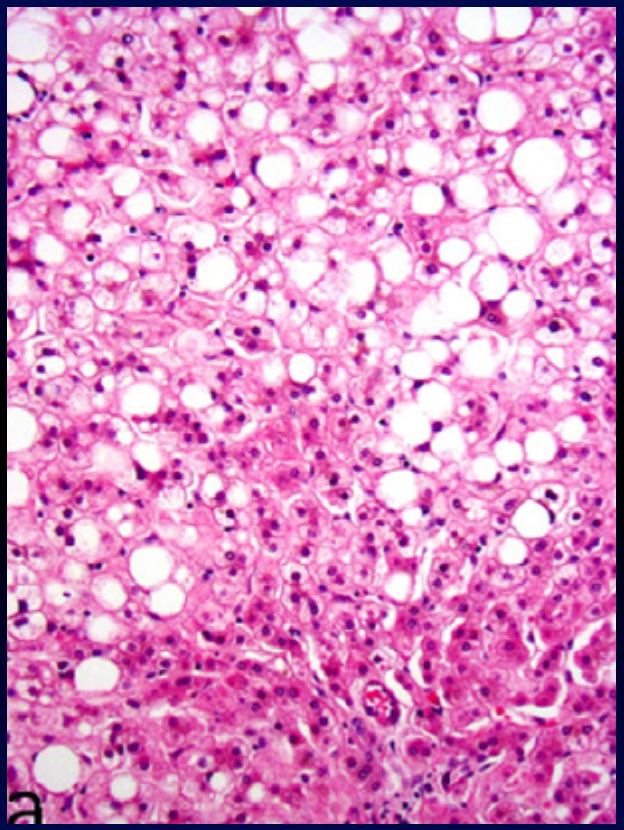

Mutação do gene HNF1α

Alterações gordurosas

Tipo II

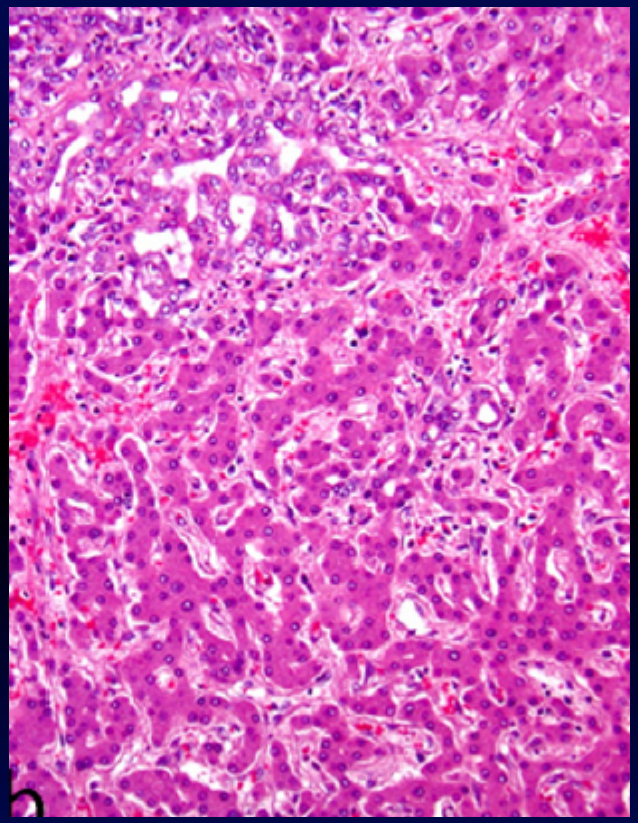

Mutação β-catenina

Atipia nuclear hepatocelular

Tipo III

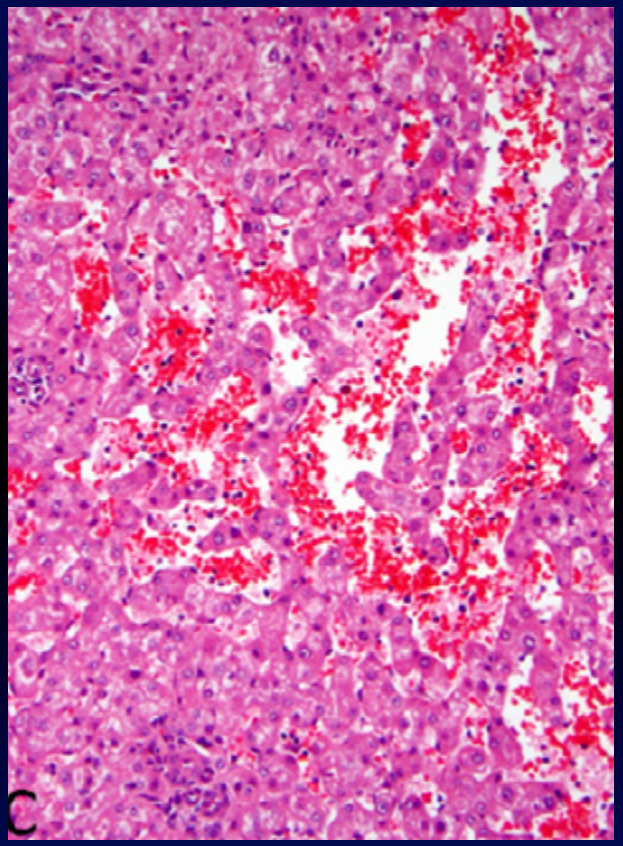

Ativação da via da IL-6

Dilatação sinusoidal e infiltração inflamatória

Karkar AM, et al. HPB 2013;15:235-43

Adenoma hepatocelular

- Ruptura e hemorragia (20-40%)

  Intratumoral

  Intraperitoneal

- Transformação maligna

  4,2 %

  > 5 cm

  Não é evitada pela suspensão do ACO

Stoot J, et al. HPB 2010;12:509-22
Marks WH, et al. Ann Surg 1988;208:190-5

Sangramento

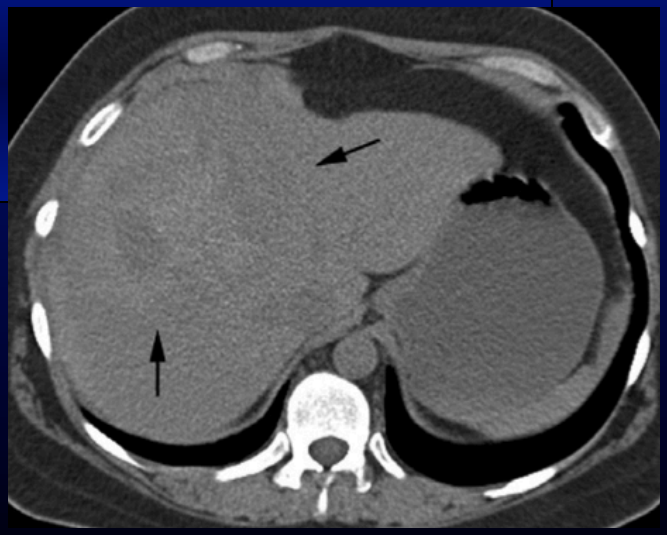

- Sintoma
- > 5 cm
- Gravidez e puerpério

Barthelmes L, et al. HPB 2005;7:186-96

Transformação maligna

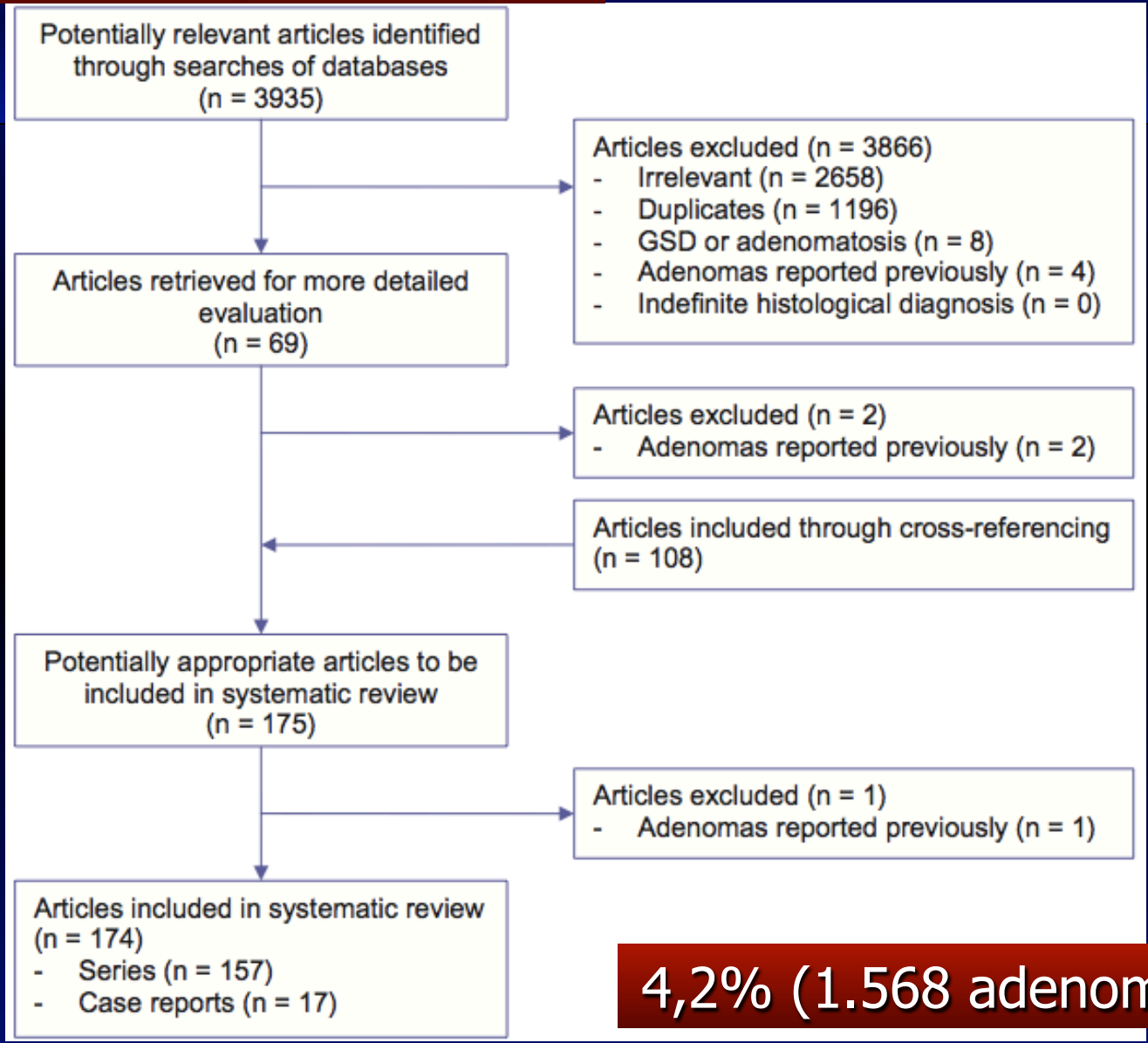

4,2% (1.568 adenomas)

Stoot J, et al. HPB 2010;12:509-22

Tamanho da lesão

- Médio 8,0 cm
- 3 casos < 5 cm
- Menor na literatura - 4,0 cm

Stoot J, et al. HPB 2010;12:509-22
Micchelli ST, et al. Mod Pathol 2008;21:491-7

Risco elevado

- Ingesta de esteróides anabolizantes
- Sexo masculino
- Doença de depósito de glicogênio
- Presença de displasia

Stoot J, et al. HPB 2010;12:509-22

Table 3a Resection indications and outcomes

	Solitary (61.1%)	Multifocal (38.9%)
	Single HA	Multiple HAs (2–9)
Resections	22	12
Indication for intervention		
Suspicion of malignancy	8	4
Large size	9	5
Clinical haemorrhage	3	0
Growth	1	2
PET +	1	0
Continuous HRT	0	1

Karkar AM, et al. HPB 2013;15:235-43

Outras formas de tratamento

Embolização

Table 2 Adenomas were divided into three treatment groups with follow-up time and size recorded. Median sizes between each resection group were significantly different ($P < 0.01$)

Intervention	No. of patients	Median follow-up time	No. of adenomas	Median size (cm)
Resection	35	1.8 years (22 days–18 years)	48	3.6 (0.7–23)
Embolization	13	4.7 years (5.1 months–13.8 years)	37	2.6 (0.5–9.9)
Observation	9	1.6 years (1 day–7.8 years)	15	1.2 (0.6–6.3)

Recorrência em 5 casos (9,2%)

Karkar AM, et al. HPB 2013;15:235-43

Recorrência

Table 4 The treatment and time interval between treatments for each of five treatment failures

Group	Size of initial lesion (cm)	1st treatment	Type of recurrence	2nd treatment	Time interval between procedures (months)	Status
Multiple	3.2	Embolization	Persistent disease	Embolization	3.7	AWD
Multiple	5.5	Embolization	Persistent disease	Embolization	4.5	AWD
Single	4.2	Embolization	Persistent disease	Resection	4.4	No recurrence
Single	11.5	Resection	Local recurrence	Embolization	66	AWD
Single	10	Resection	Local recurrence	Resection	10	No recurrence

AWD, alive with disease.

Karkar AM, et al. HPB 2013;15:235-43

Tratamento

- Observar
- Ablação por radiofrequência
- Microwave
- Embolização arterial seletiva (hemorragia)
- Cirurgia

Atwell TD, et al. Am J Roentgenol 2005;184:828-31
Erdogan D, et al. Liver Int 2006;26: 433-8
Karkar AM, et al. HPB 2013;15:235-43

ORIGINAL ARTICLE

Hepatocellular adenoma: an excellent indication for laparoscopic liver resection

Paulo Herman, Fabricio Ferreira Coelho, Marcos Vinicius Perini, Renato Micelli Lupinacci, Luiz Augusto Carneiro D'Albuquerque & Ivan Cecconello

Liver Surgery Unit, Department of Gastroenterology, University of São Paulo Medical School, São Paulo, SP, Brazil

- Tempo de internação de 3,8 dias (1-15)
- Morbidade de 6,5%
- Mortalidade nula

Herman P, et al. HPB 2012;14:390-5

Laparoscopia

- Feminino
- Jovens
- Localização da lesão

  II,III,IVb,V,VI

Toro A, et al. Langenbecks Arch Surg 2013;398:195-210
Herman P, et al. HPB 2012;14:390-5

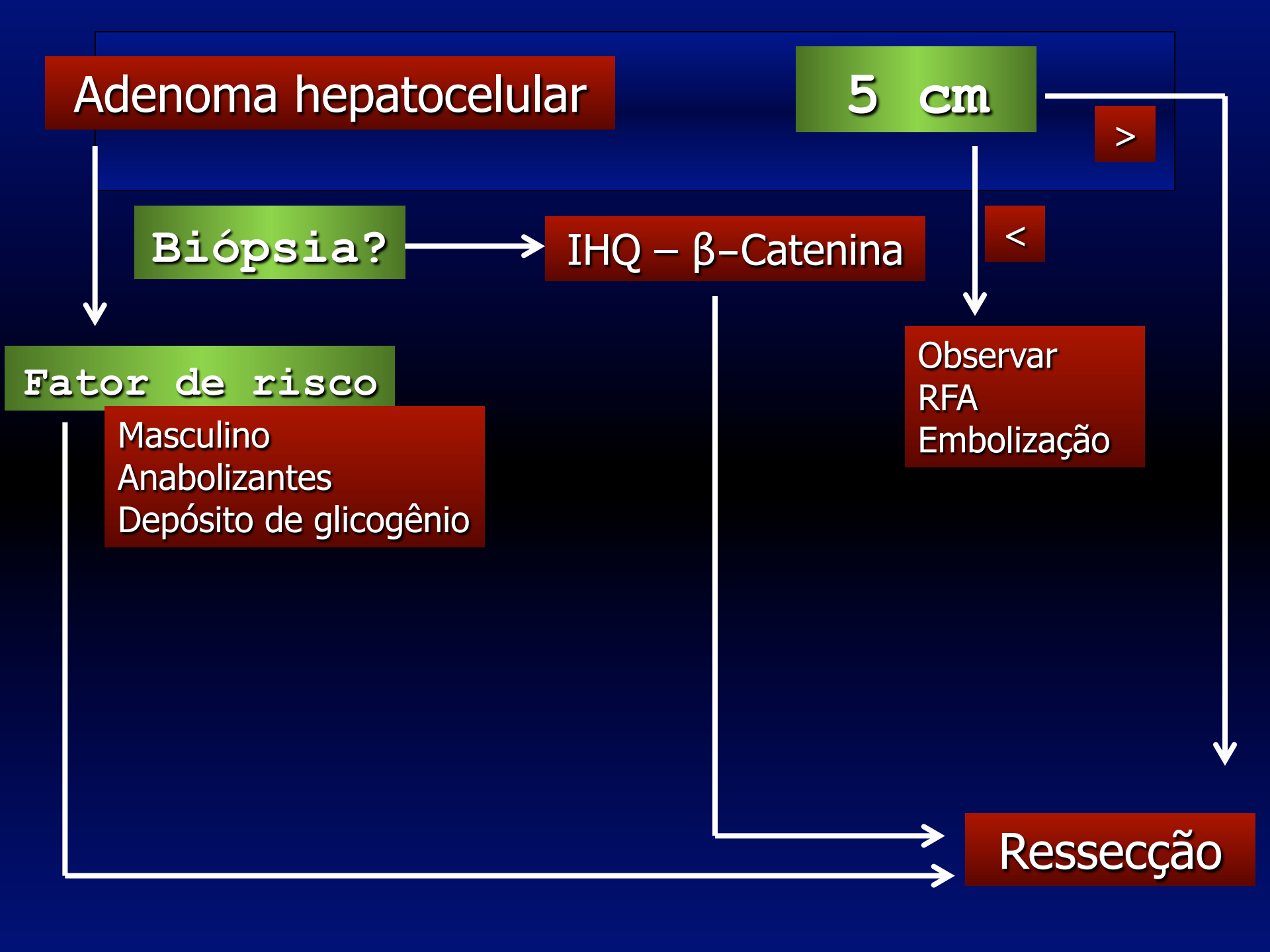
Adenoma hepatocelular
5 cm
>
<
Biópsia?
IHQ – β-Catenina
Fator de risco
Masculino
Anabolizantes
Depósito de glicogênio
Observar
RFA
Embolização
Ressecção

Hiperplasia nodular focal

- 2ª lesão benigna mais comum
- 8x mais frequente em mulheres
- Fraca relação com:

  Idade reprodutiva

  Contraceptivo oral
- Sem relação com malignidade confirmada

Navarro AP, et al. HPB 2013

Hiperplasia nodular focal

- Certeza diagnóstica
- Definição de sintomatologia

Navarro AP, et al. HPB 2013

Hiperplasia nodular focal

- Sintomáticos

  Dor abdominal

  Efeito de massa

  Ação sobre outros órgãos

  Do próprio tumor

- Diagnóstico incerto

  Progressão da doença

  Imagem radiológica atípica

- Suspeita de malignidade

Navarro AP, et al. HPB 2013

Hiperplasia nodular focal

Table III. Use and sensitivities of US, CT and MRI scanning for FNH.

Imaging modality	Number performed	Sensitivity in diagnosing FNH [number (%)]
Ultrasound	27/52	8 (30%)
CT scanning	34/52	24 (70%)
MRI scanning	46/52	40 (87%)

Bonney GK, et al. HPB 2007; 9 : 368-72

Hiperplasia nodular focal

Fase arterial | Fase portal | Fase de Equilíbrio

Hiperplasia nodular focal

- RNM típico

  Hiperintensa na fase arterial

  Isointensa no pré-contraste

  Isointensa na fase portal

  Hiper a Isointensa em T2 no pré-contraste

  Iso a hipointensa em T1

  Escara central (50%):

  levemente hiperintensa em T2

  Hipointensa em T1 (arterial e portal)

Navarro AP, et al. HPB 2013

Fase arterial T1

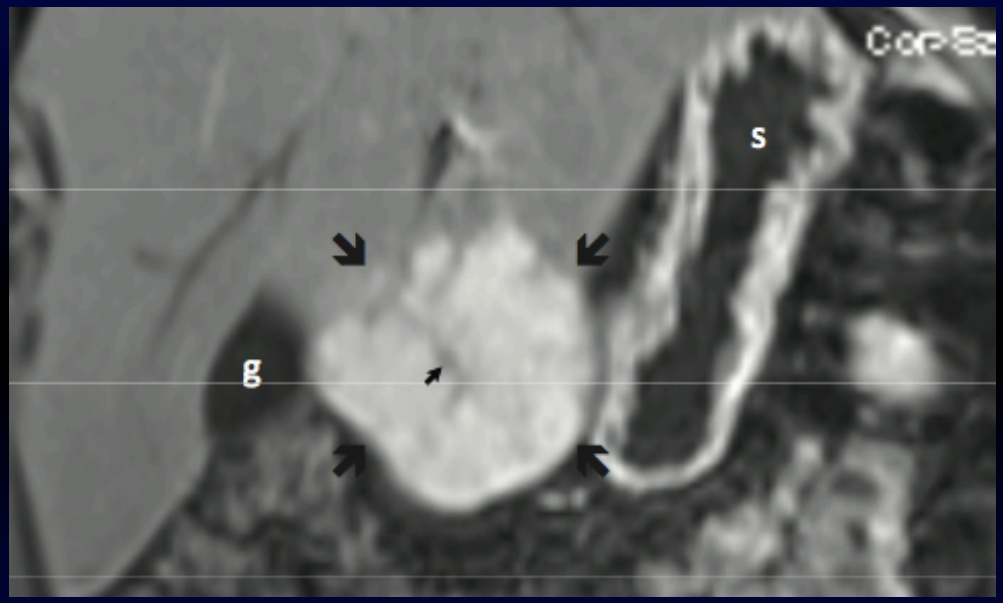

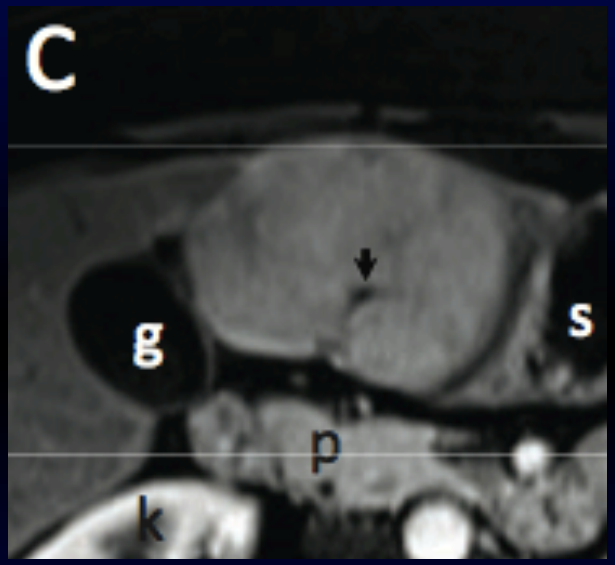

HNF: Hiperintensa na fase arterial

Escara central: Hipointensa em T1

Fase arterial T2

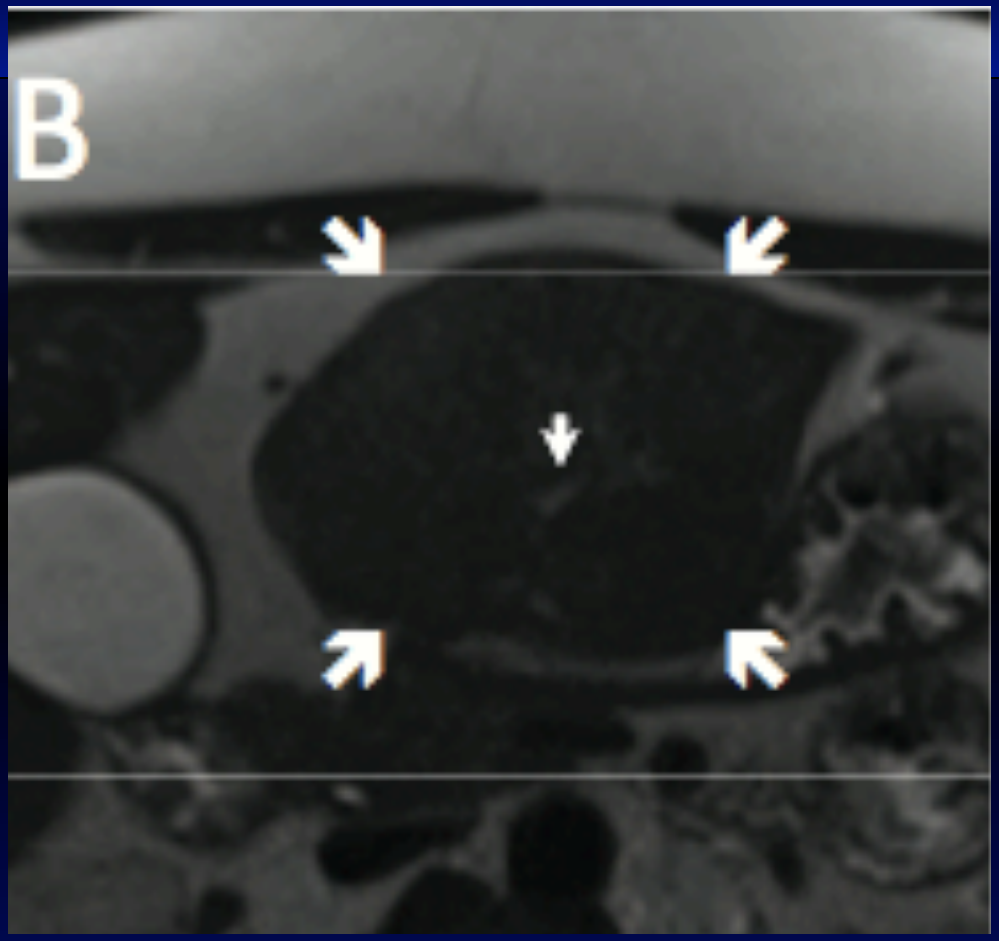

HNF: Ligeiramente hiperintensa em T2
Escara central: Hiperintensa T2

Fase portal e tardia (5 min)

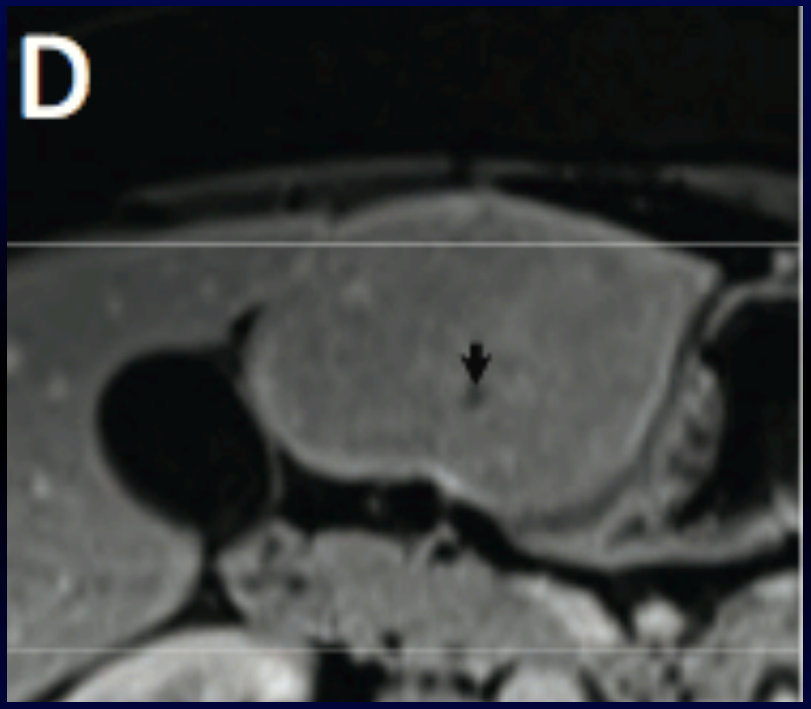

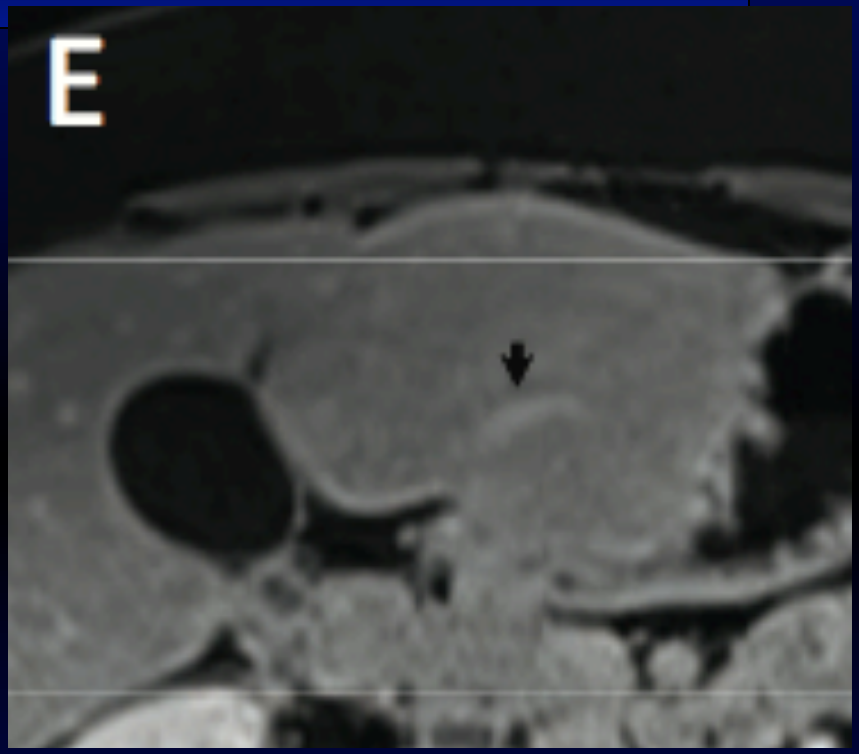

HNF: Isointenso nas fases tardias

Escara central: Hipointensa na fase portal e hiperintensa após 5 min

Hiperplasia nodular focal

- 9 estudos
  - 97 pacientes (58%)
    - Ressecados sem diagnóstico de HNF
      - Incerteza diagnóstica 76 (43%)
      - Dor abdominal

Navarro AP, et al. HPB 2013

Caso clínico

N, feminino, 23 anos
Dor abdominal leve, plenitude.
Não usa ACO
CT de abdome:

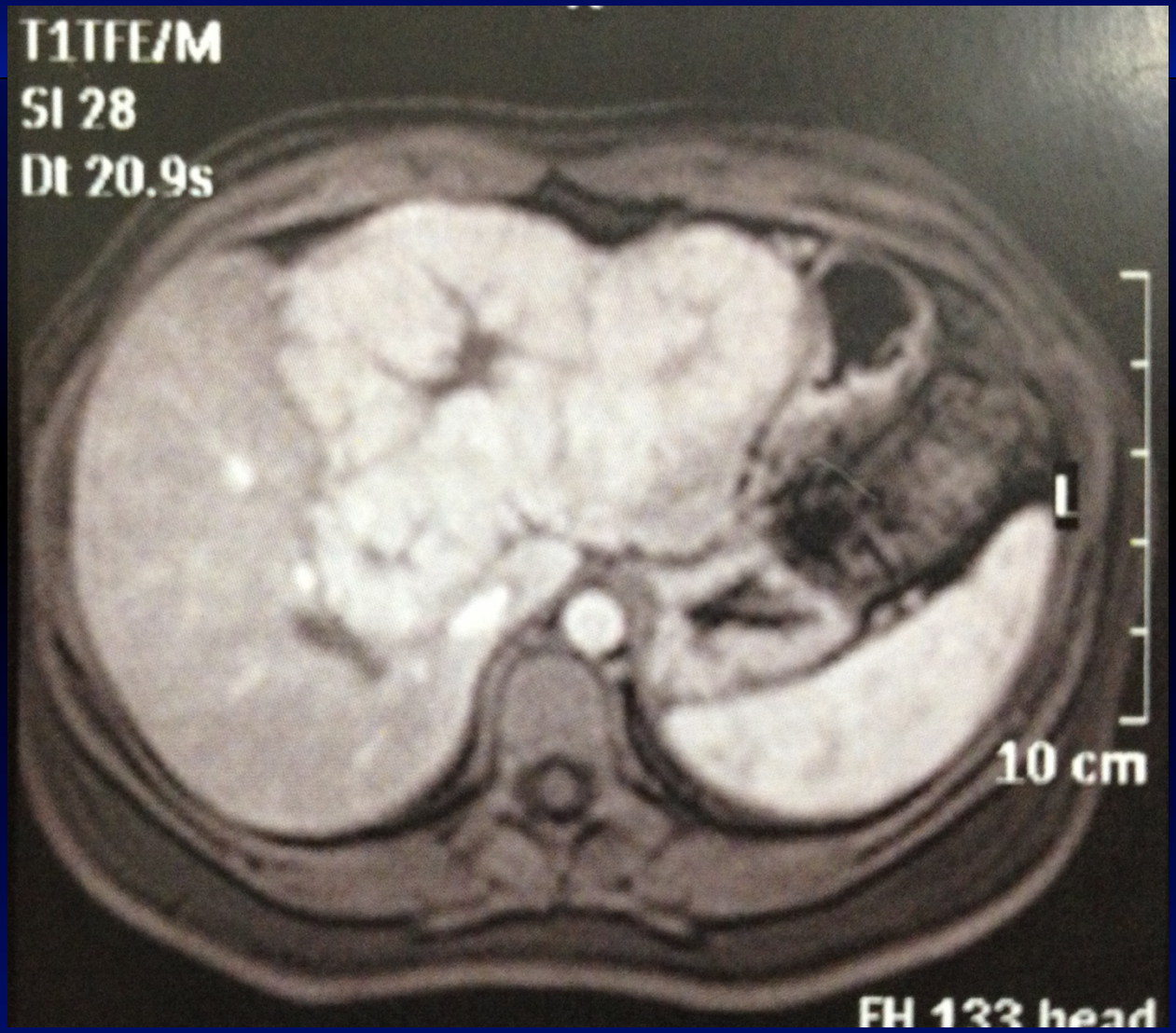
T1TFE/M
SI 28
Dt 20.9s
L
10 cm
FH 133 head

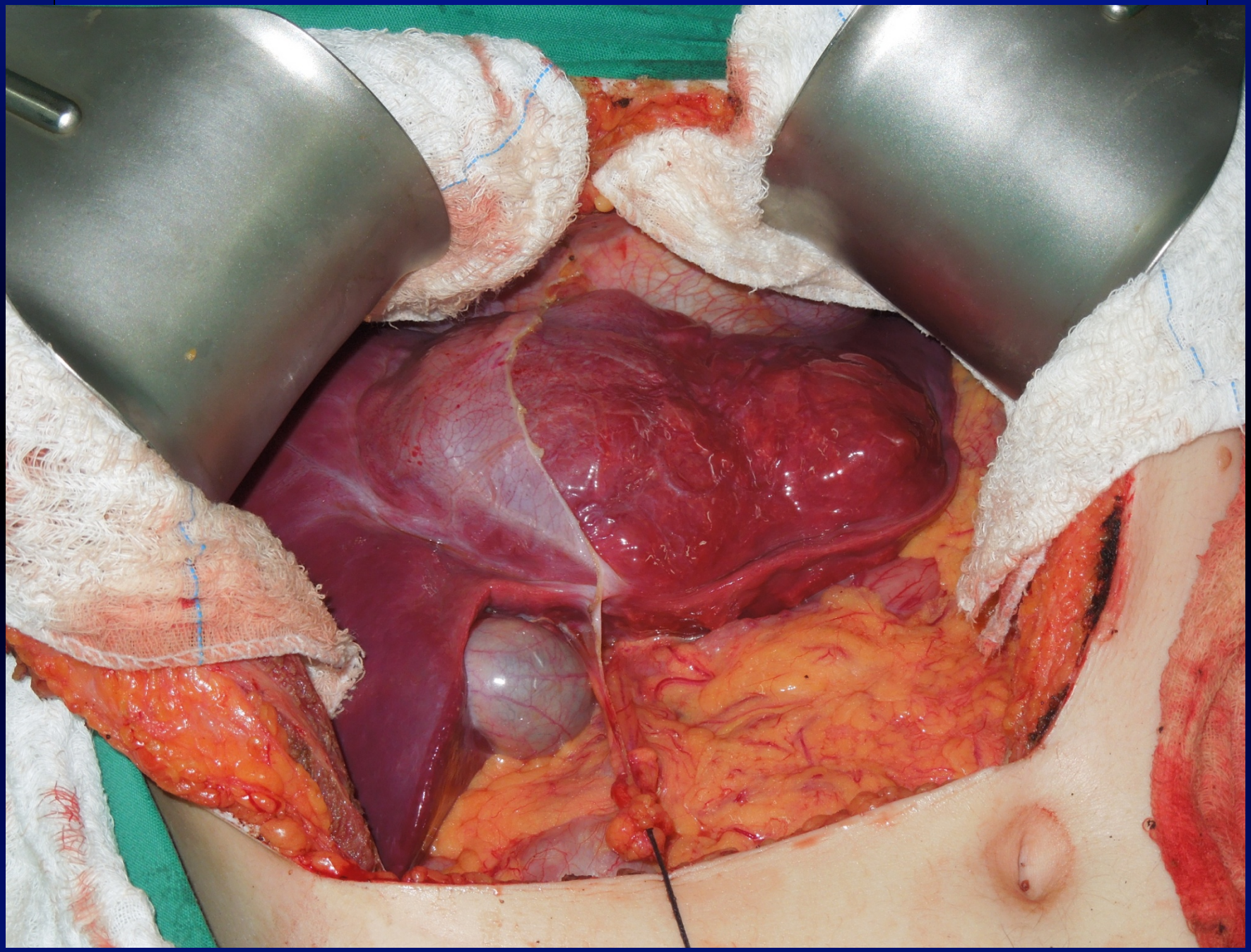

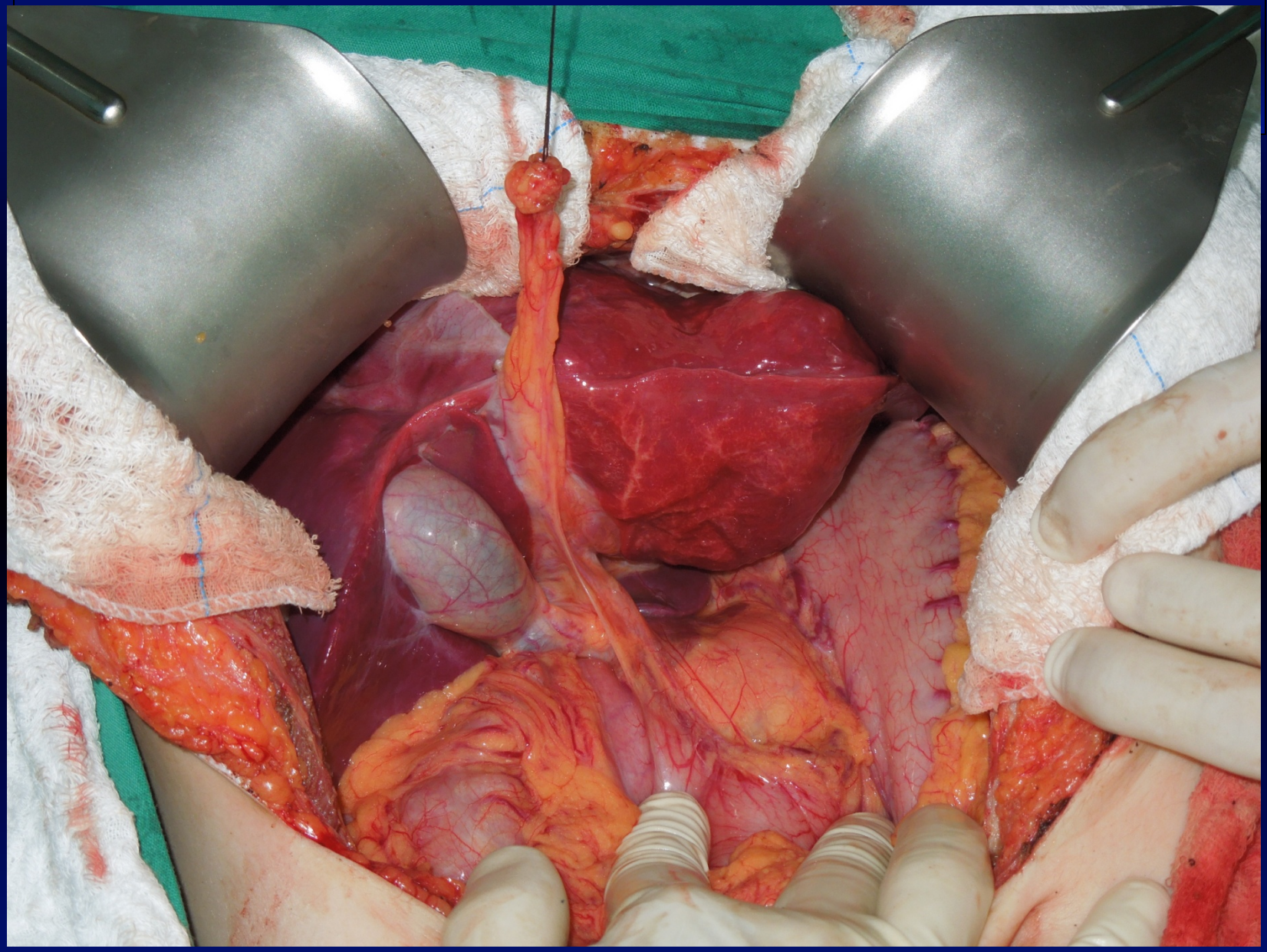

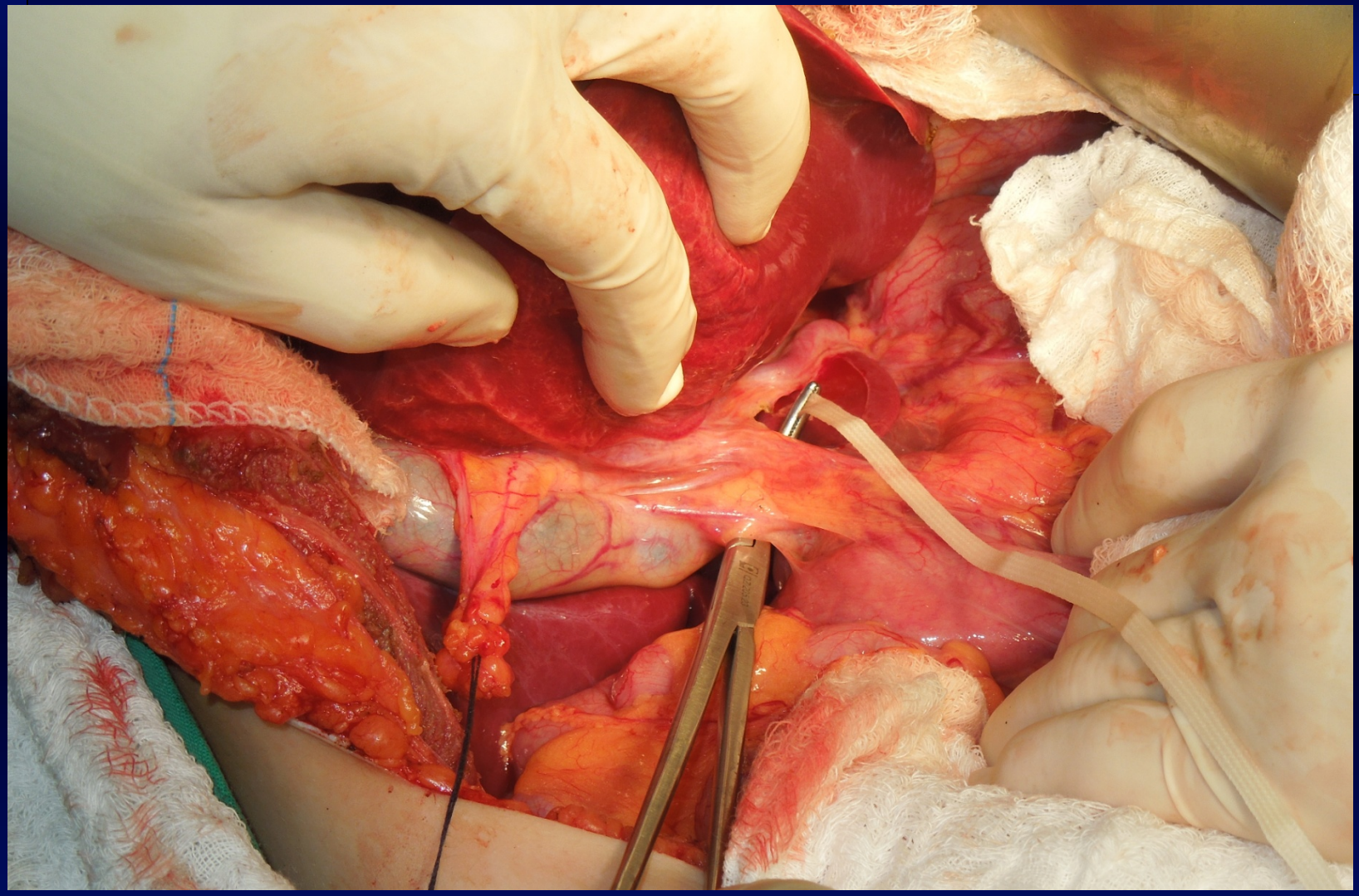

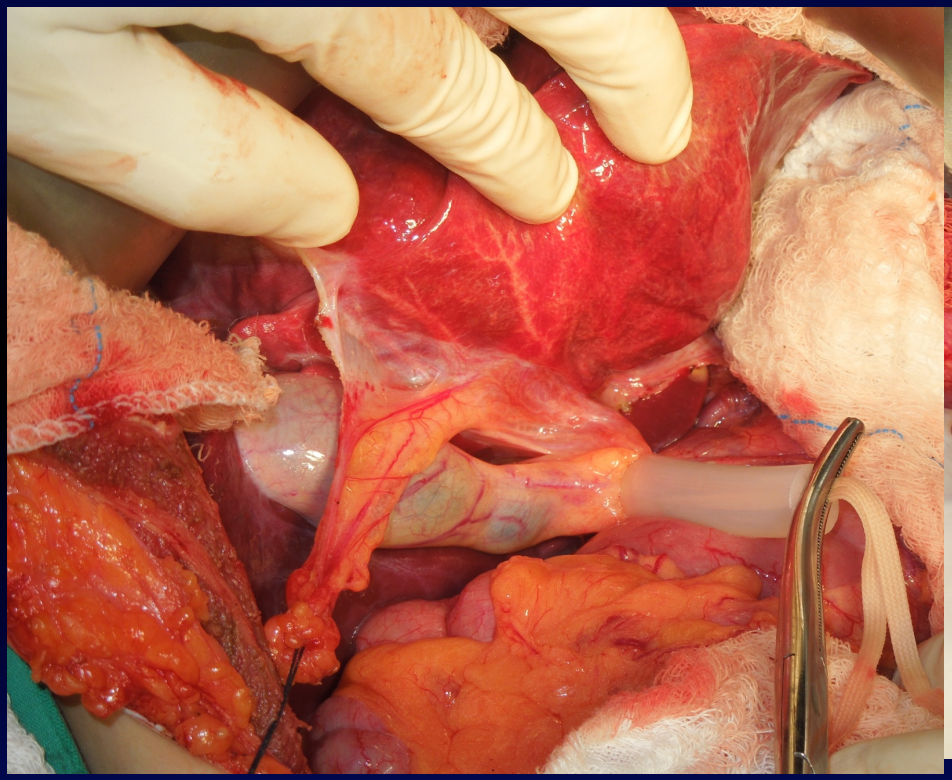

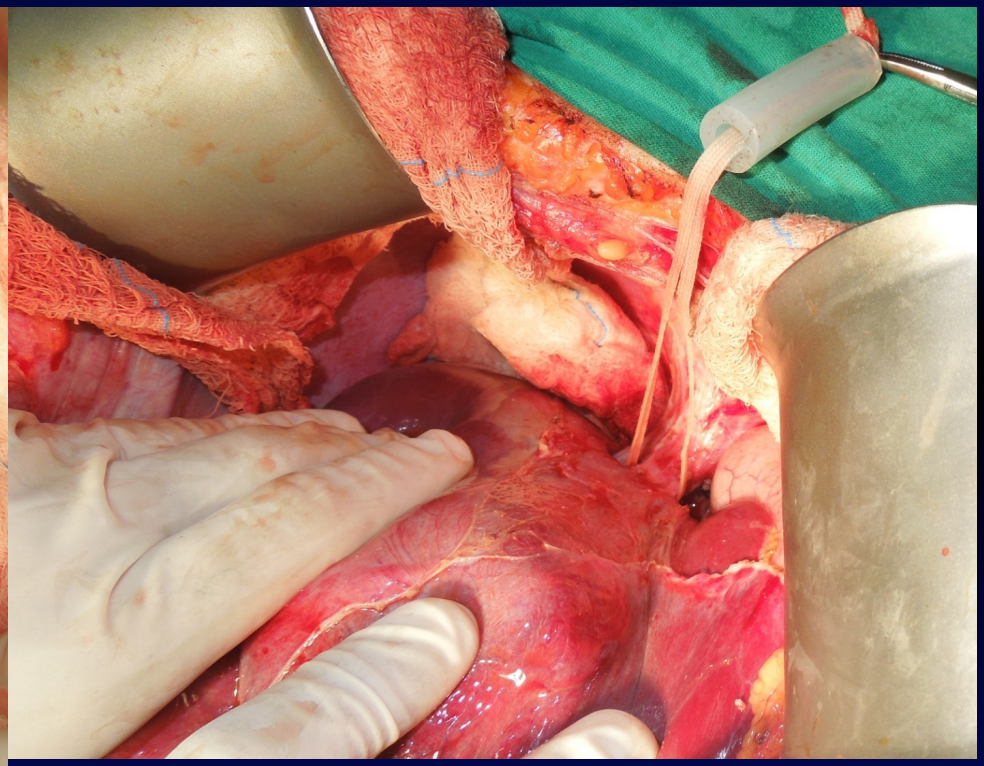

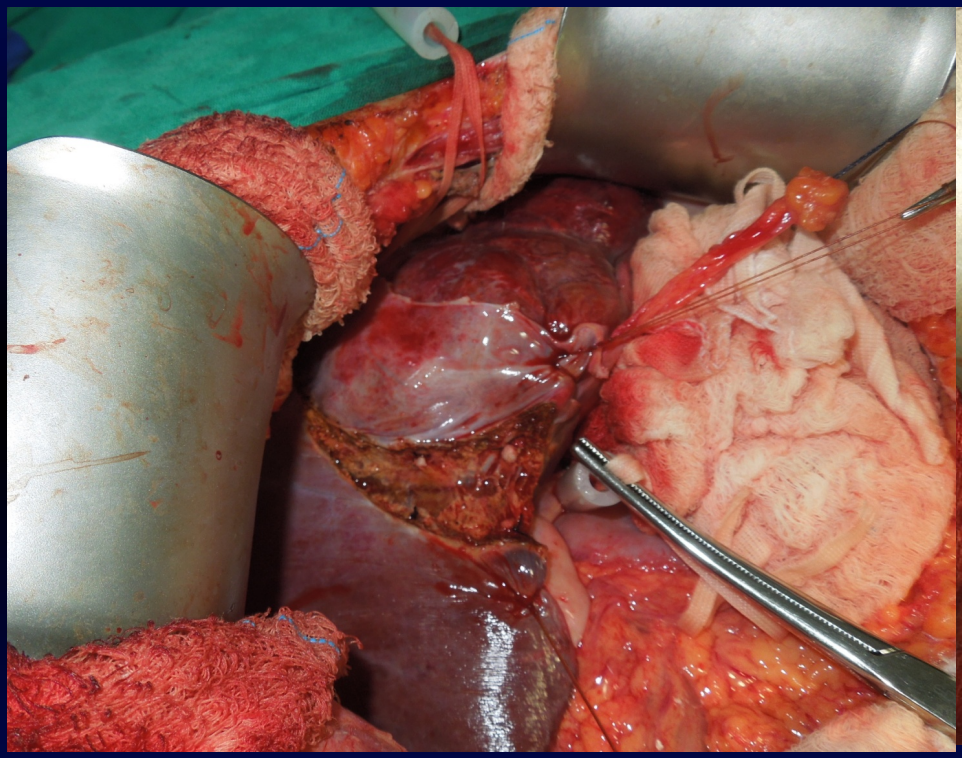

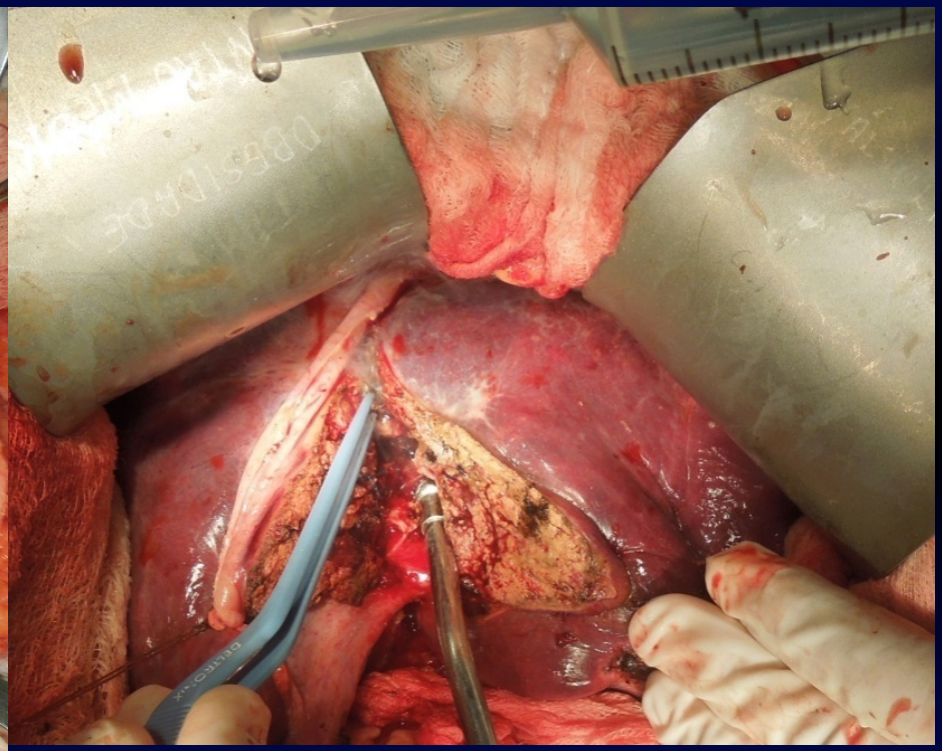

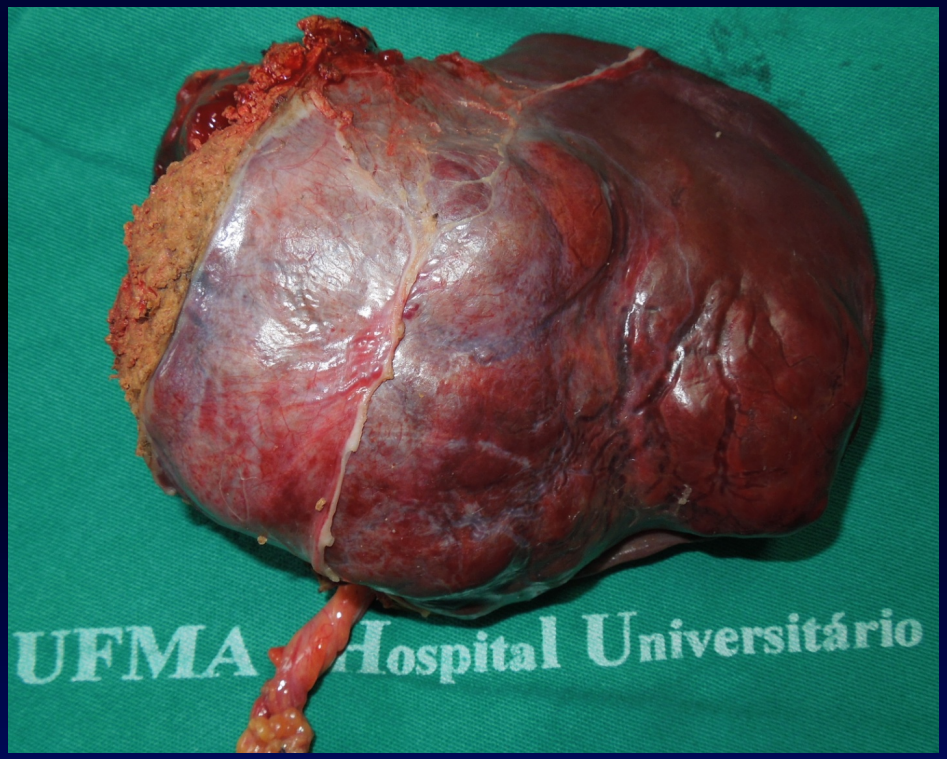
UFMA - Hospital Universitário

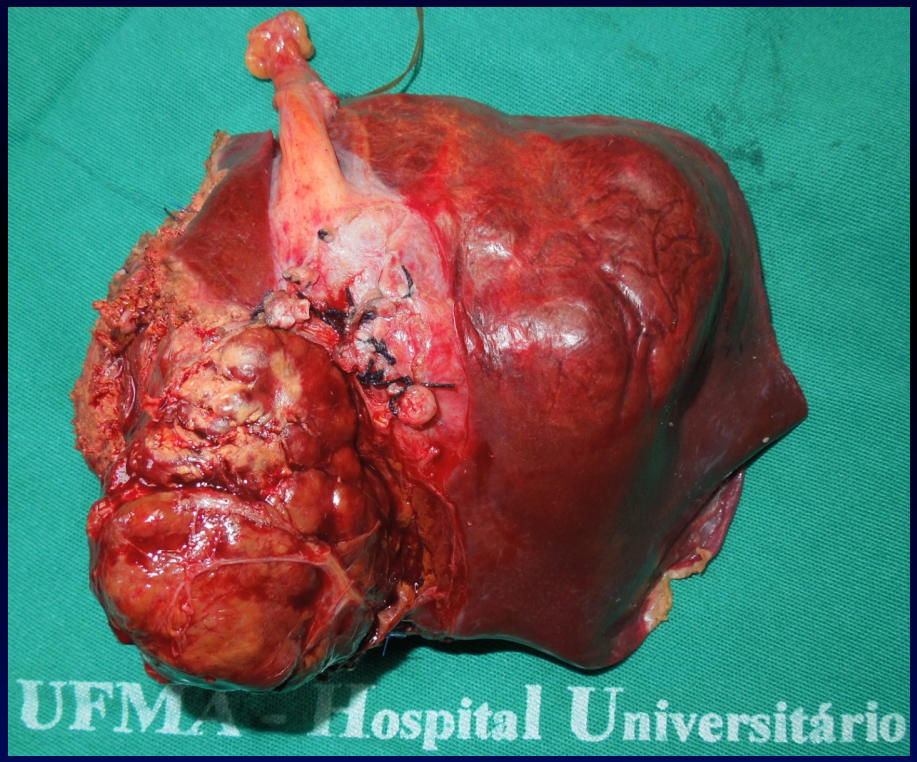
UFMA - Hospital Universitário

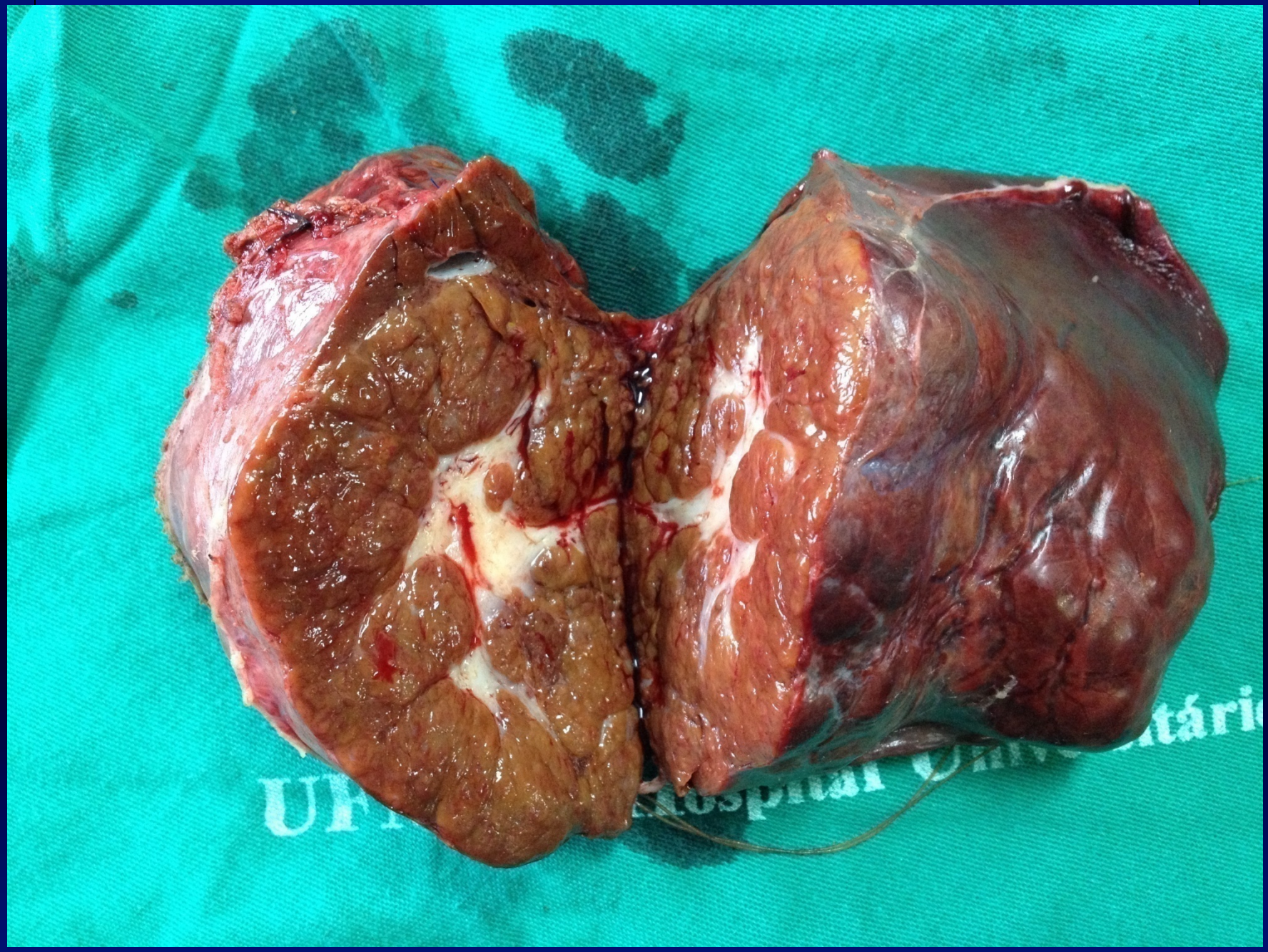

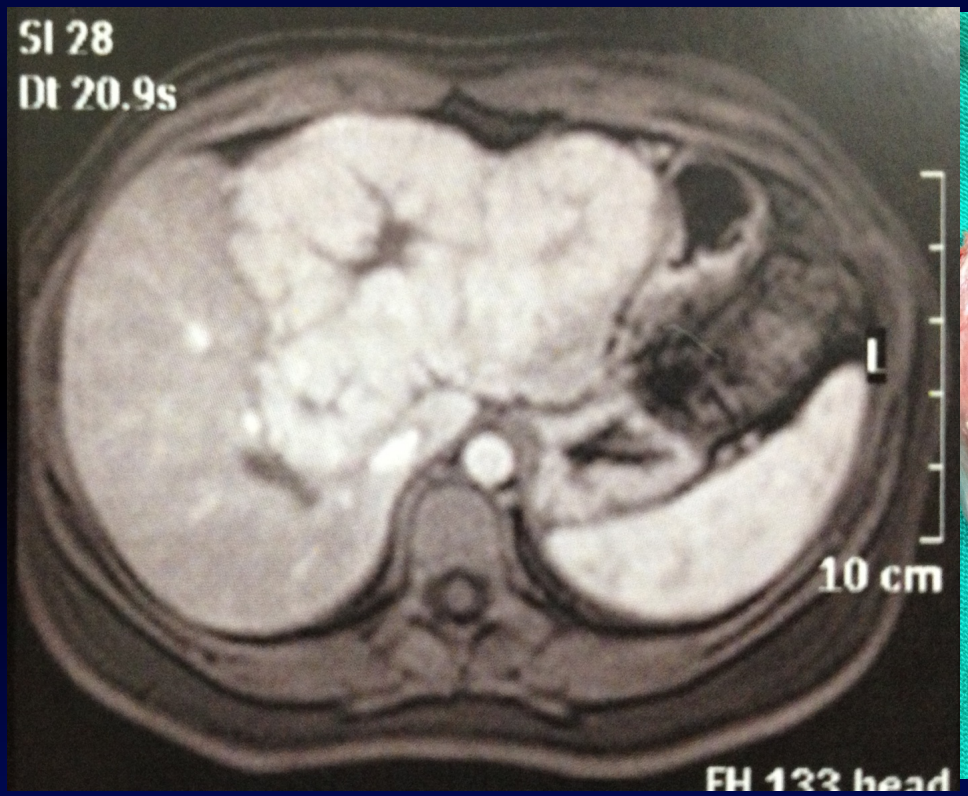
SI 28
Dt 20.9s
L
10 cm

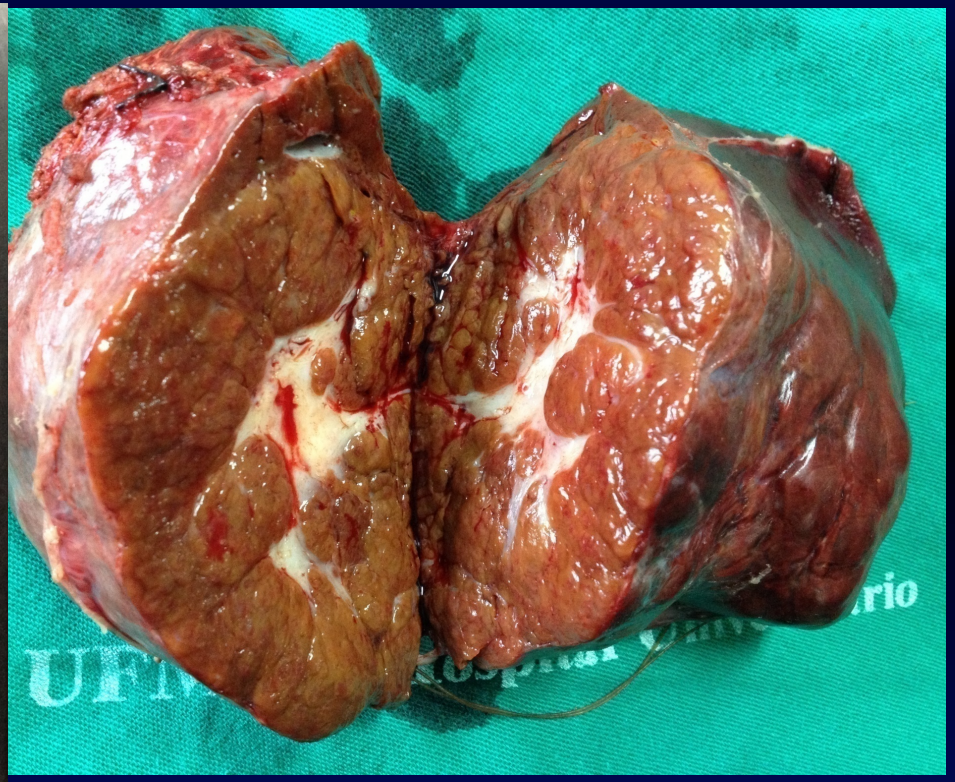

Hiperplasia nodular focal

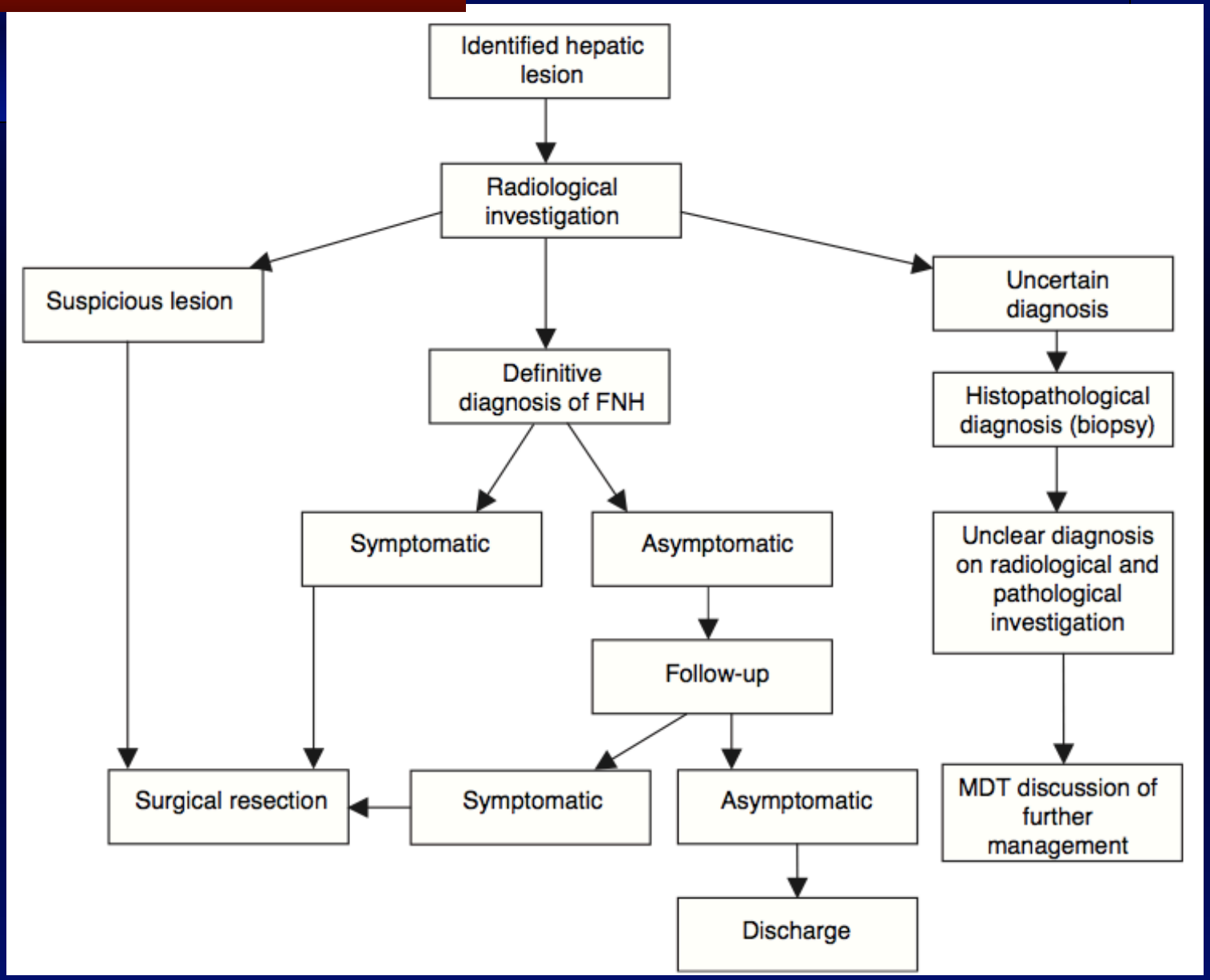

Bonney GK, et al. HPB 2007; 9 : 368-72

Biópsia?

- Falta de acurácia

  Sensibilidade baixa

  Especificidade baixa

- Dificuldade de diferenciar:

  HNF

  HCC Fibrolamelar bem diferenciado

- Risco de implante no trajeto da agulha

Hanaoka J, et al. Hepatol Res 2012; 42: 727-31

Hemangioma

- Tumor benigno mais comum (2-7% da população geral)
- Mais frequente em mulheres
- Gigante (>4-10 cm)
- Em crianças:

  Síndrome de Kasabac-Merrit

  Insuficiência cardíaca

Hemangioma

Fase arterial	Fase portal	Fase de Equilíbrio

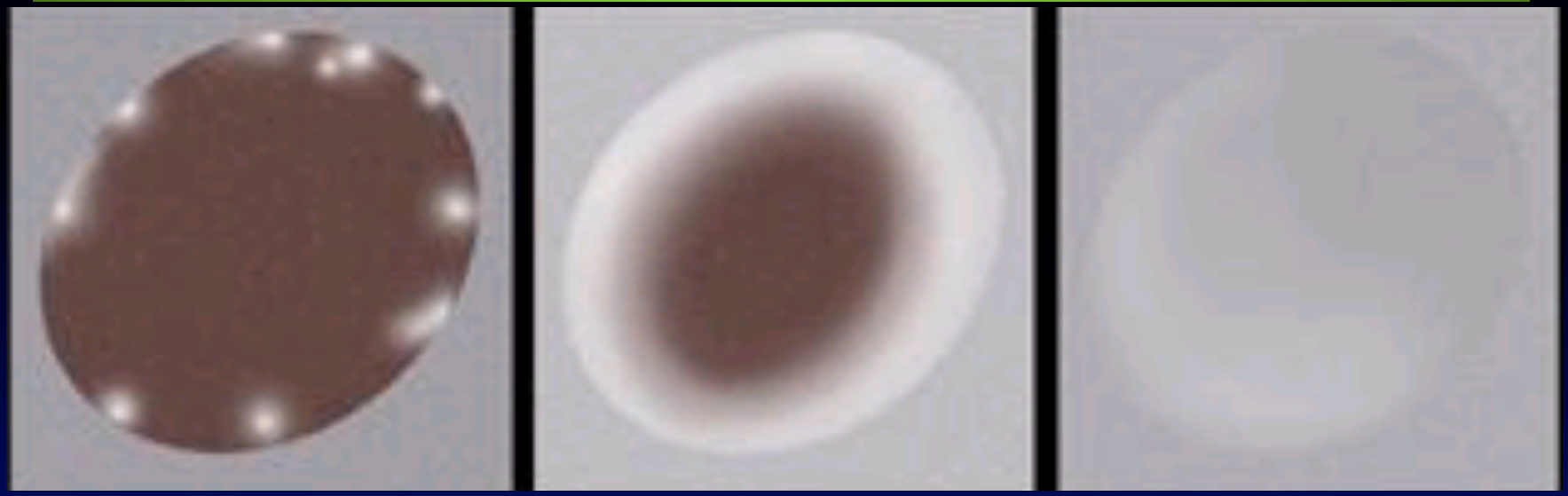

Hemangioma

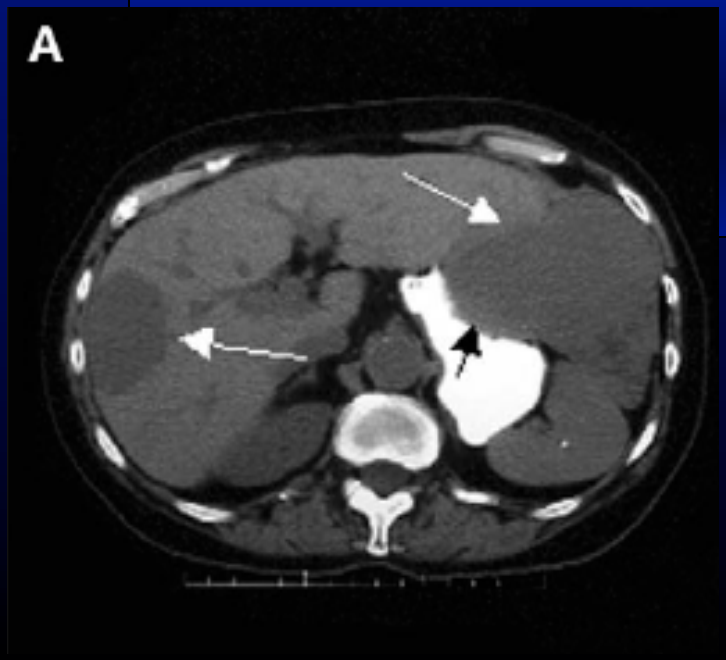

CT sem contraste

Fase arterial

Fase portal

Gibbs JF, et al. Surg Clin N Am 84:463-480, 2004

Hemangioma

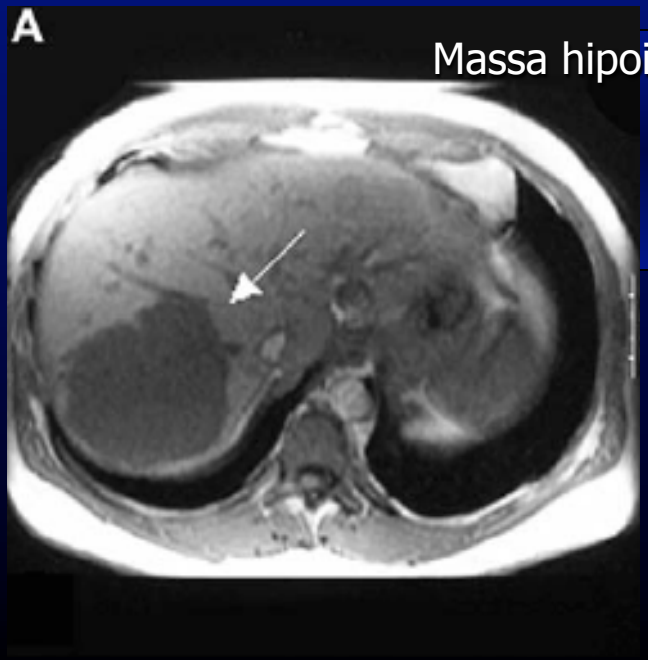

Massa hipointensa em T1

Massa hiperintensa em T2

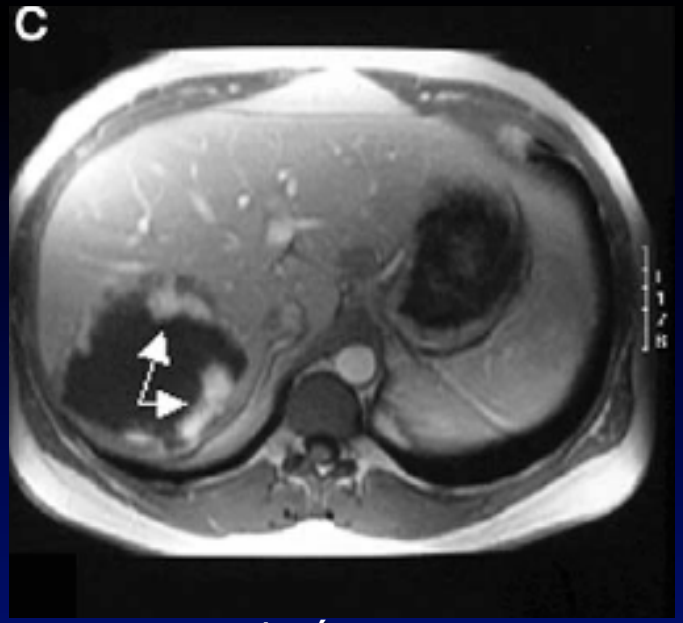

Fase arterial pós contraste em T1 com intensificação nodular periférica

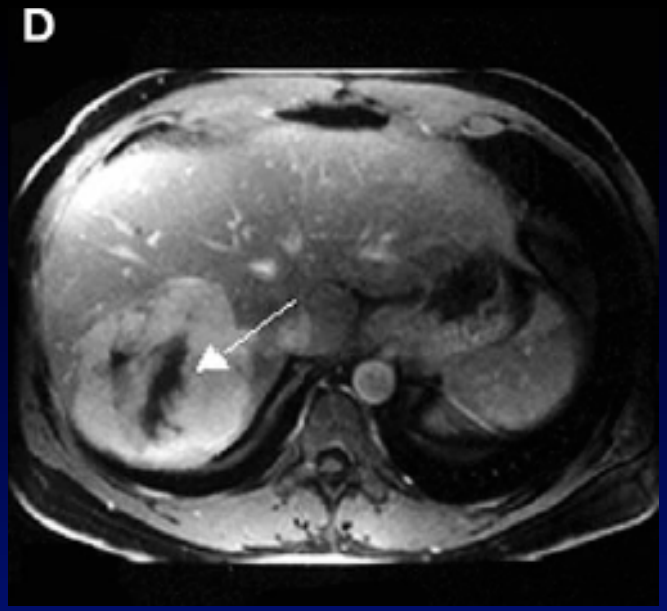

Fase venosa portal com preenchimento centrípeto

Hemangioma hepático

- Coagulopatia de consumo

  Síndrome de Kasabach-Merritt
- ICC por hiperfluxo
- Sintomas severos
- Incerteza diagnóstica

Stoot J, et al. HPB 2010;12:509-22

Outras apresentações

- Icterícia obstrutiva
- Cólica biliar
- Torção de lesão pediculada
- Obstrução gástrica

- Caso clínico

Feminino, 43 anos
Colelitíase, encaminhada para colecistectomia VL.
Intra-operatório: lesão no fígado sobre o leito da vesícula

- CT de abdome:
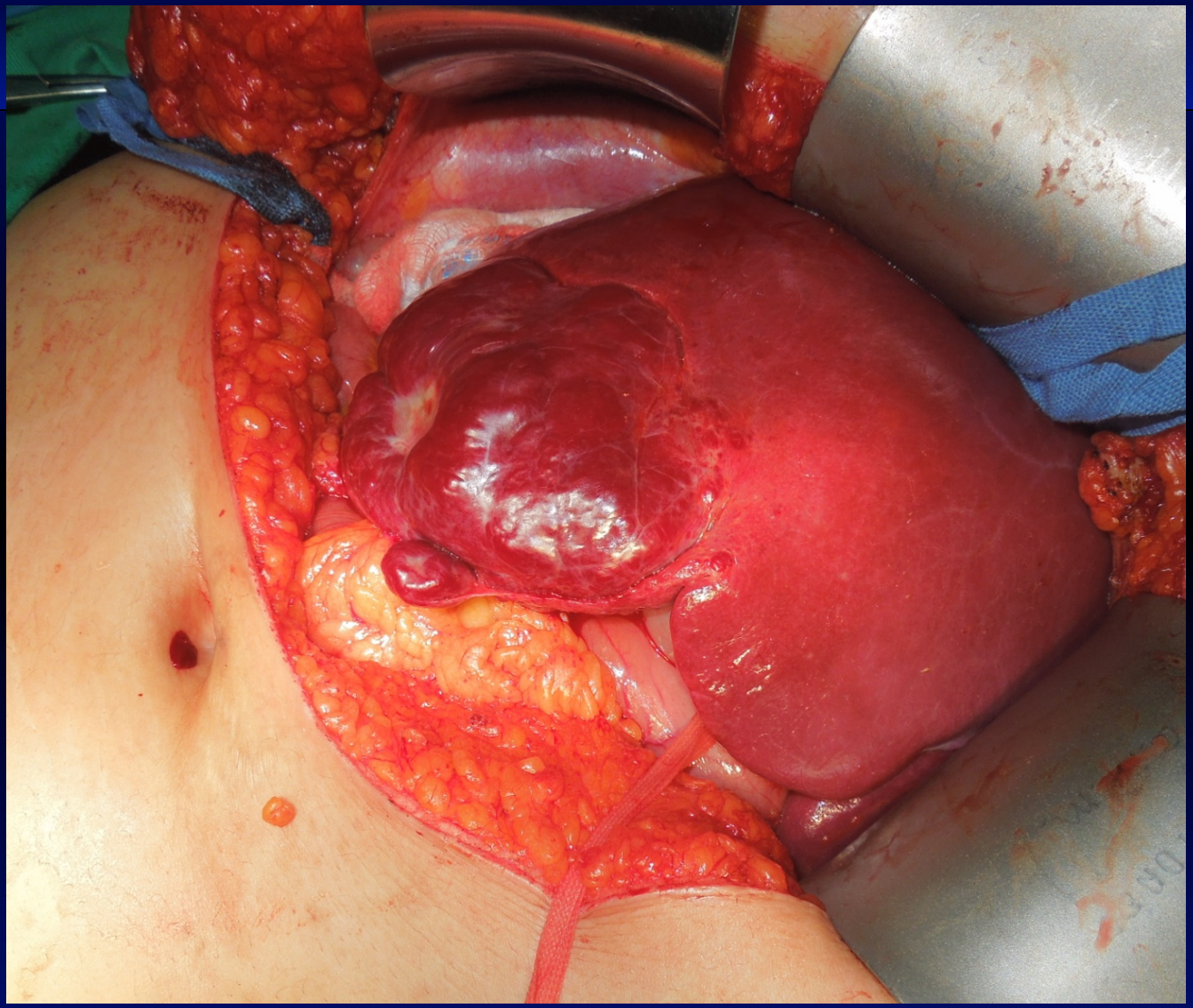
Hemangioma hepático
Colelitíase