SOBED 2018

XII Simpósio Internacional de Endoscopia Digestiva da SOBED
XIII Congresso Norte-Nordeste de Gastroenterologia
XXXIII Congresso da Regional Norte-Nordeste de Coloproctologia
I Congresso Norte-Nordeste do Colégio Brasileiro de Cirurgia Digestiva
VI GastroParaíba

17 a 19 de maio | Centro de Convenções de João Pessoa | PB | 2018

Metástase hepática de tumor colorretal: qual a evidência atual?

Orlando Jorge M. Torres
Professor Titular
Chefe do Serviço de Cirurgia do Aparelho Digestivo
Universidade Federal do Maranhão

Ressecção hepática

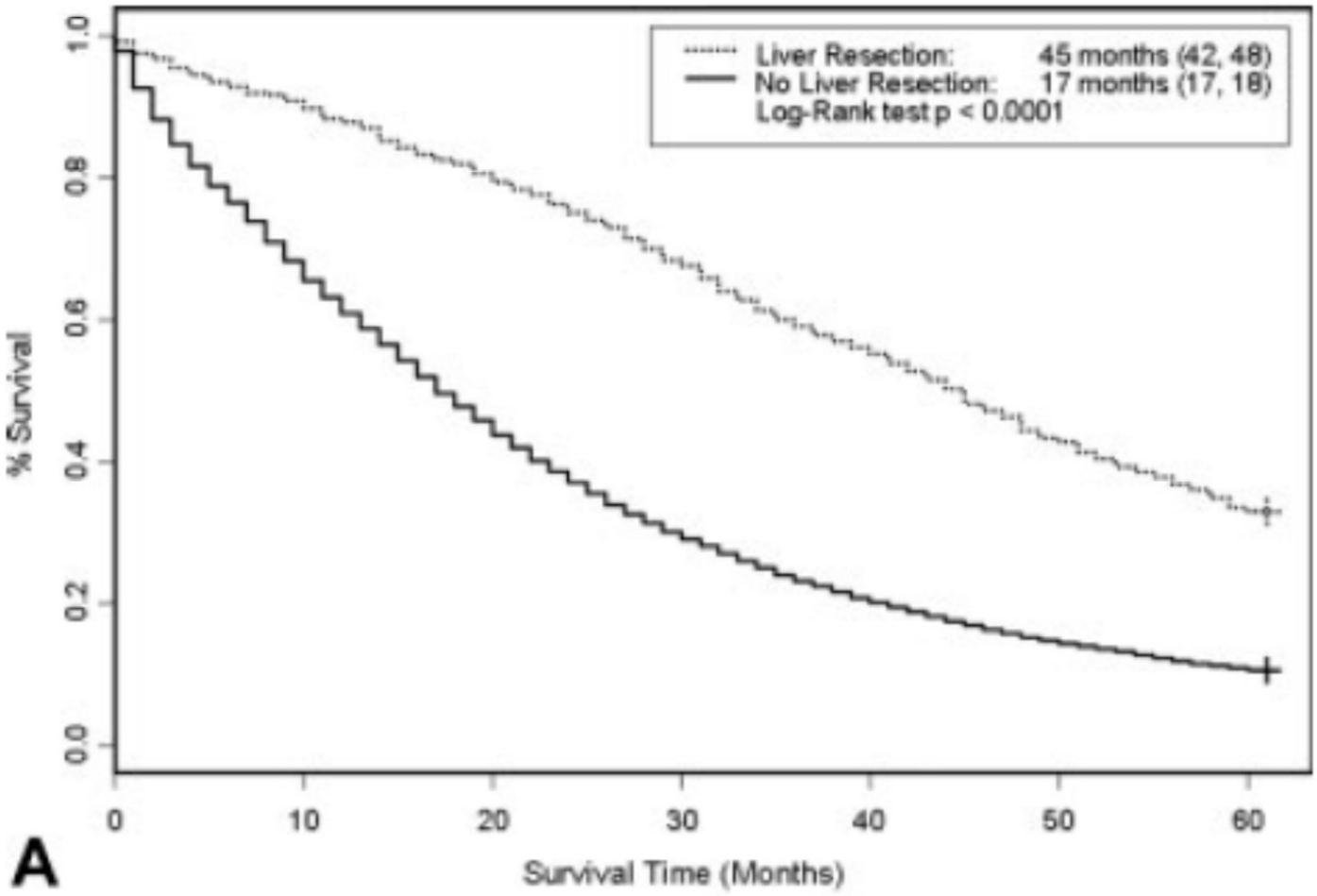

- A ressecção hepática esteve associada com aumento na sobrevida.

Cummings LC, et al. Cancer 109:718-726, 2007

Resultados em meta colo-retal

FIGURE 2

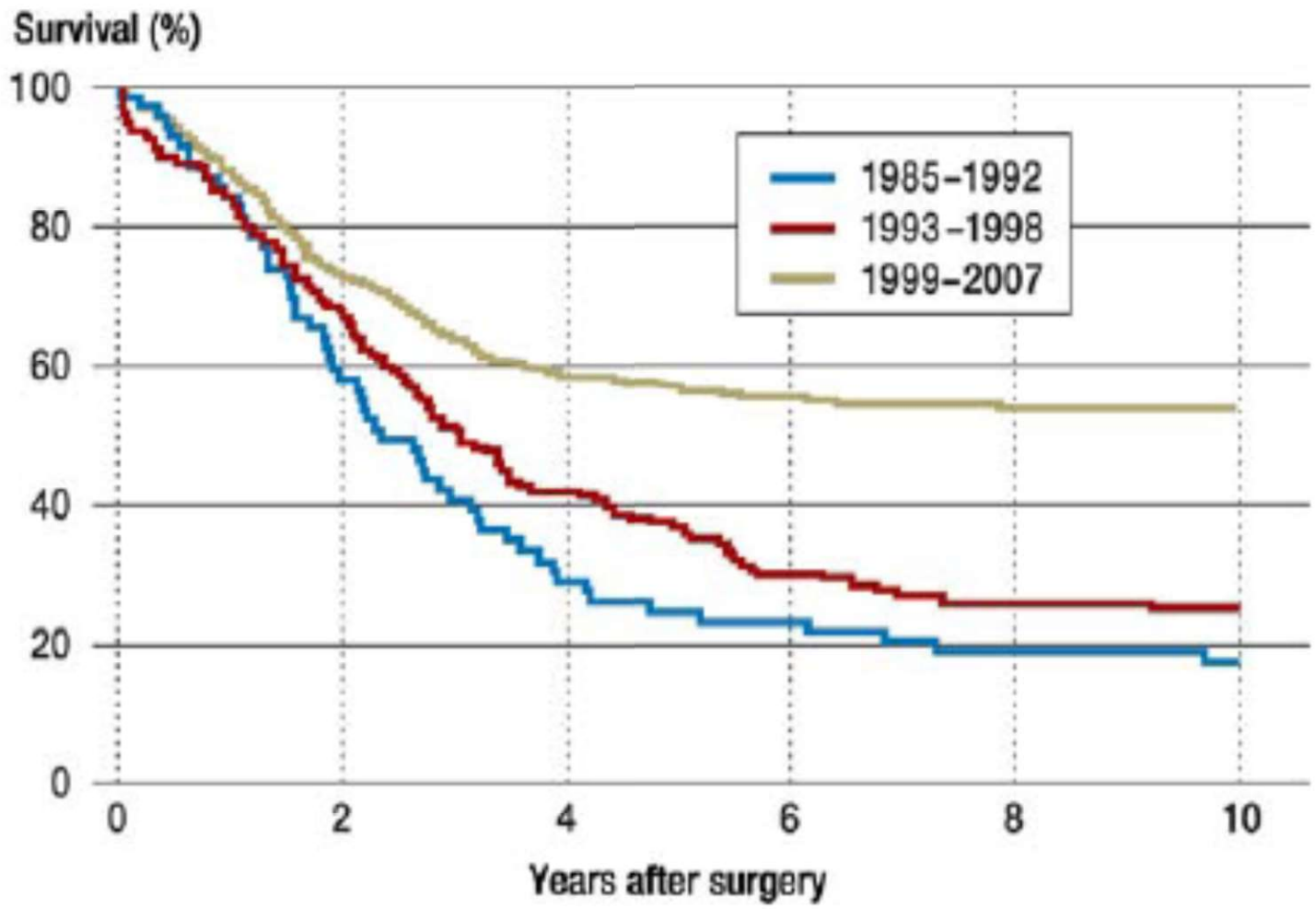

Neumann UP et al – Dtsch Arztebl Int 2010;107:335-42

Critérios de irressecabilidade

Antes

- Quatro ou mais metástases
- Tamanho > 5 cm
- Doença bilateral
- Margem cirúrgica < 1 cm
- Doença extra-hepática
- Escore prognóstico

Depois

- Incapacidade de ressecção R0
- Margem histológica positiva
- Inabilidade de ressecar toda doença detectável
- Progressão da doença apesar da QT

Charnsangavej C, et al. Ann Surg Oncol, 2006;13:1261-8

Equipe multidisciplinar

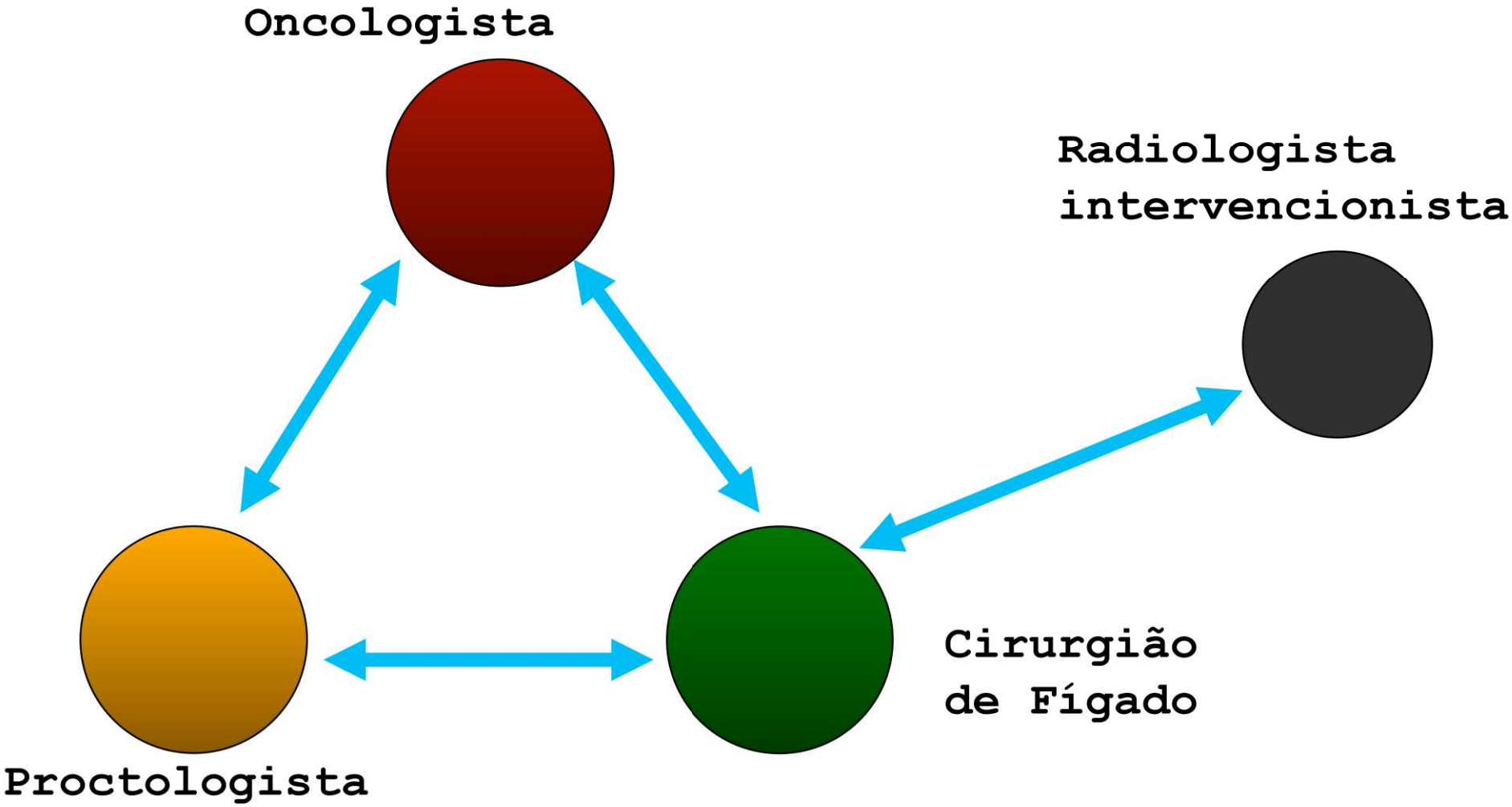

Qumioterapia

- Promover downsize e elevar a taxa de ressecção curativa.
- Converter doença irressecável para ressecável.
- Identificar os respondedores em pacientes de risco elevado de recorrência, para pós-operatória.
- Pacientes com múltiplas lesões, selecionar quem progride apesar da QT, que podem não se beneficiar da ressecção.

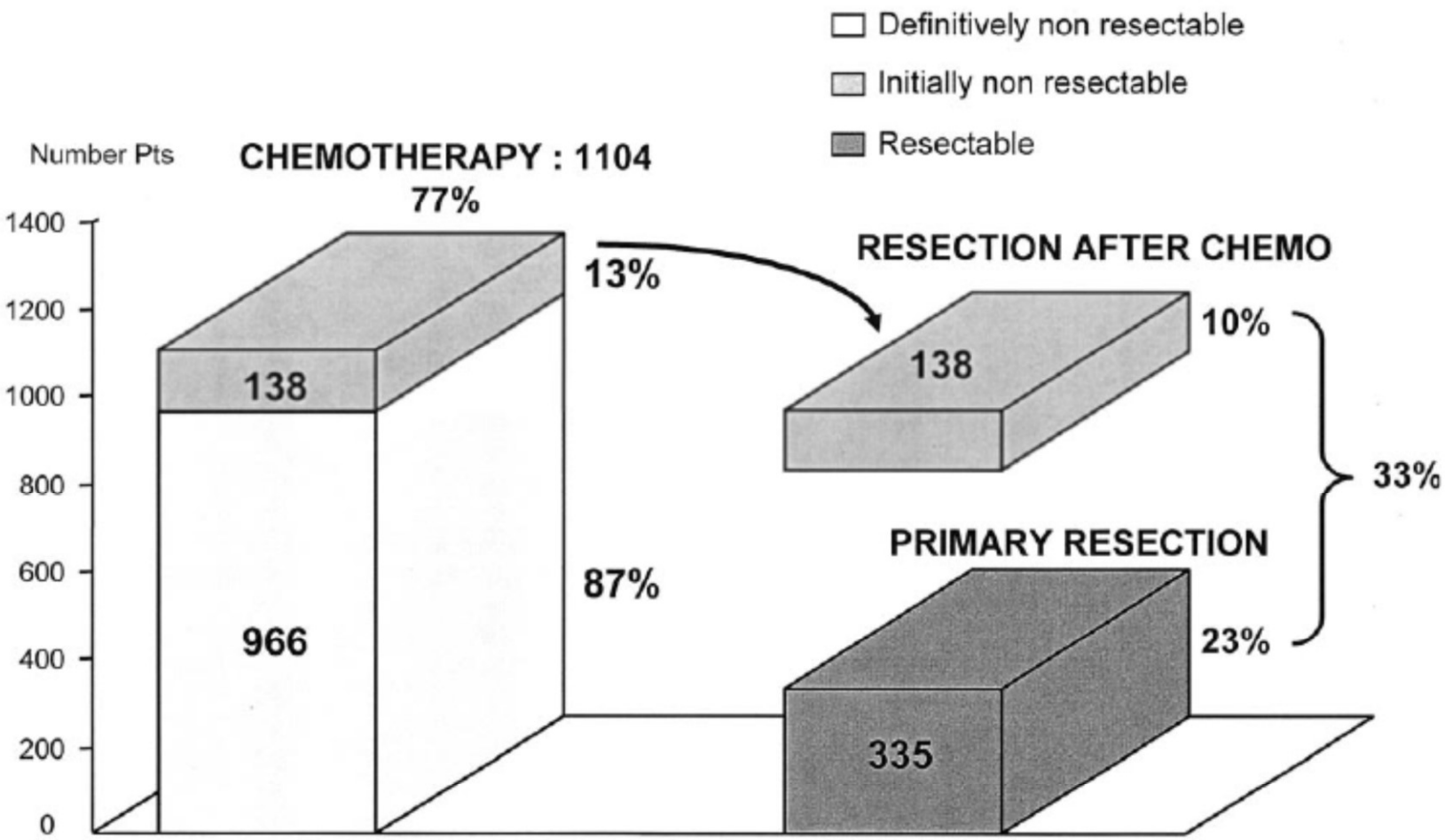

Adam R, et al. Ann Surg 2004;240:644-58

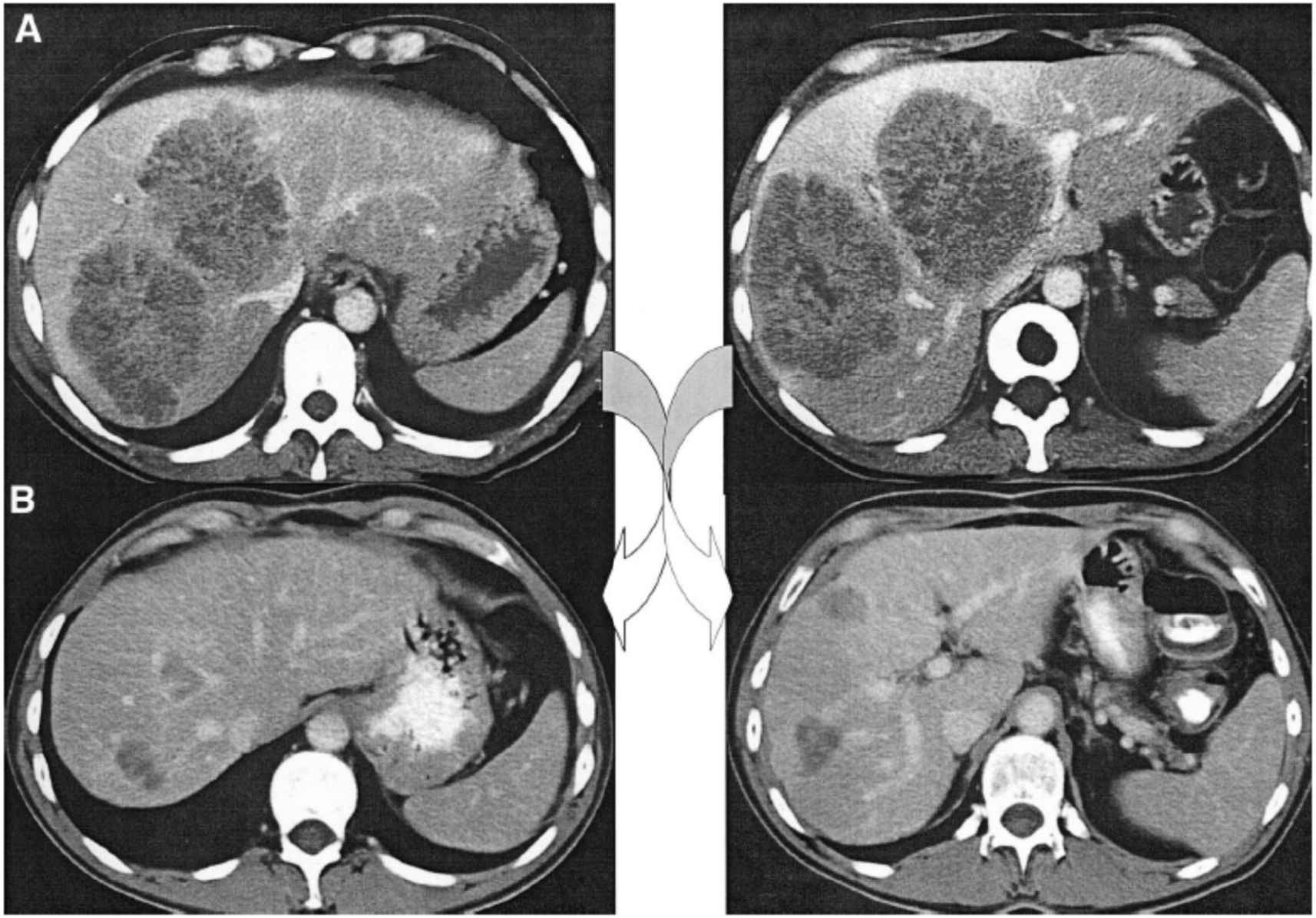

Adam R, et al. Ann Surg 2004;240:644-58

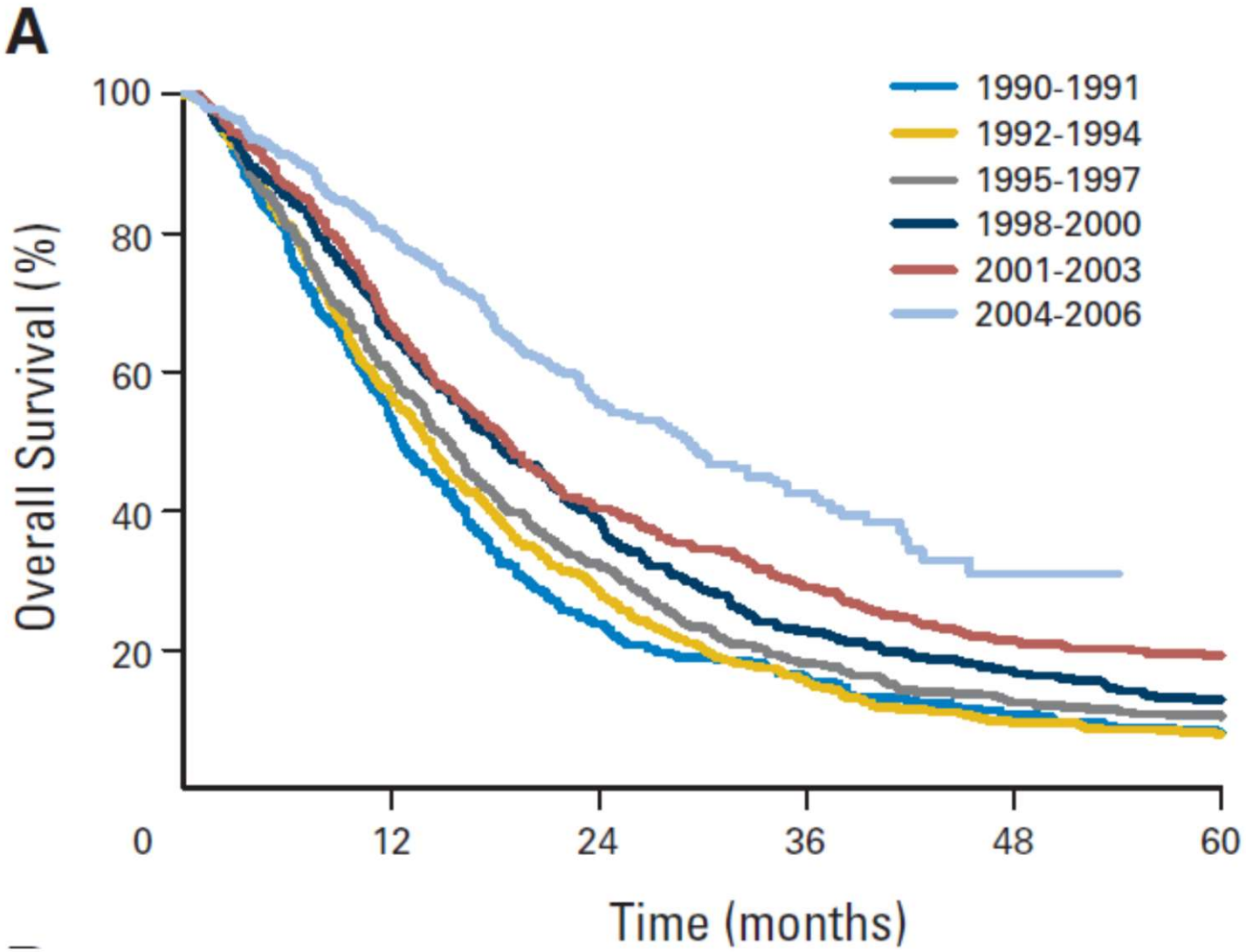

Kopetz S, et al. J Clin Oncol 2009;27:3677-83

Remanescente hepático

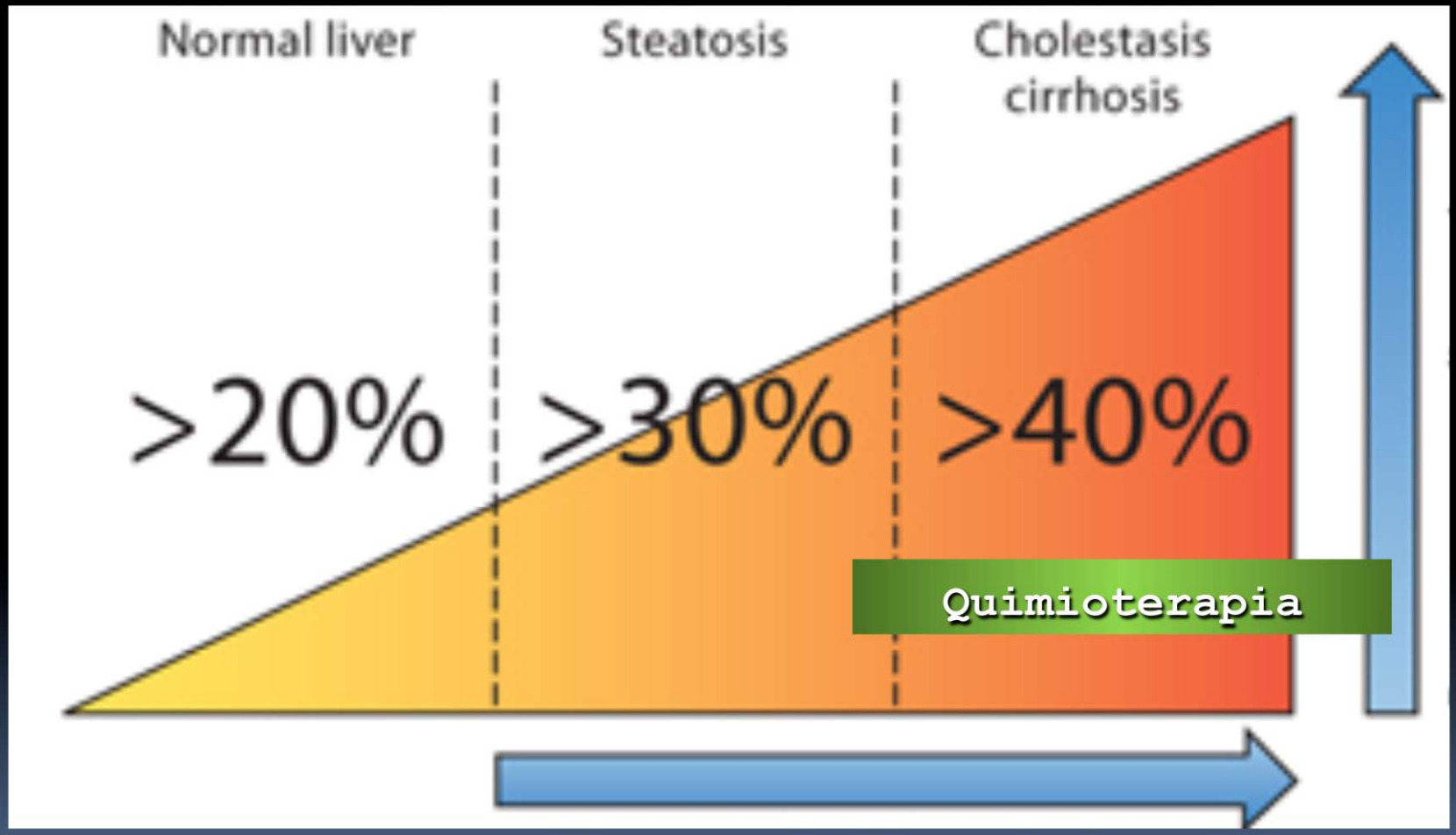

Abdalla EK, et al. Dig Surg 2008;25:421-9

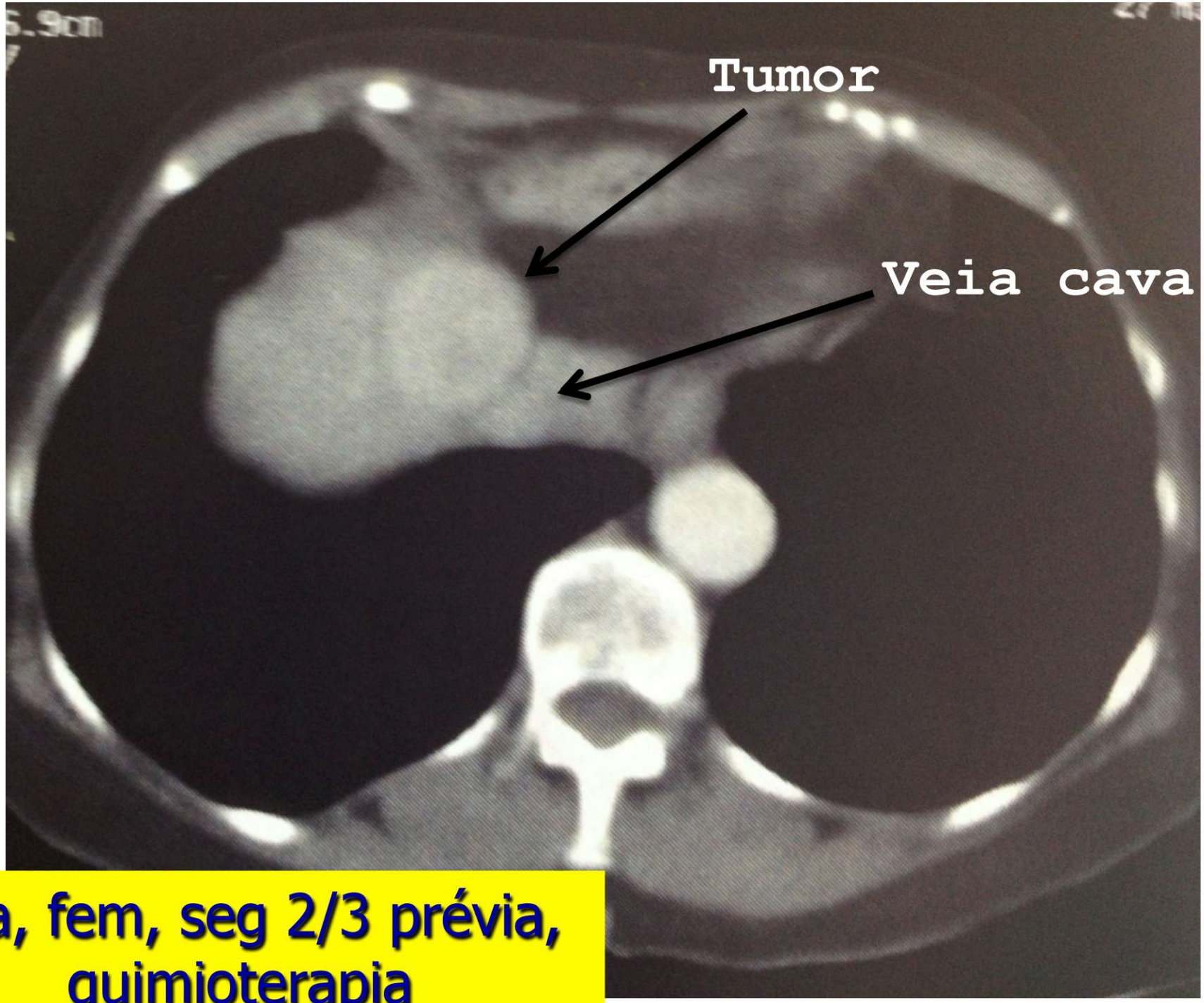

68a, fem, seg 2/3 prévia, quimioterapia

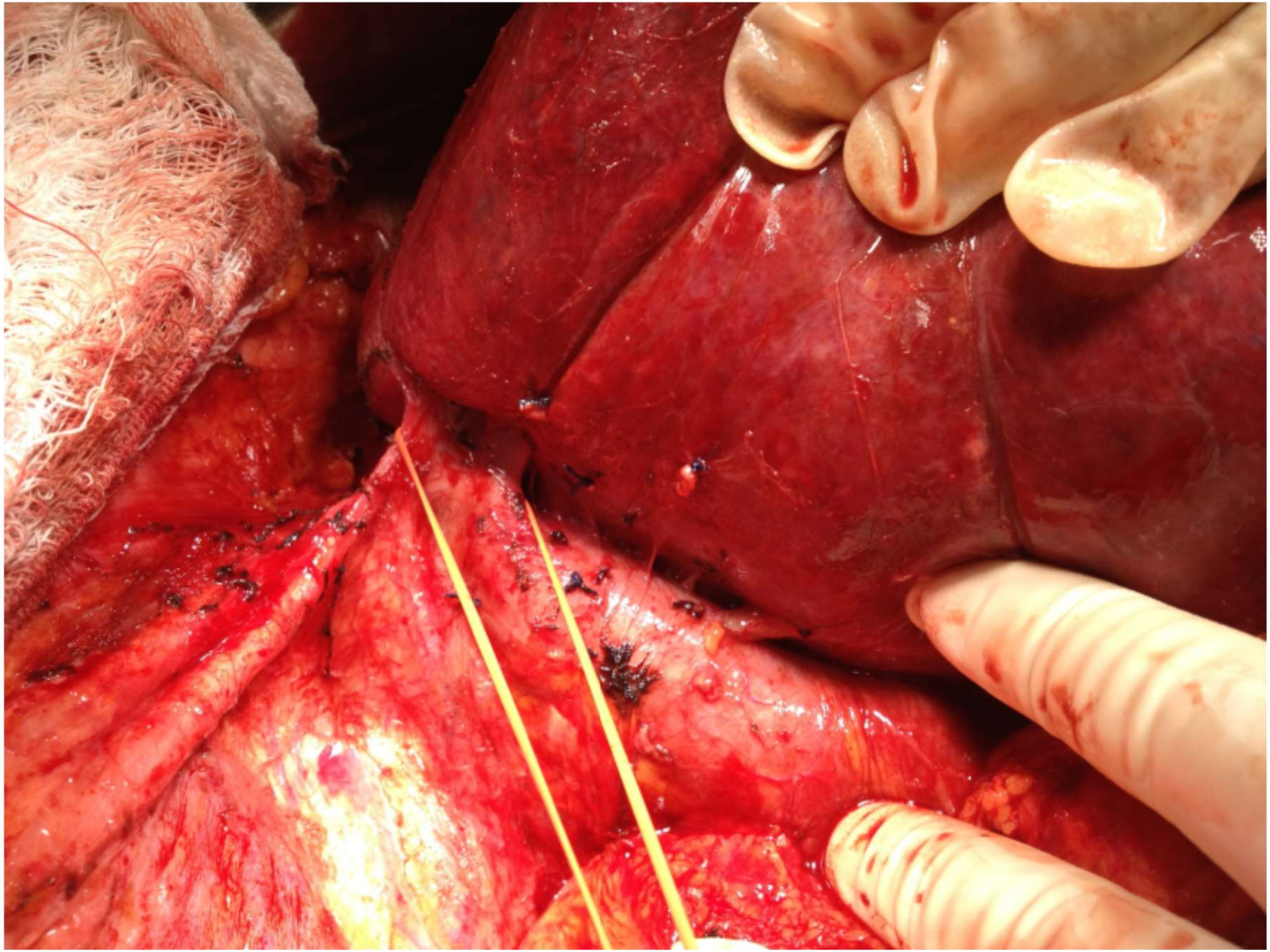

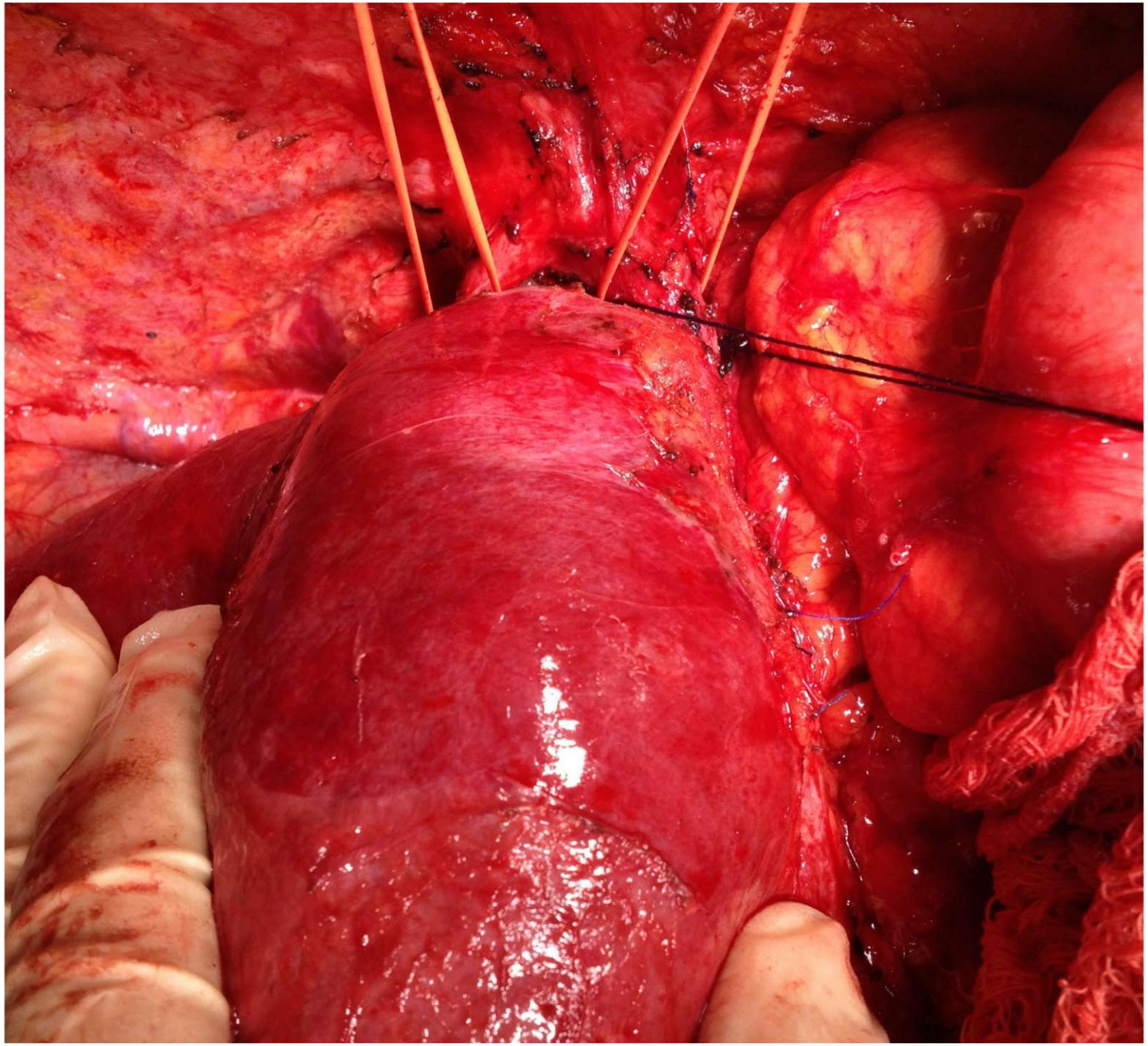

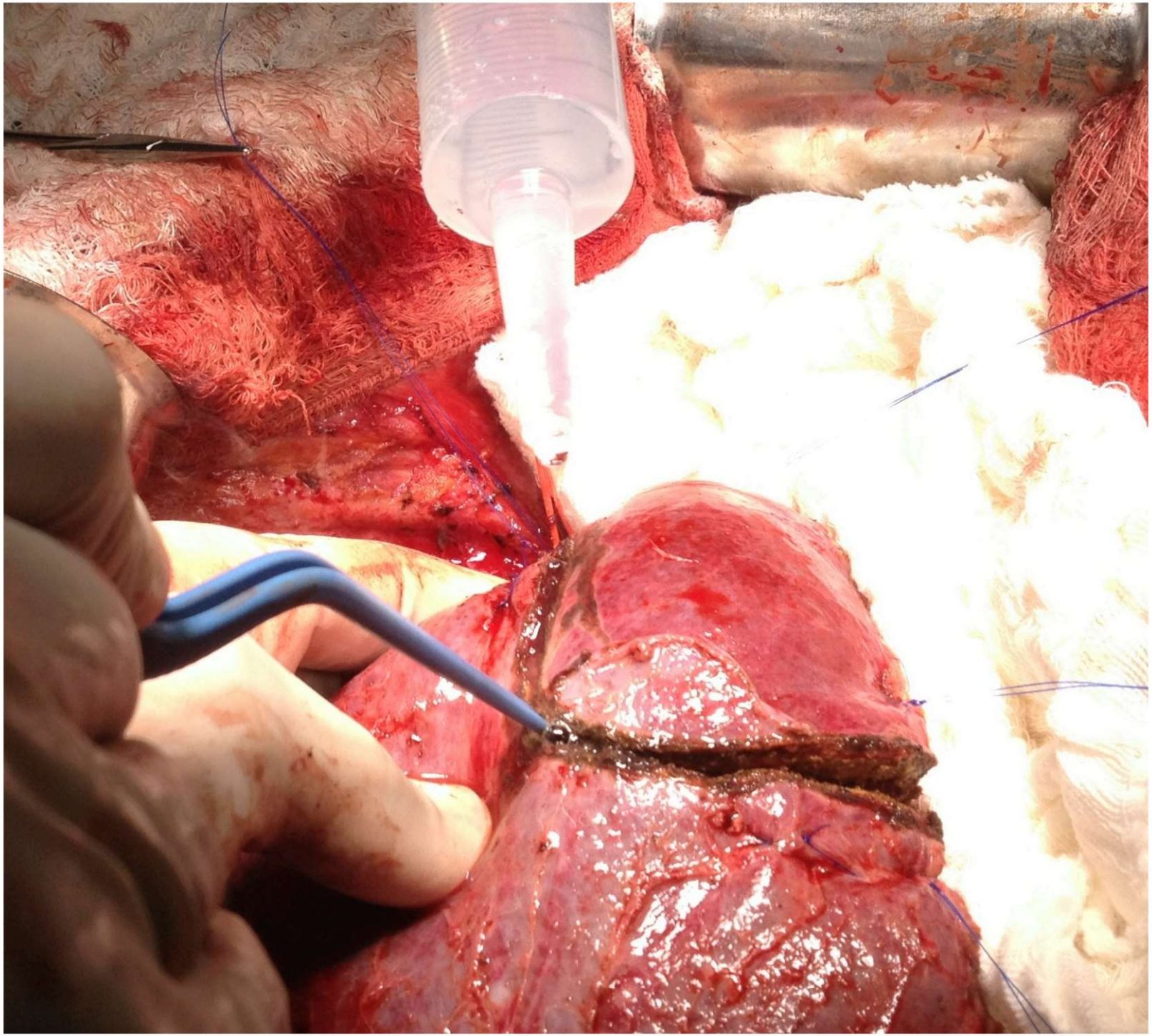

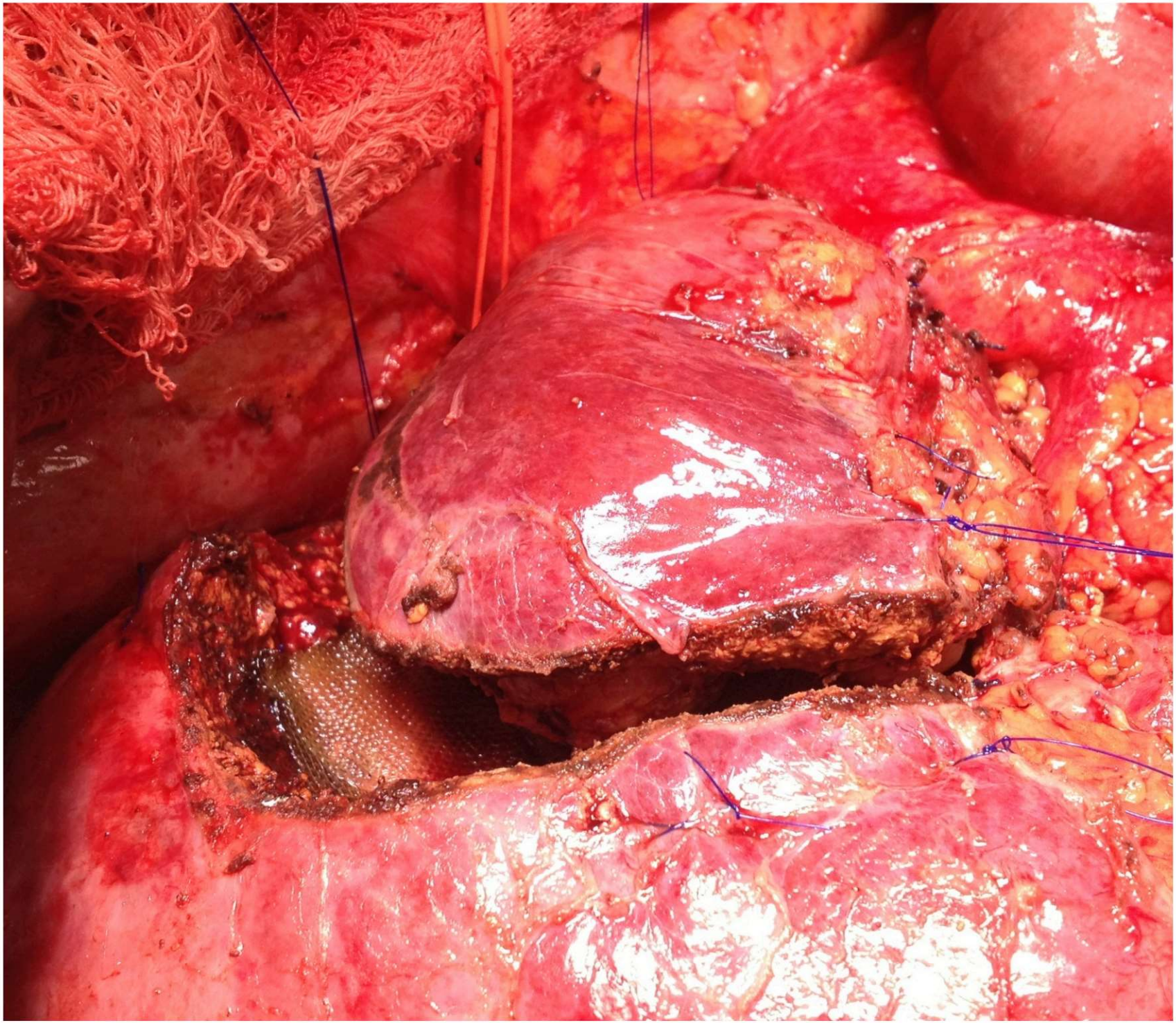

Volumetria

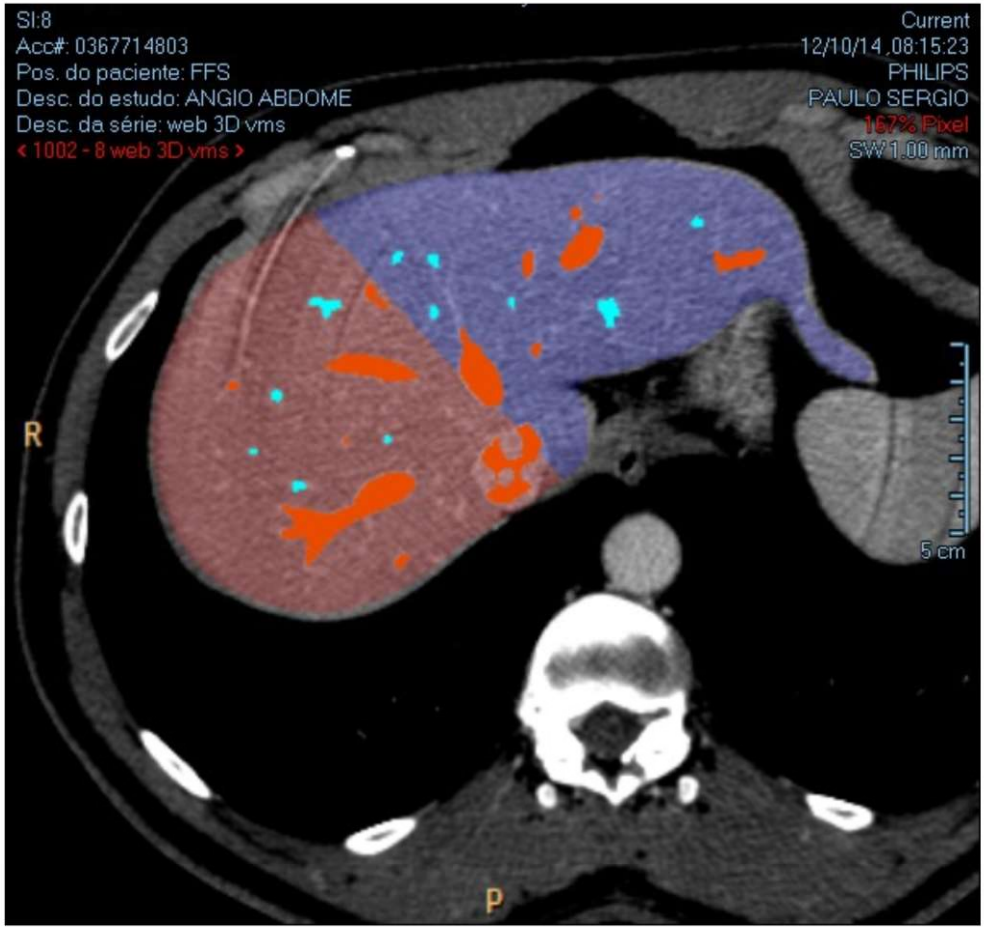
SI:8
Acc#: 0367714803
Pos. do paciente: FFS
Desc. do estudo: ANGIO ABDOME
Desc. da série: web 3D vms
< 1002 - 8 web 3D vms >
Current
12/10/14 ,08:15:23
PHILIPS
PAULO SERGIO
167% Pixel
SW1.00 mm
R
5 cm
P

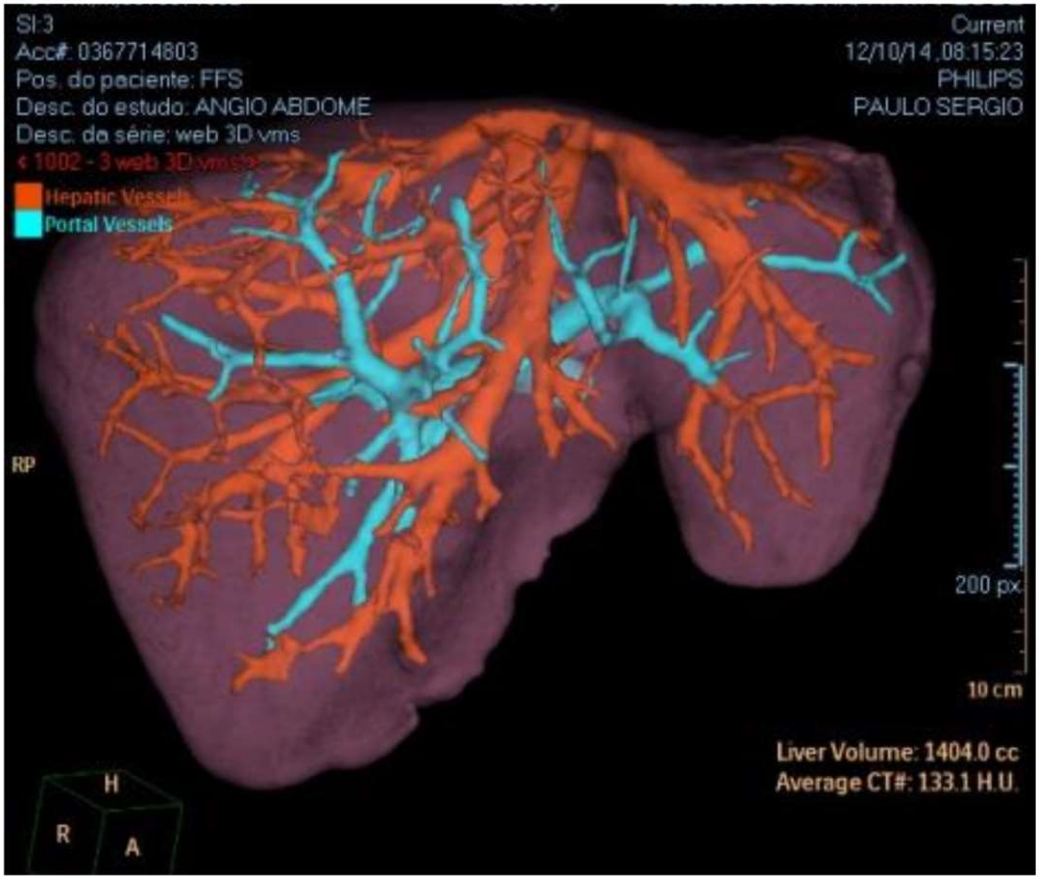
SI:3
Acc#: 0367714803
Pos. do paciente: FFS
Desc. do estudo: ANGIO ABDOME
Desc. da série: web 3D vms
Current
12/10/14 ,08:15:23
PHILIPS
PAULO SERGIO
Hepatic Vessels
Portal Vessels
RP
200 px
10 cm
Liver Volume: 1404.0 cc
Average CT#: 133.1 H.U.
H
R
A

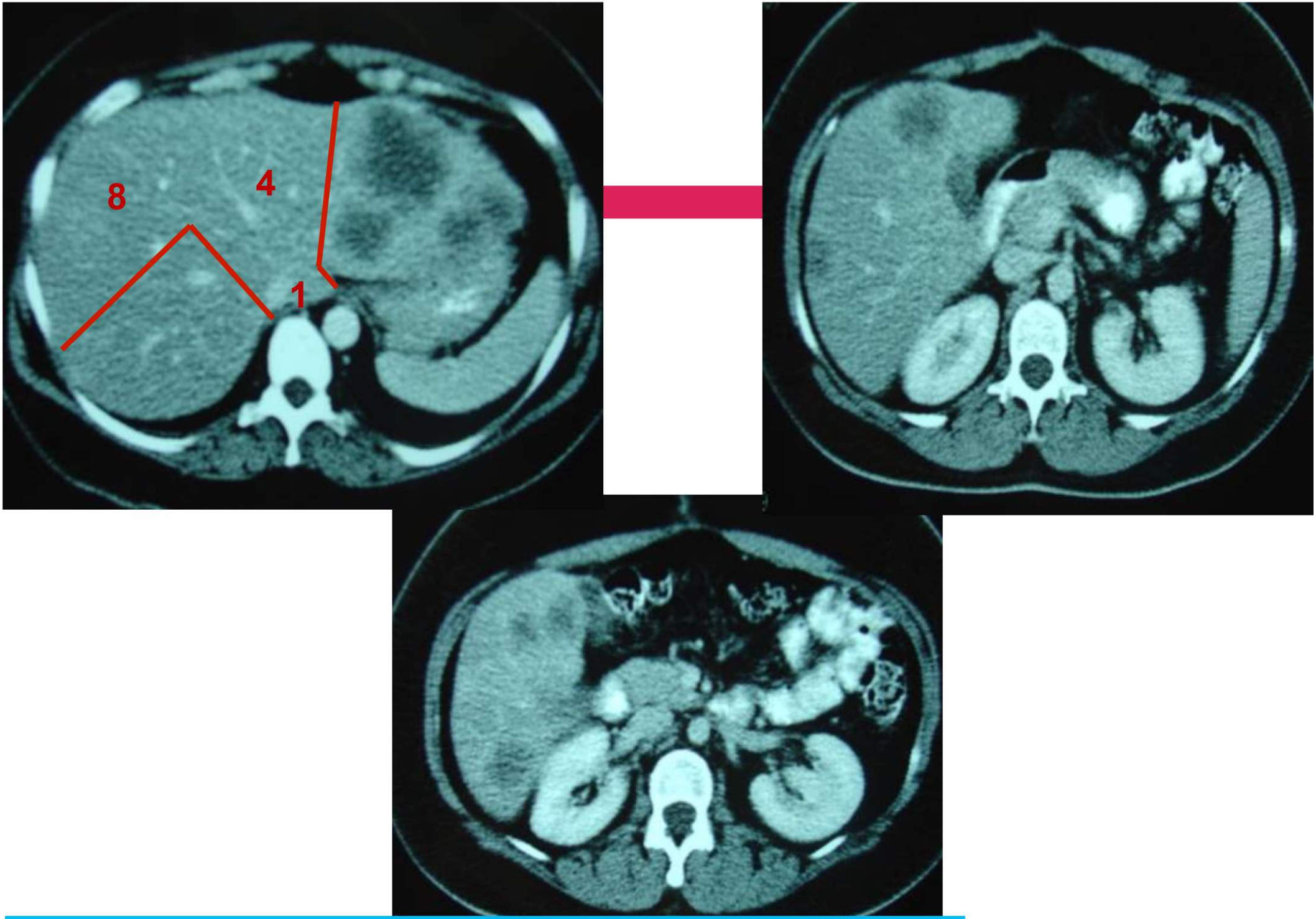

Cortesia: Prof. Paulo Herman (USP)

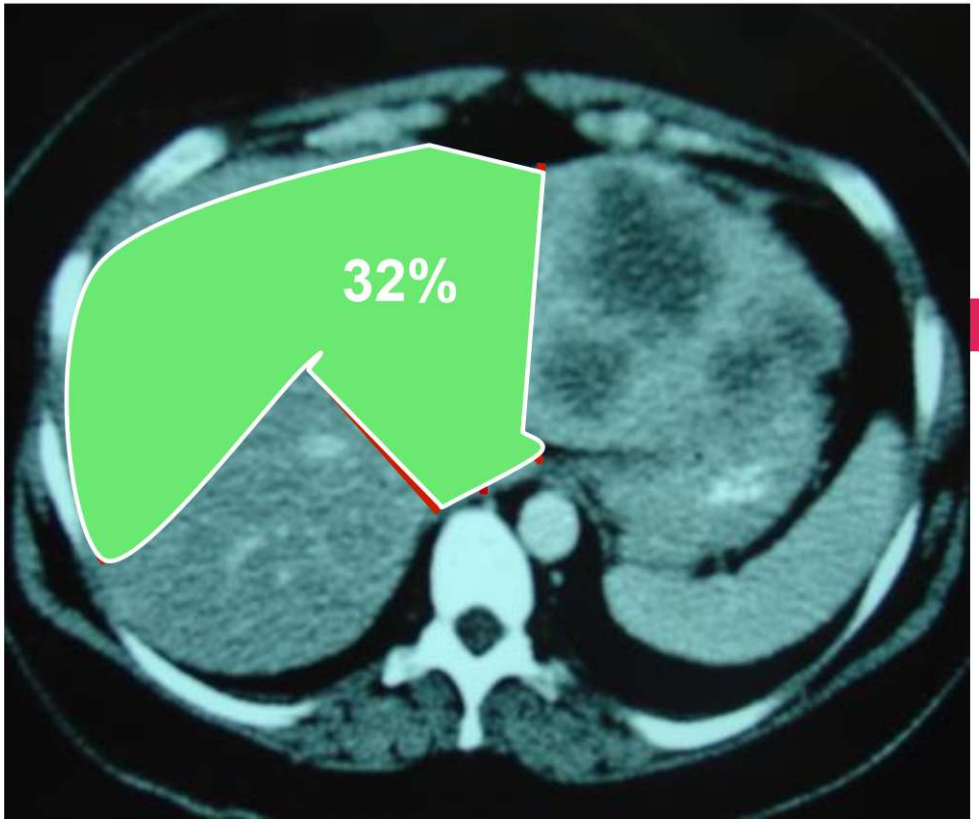

Cortesia: Prof. Paulo Herman (USP)

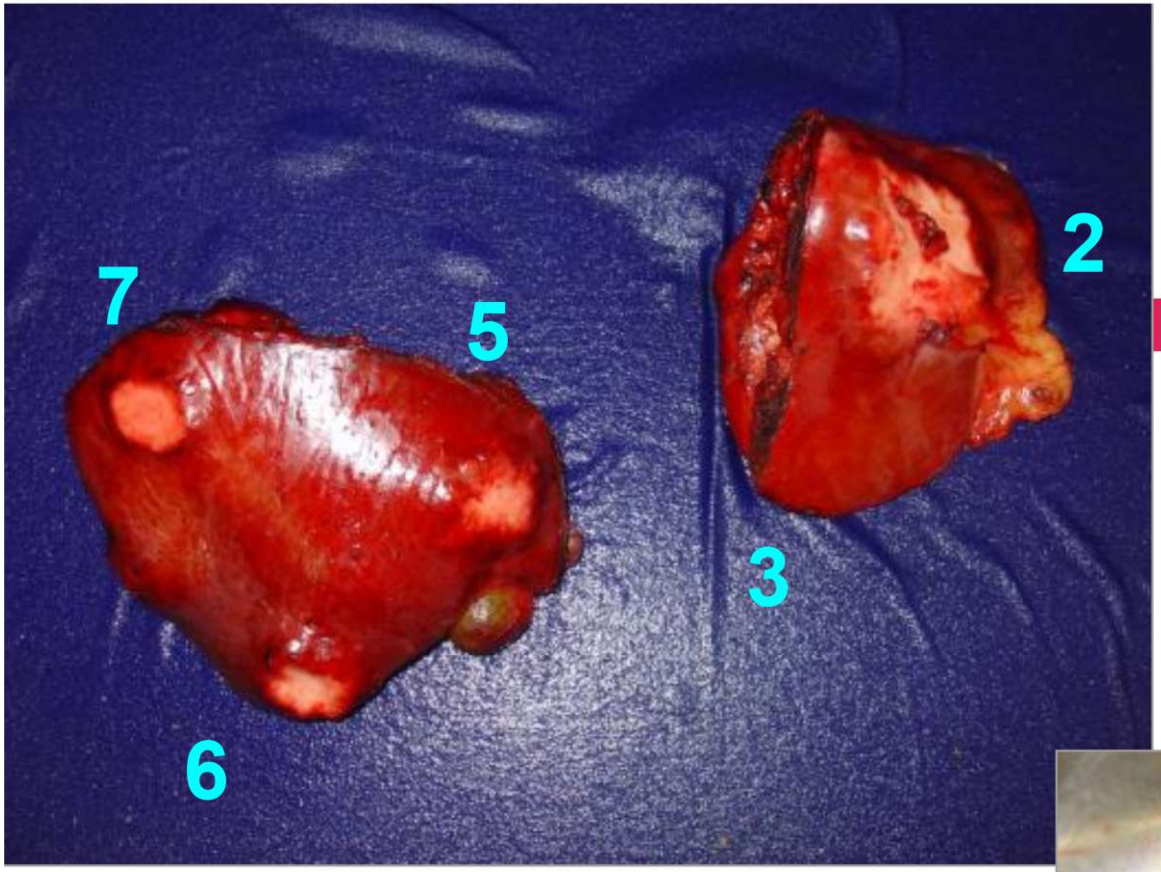

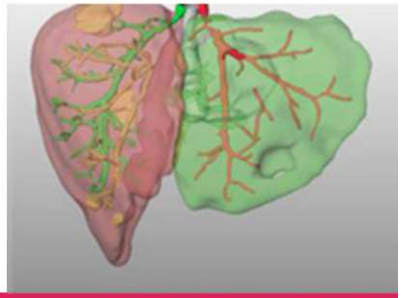

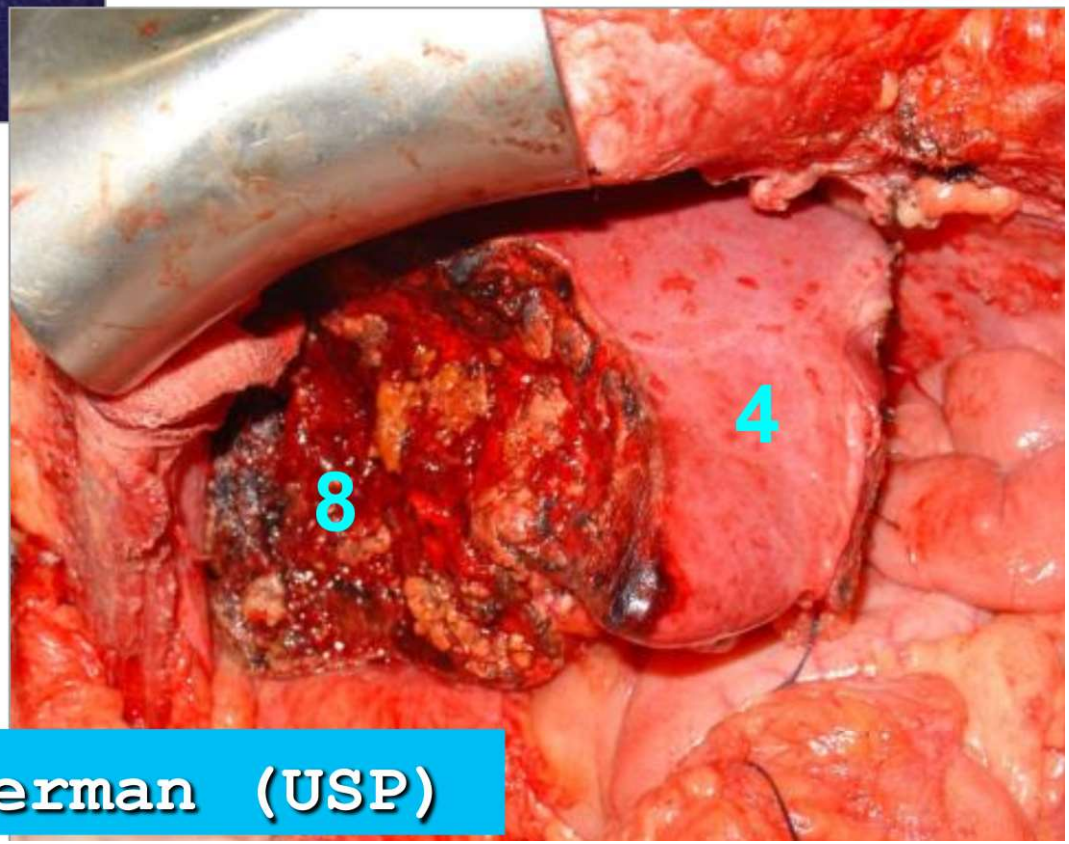

Cortesia: Prof. Paulo Herman (USP)

Hepatotoxicidade

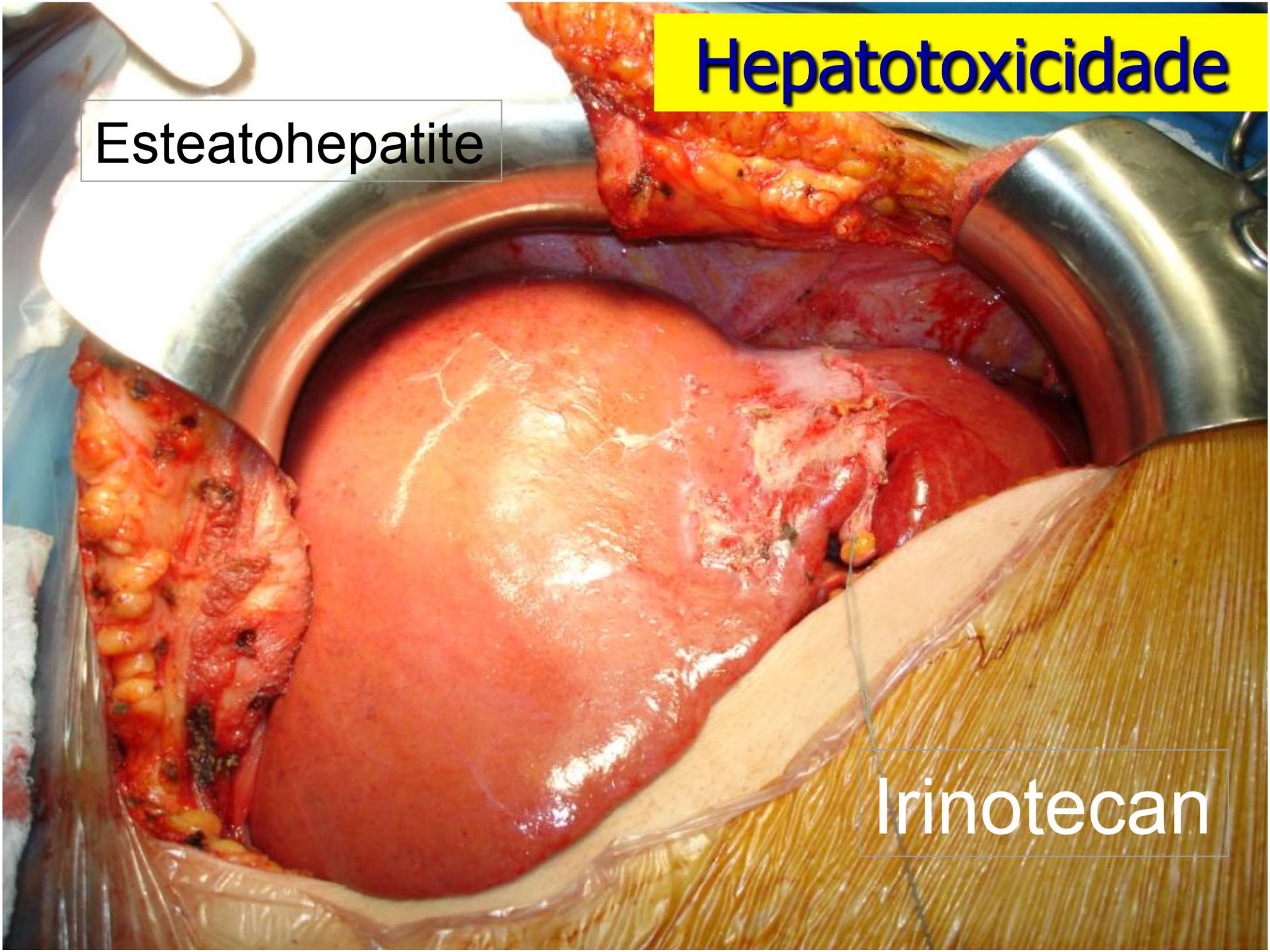

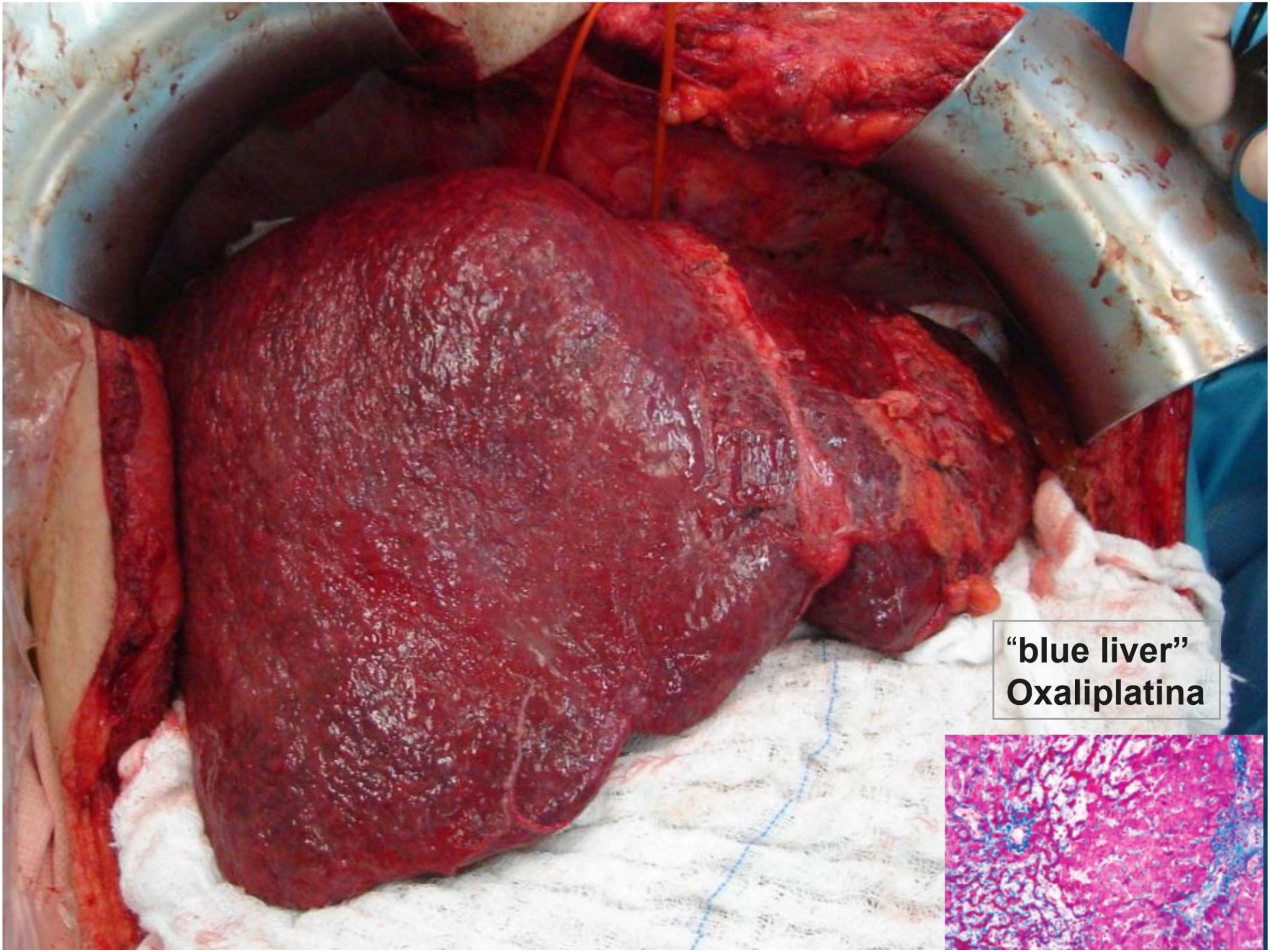
“blue liver”
Oxaliplatina

Embolização da veia porta

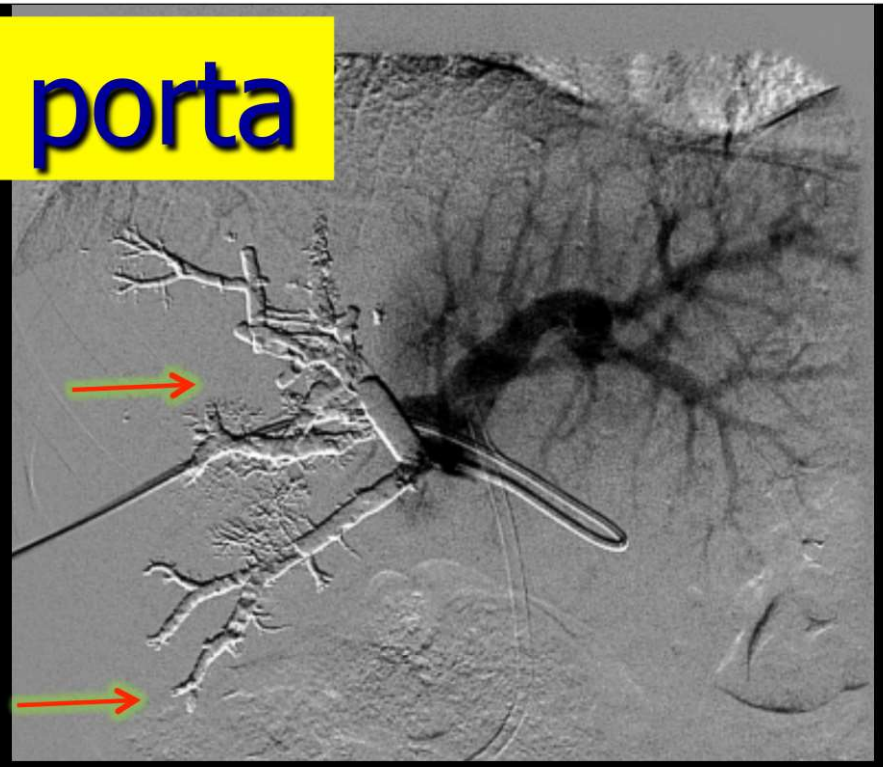

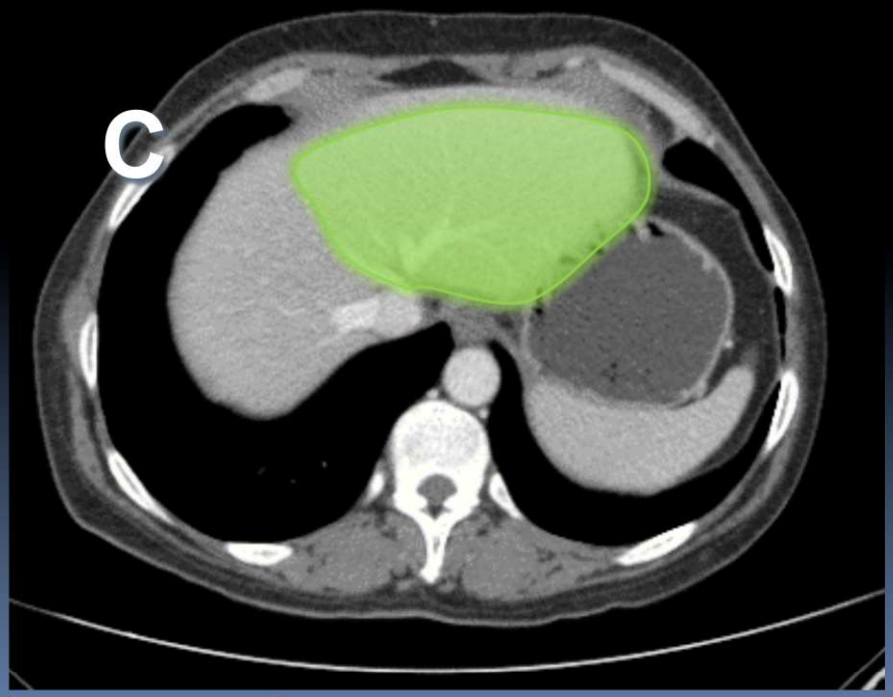

Carnevale F, et al, In Torres OJM - Ed Rubio. In press

EMBOLIZAÇÃO DA VEIA PORTA

EMBOLIZAÇÃO DA VEIA PORTA

Makuuchi M, et al. Surgery 1990

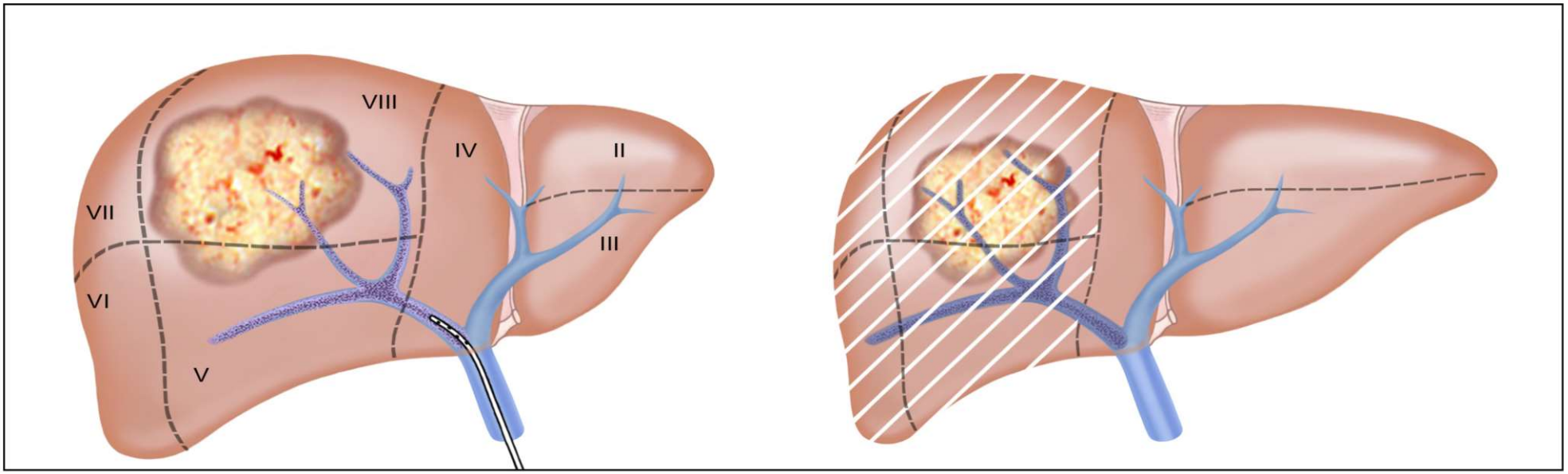

Embolização da veia porta

Madoff DC et al – Radiology 2003;227:251-60

Ligadura da veia porta

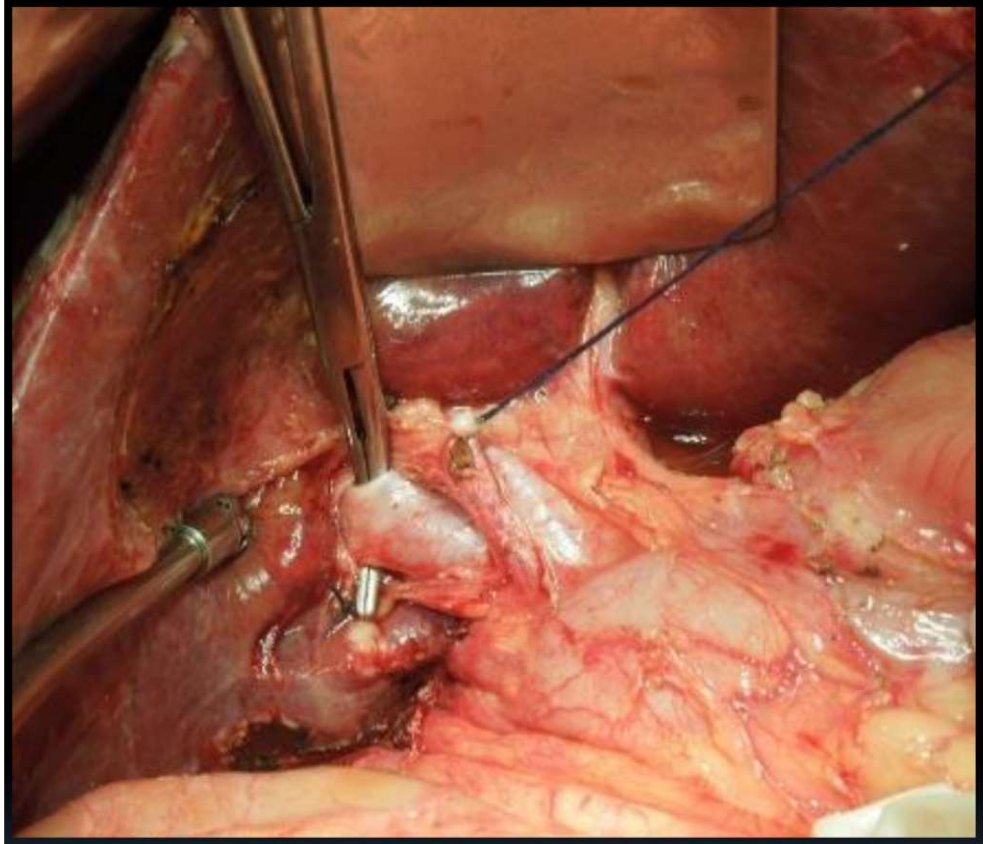

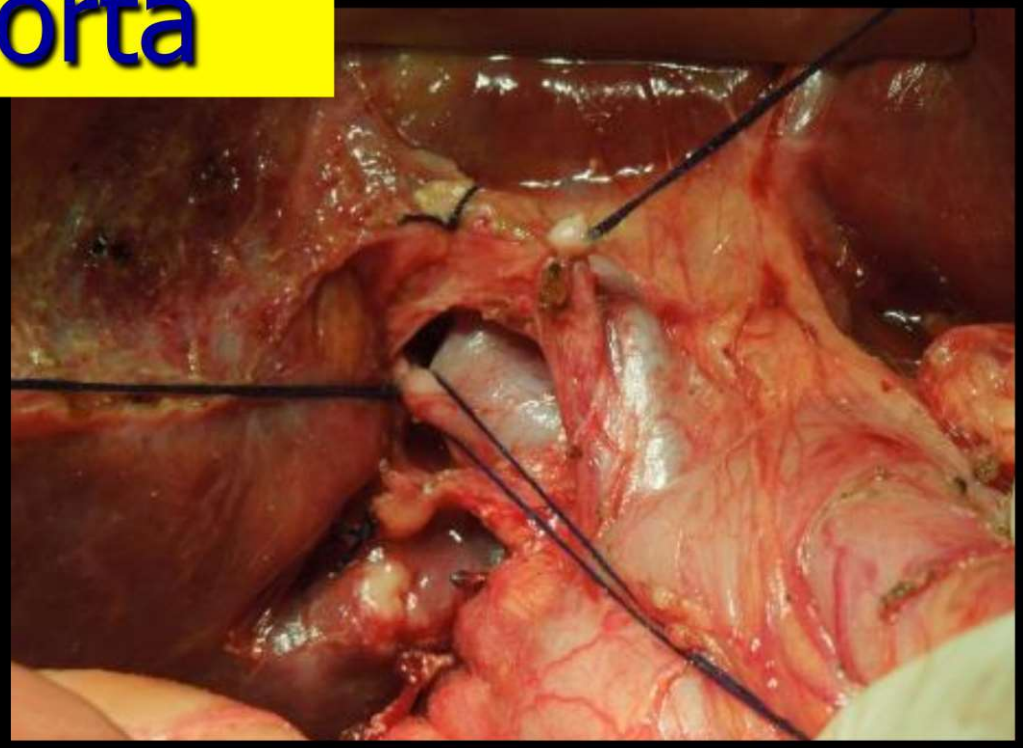

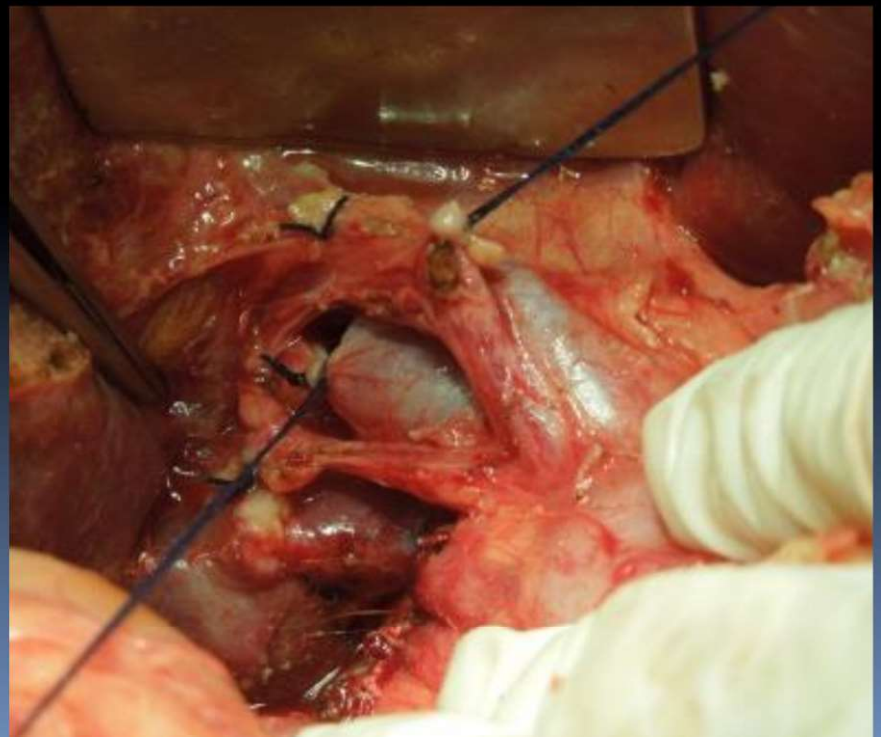

Ligadura da veia porta D

Liver Metastasis Resection: A Simple Technique That Makes It Easier

Metastasectomia

Eduardo de Santibañes · Rodrigo Sánchez Clariá · Martín Palavecino · Axel Beskow · Juan Pekolj

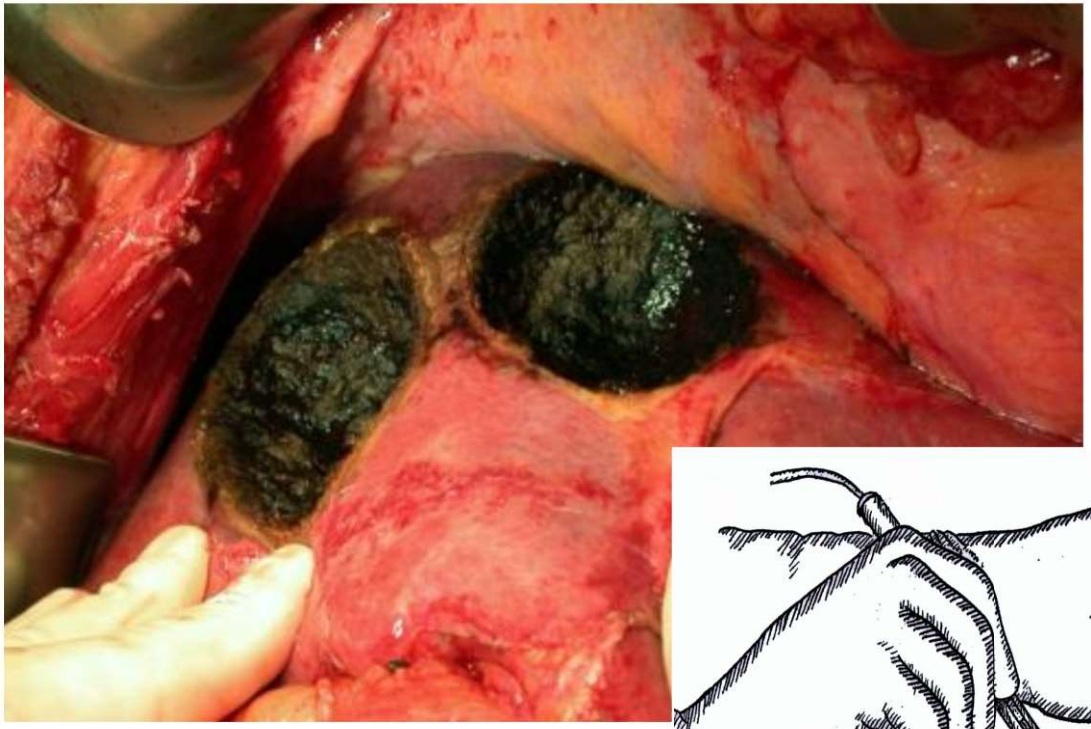

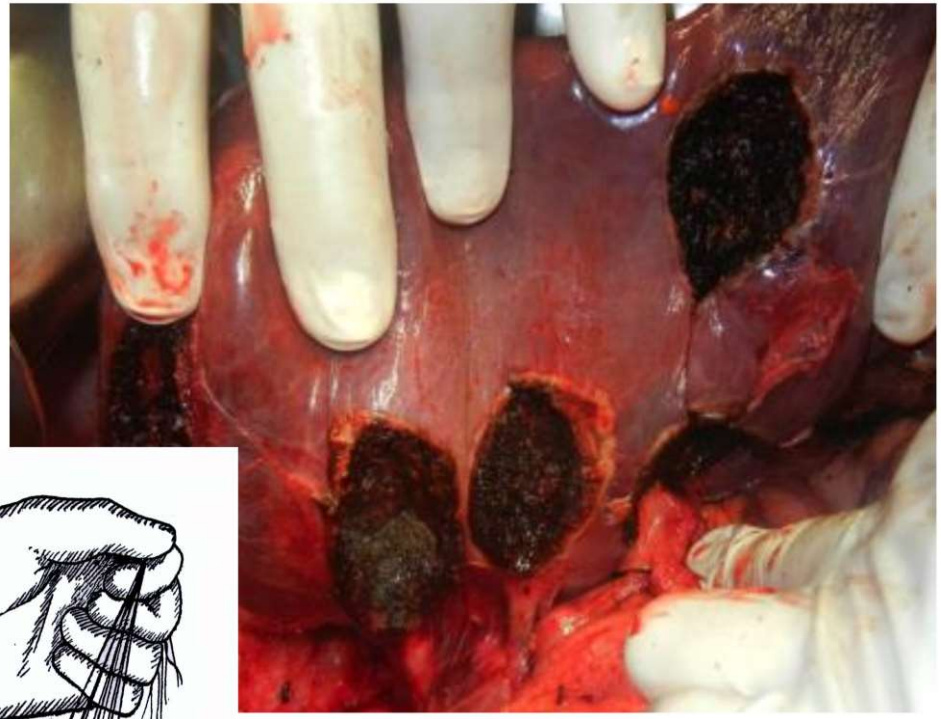

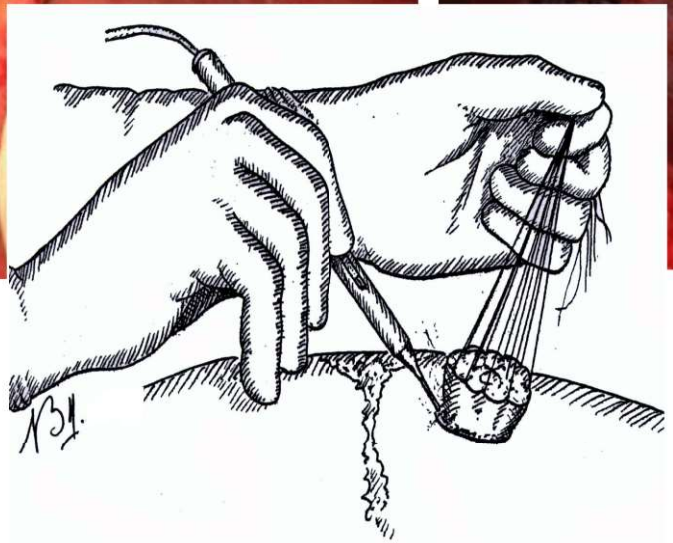

J Gastrointestinal Surg 2007

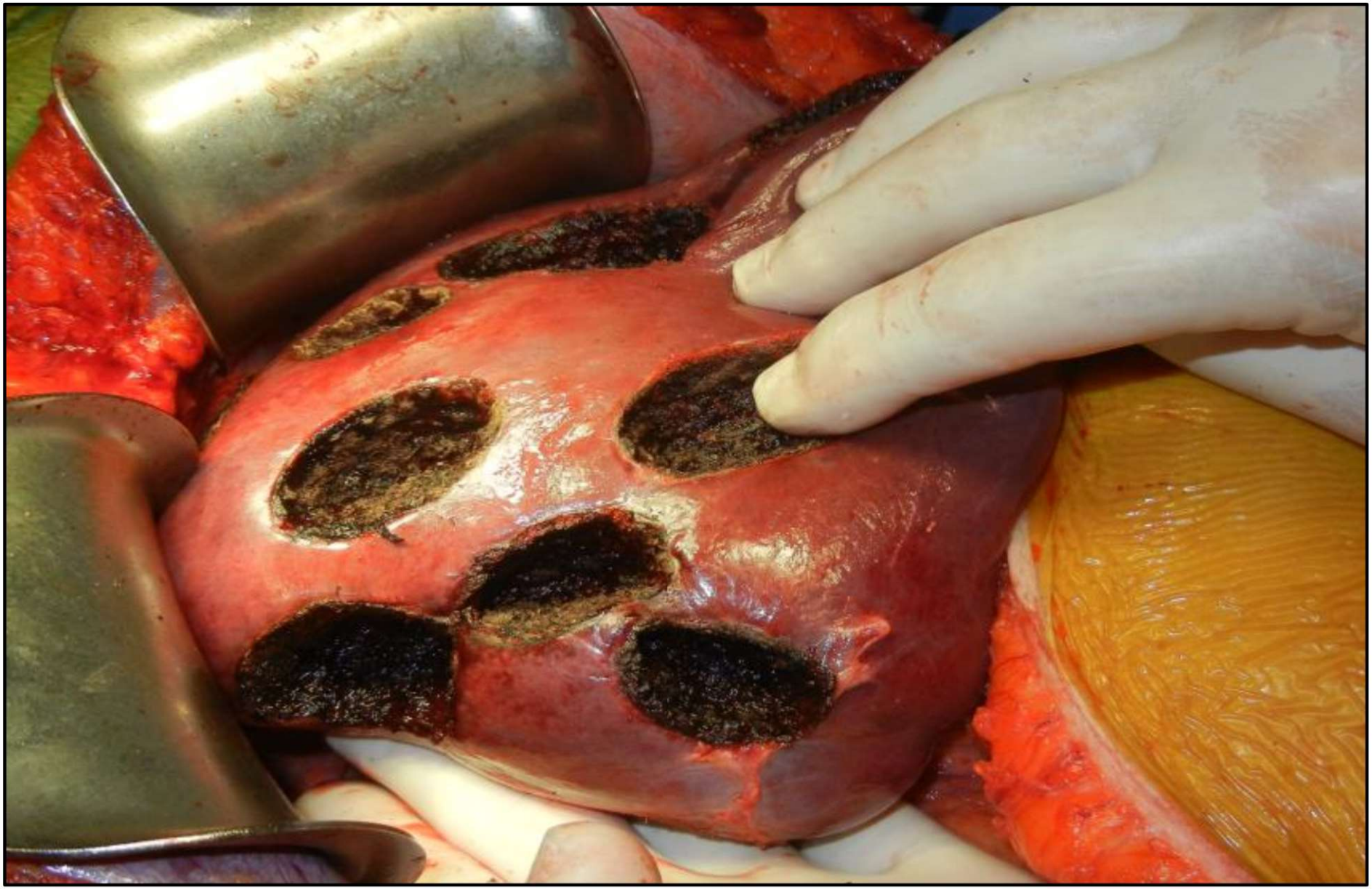

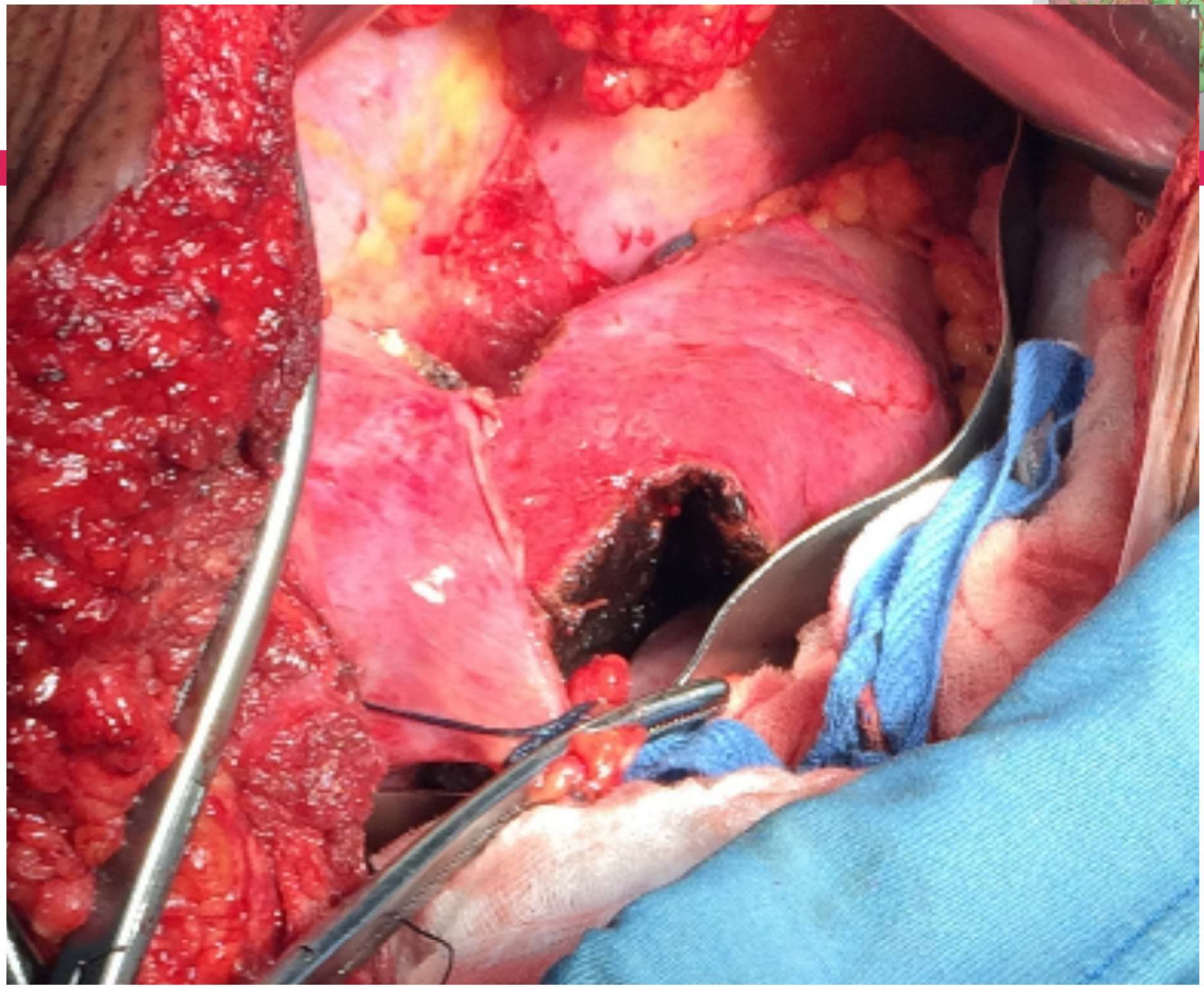


hospital
São Domingos

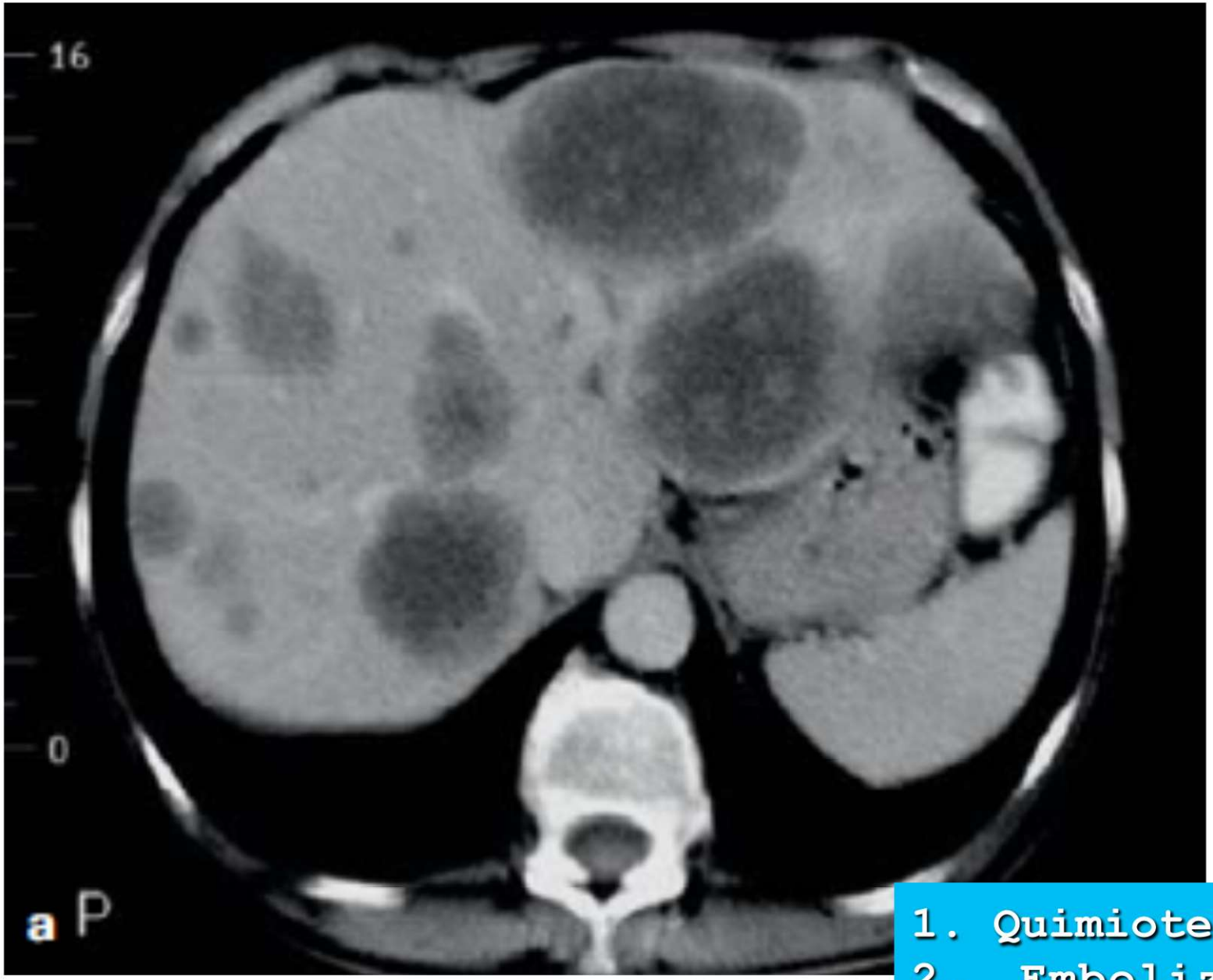

1. Quimioterapia
2. Embolização da veia porta
3. Operações dois tempos

Neumann UP et al – Dtsch Arztebl Int 2010;107:335-42

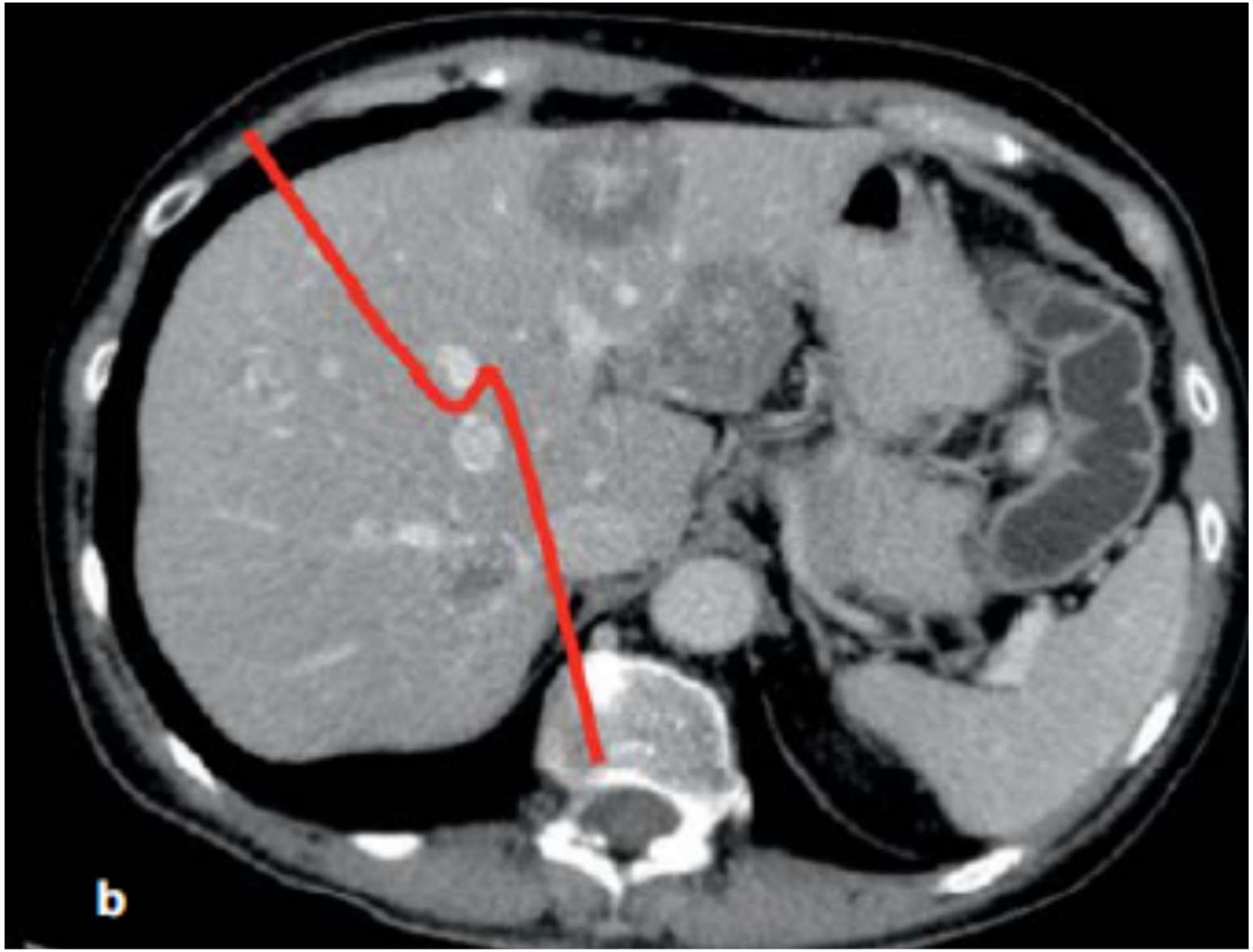

Neumann UP et al – Dtsch Arztebl Int 2010;107:335-42

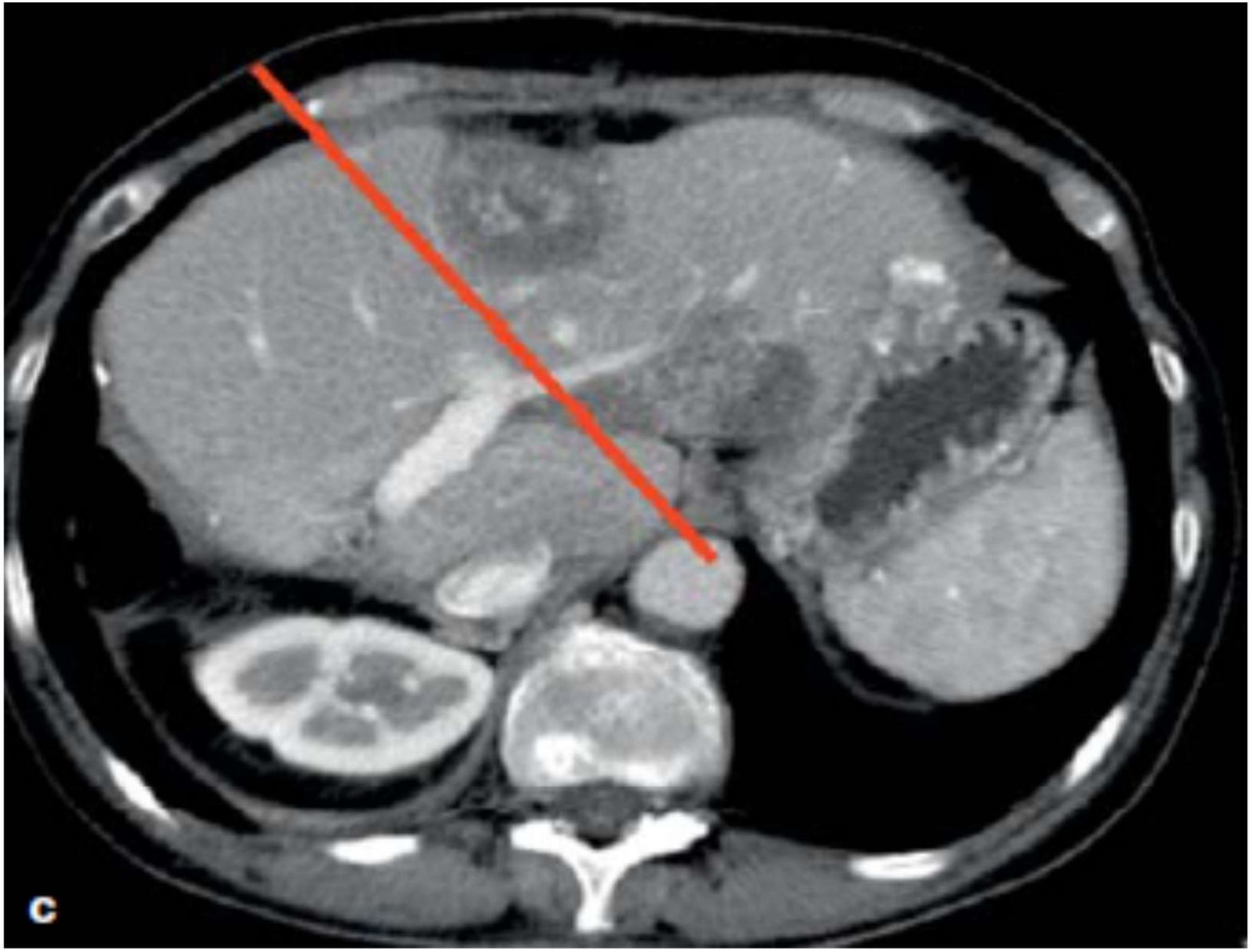

Neumann UP et al – Dtsch Arztebl Int 2010;107:335-42

Neumann UP et al - Dtsch Arztebl Int 2010;107:335-42

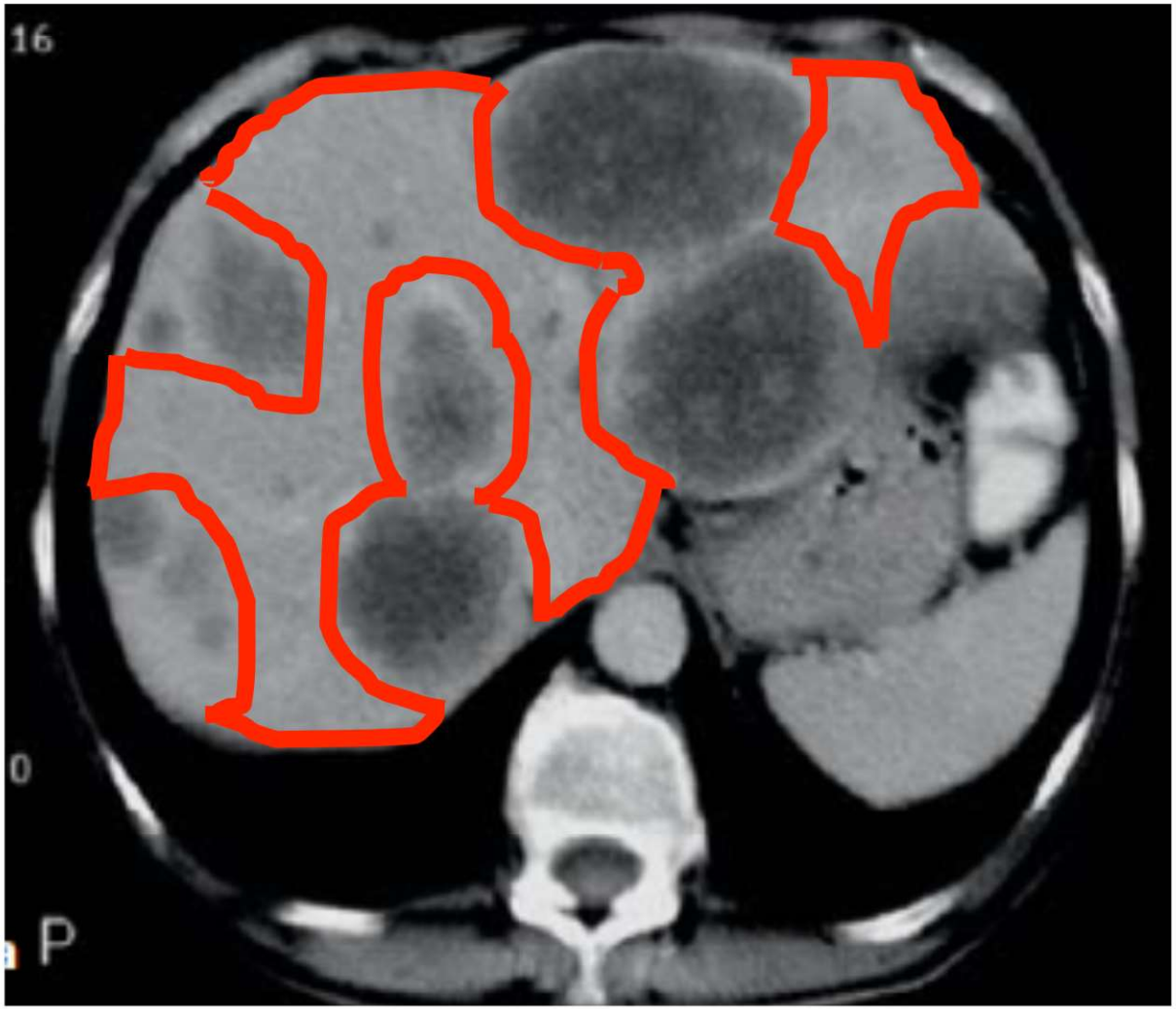

“Ver a vida pelo lado bom”

Abdalla EK, et al. Dig Surg 2008;25:421-9

METÁSTASES HEPÁTICAS: LIMITES PARA RESSECÇÃO

EMBOLIZAÇÃO DA VEIA PORTA
Makuuchi M, et al. Surgery 1990

HEPATECTOMIA EM DOIS TEMPOS
Adam R, et al. Ann Surg 2000

HEPATECTOMIA EM DOIS TEMPOS + EVP
Jaeck D, et al. Ann Surg 2004

HEPATECTOMIA EM DOIS TEMPOS + LVP
Belghiti J, et al. Hepatology 2008

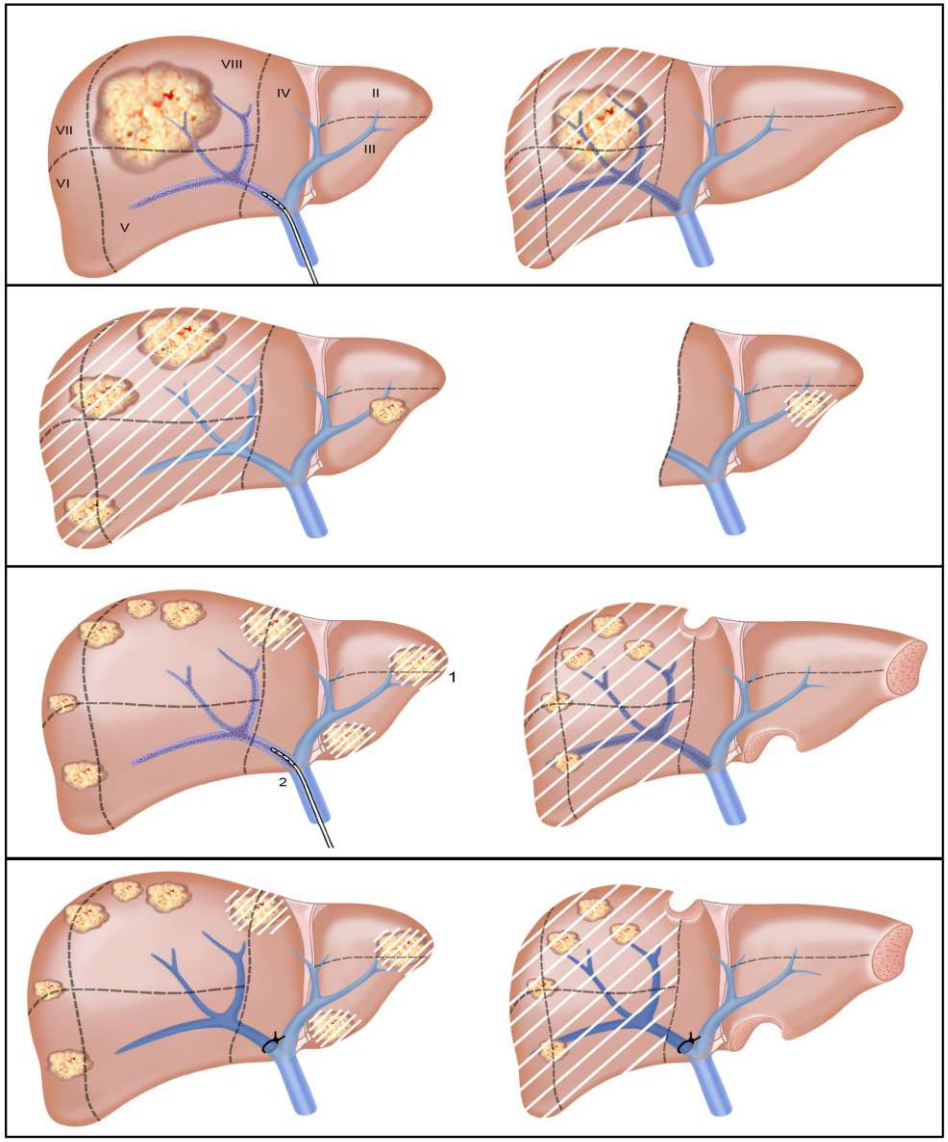

Hepatectomia em dois tempos

ANNALS OF SURGERY
Vol. 232, No. 6, 777–785

Two-Stage Hepatectomy: A Planned Strategy to Treat Irresectable Liver Tumors

René Adam, MD, PhD, Alexis Laurent, MD, Daniel Azoulay, MD, PhD, Denis Castaing, MD, and Henri Bismuth, MD, FACS (Hon)

From the Centre Hépato-Biliaire, Hôpital Paul Brousse, Villejuif, and Université Paris-Sud, France

Adam R, et al. Ann Surg 2000;232:777-85

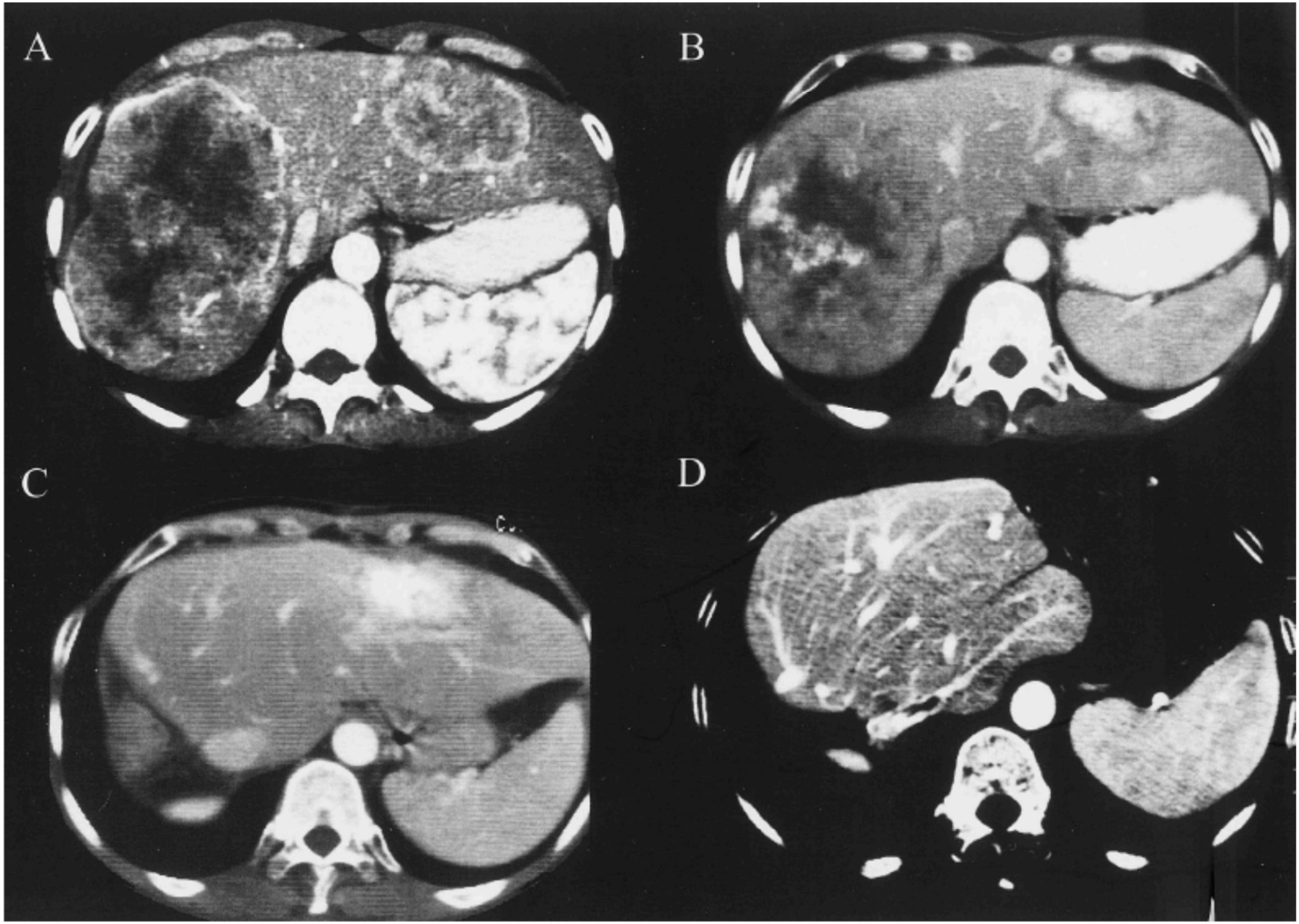

Adam R, et al. Ann Surg 2000;232:777-85

Margem de ressecção

ORIGINAL ARTICLE

One-Millimeter Cancer-Free Margin Is Curative for Colorectal Liver Metastases

A Propensity Score Case-Match Approach

Zaed Z. R. Hamady, PhD, FRCS,† J. Peter A. Lodge, MD, FRCS,† Fenella K. Welsh, FRCS,**
Giles J. Toogood, DM, FRCS,† Alan White, MRCS,† Timothy John, FRCS, and Myrddin Rees, FRCS**

Hamady ZZ, et al. Ann Surg 2014;259:543-8

Margem de ressecção

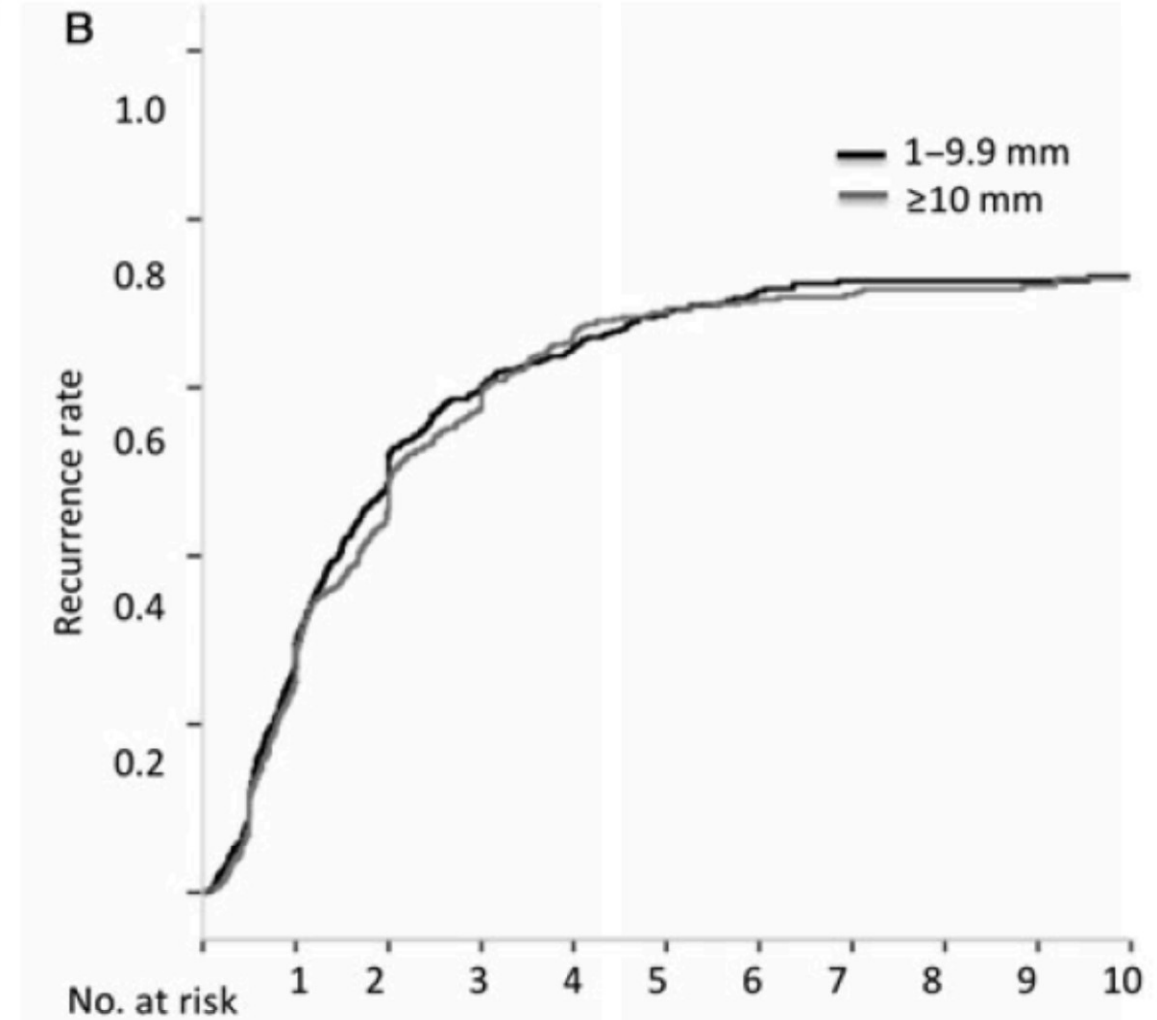

Hamady ZZ, et al. Ann Surg 2014;259:543-8

http://dx.doi.org/10.1016/j.hpb.2017.05.006 HPB

ORIGINAL ARTICLE

Twelve-year experience of "radical but conservative" liver surgery for colorectal metastases: impact on surgical practice and oncologic efficacy

Guido Torzilli, Luca Viganò, Andrea Gatti, Guido Costa, Matteo Cimino, Fabio Procopio, Matteo Donadon & Daniele Del Fabbro

Department of Surgery – Division of Hepatobiliary & General Surgery, Humanitas University, School of Medicine, Humanitas Clinical and Research Center – IRCCS, Rozzano, Milan, Italy

Torzilli G, et al. HPB 2017;259:543-8

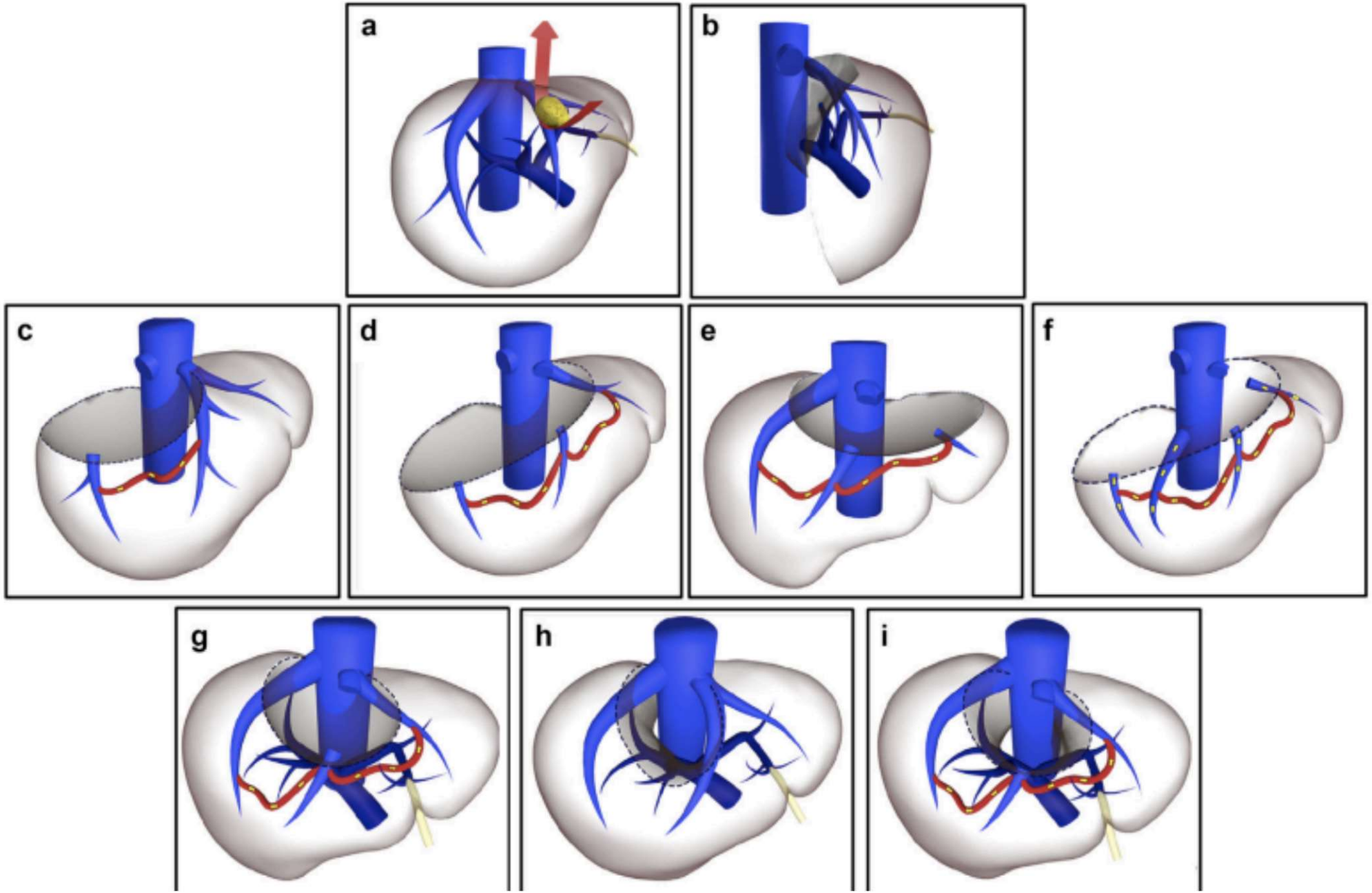

Torzilli G, et al. HPB 2017;259:543-8

Doença extra-hepática

- Pulmão
- Ovário
- Osso
- Linfonodo do pedículo
- Peritôneo

Adam R, et al. Surg Clin N Am 2004; 84:659-71

Ressecções vasculares

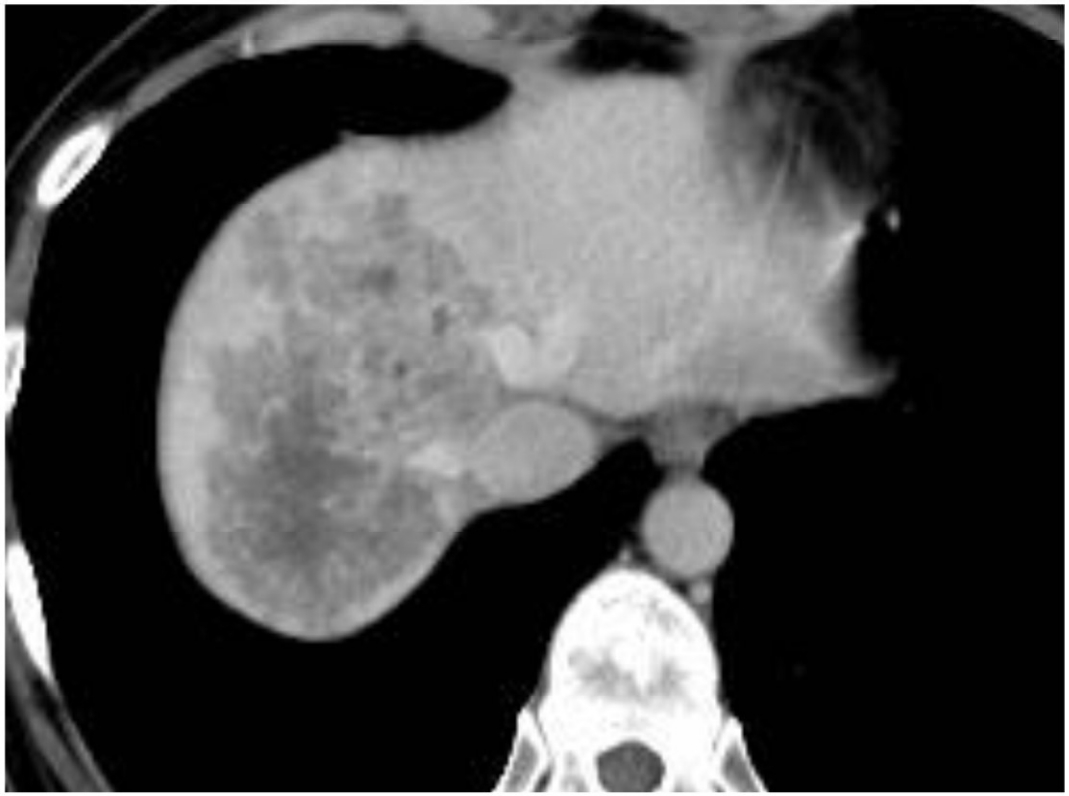

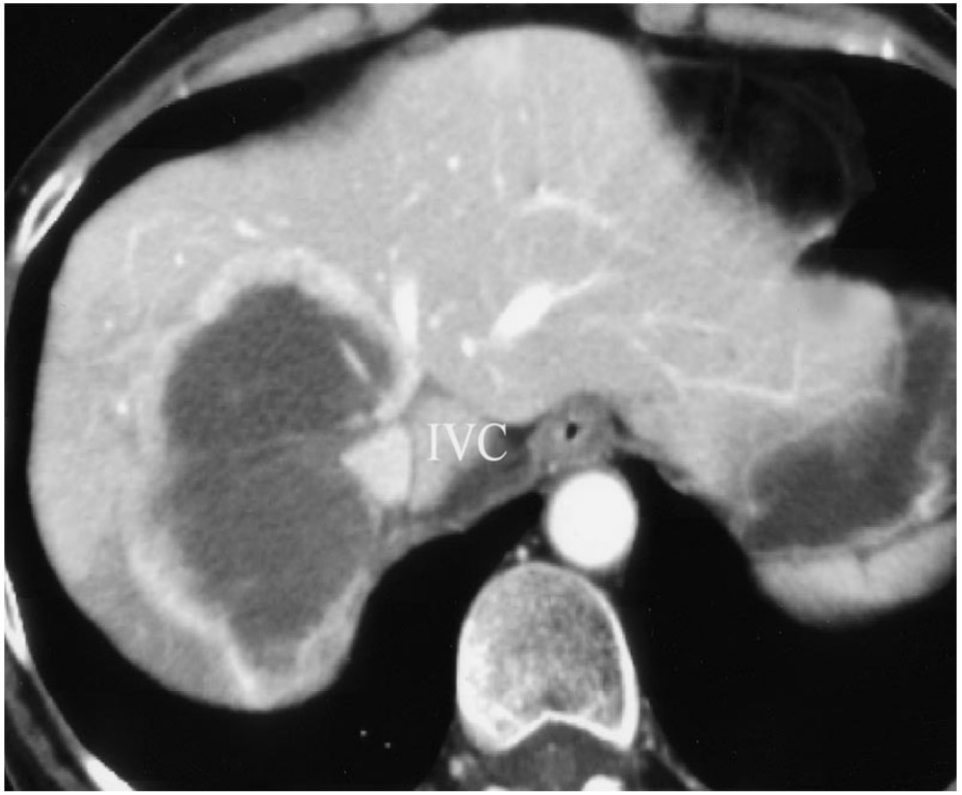

Cortesia: Dr. Eduardo de Santibanes

Ressecção de veia cava

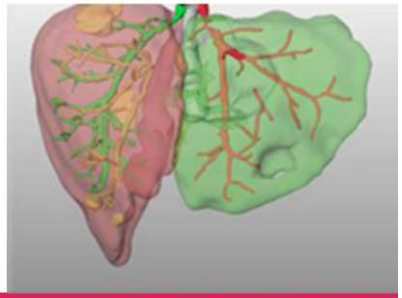

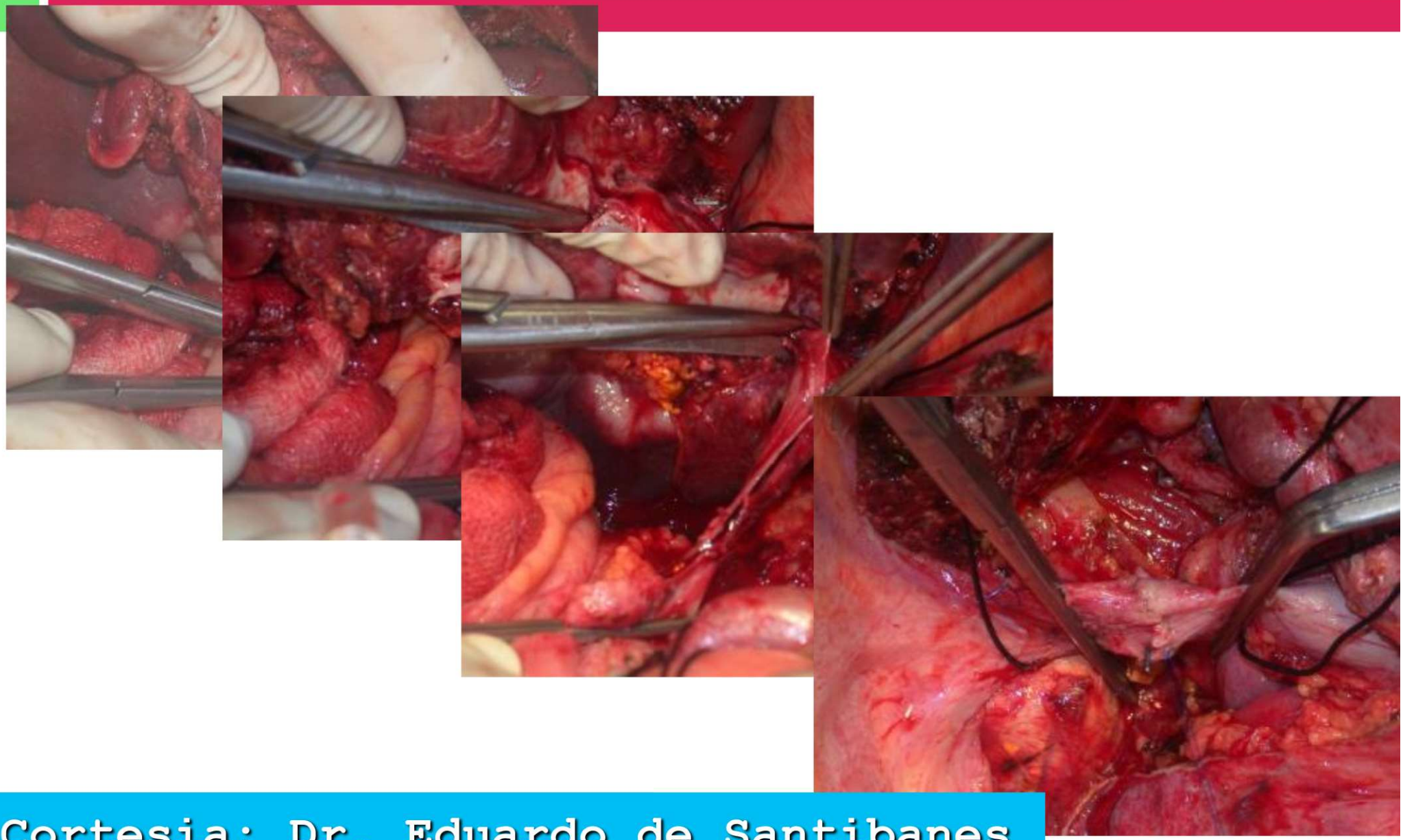

Cortesia: Dr. Eduardo de Santibanes

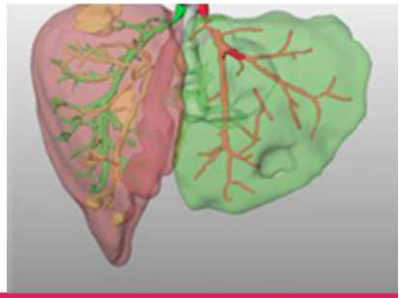

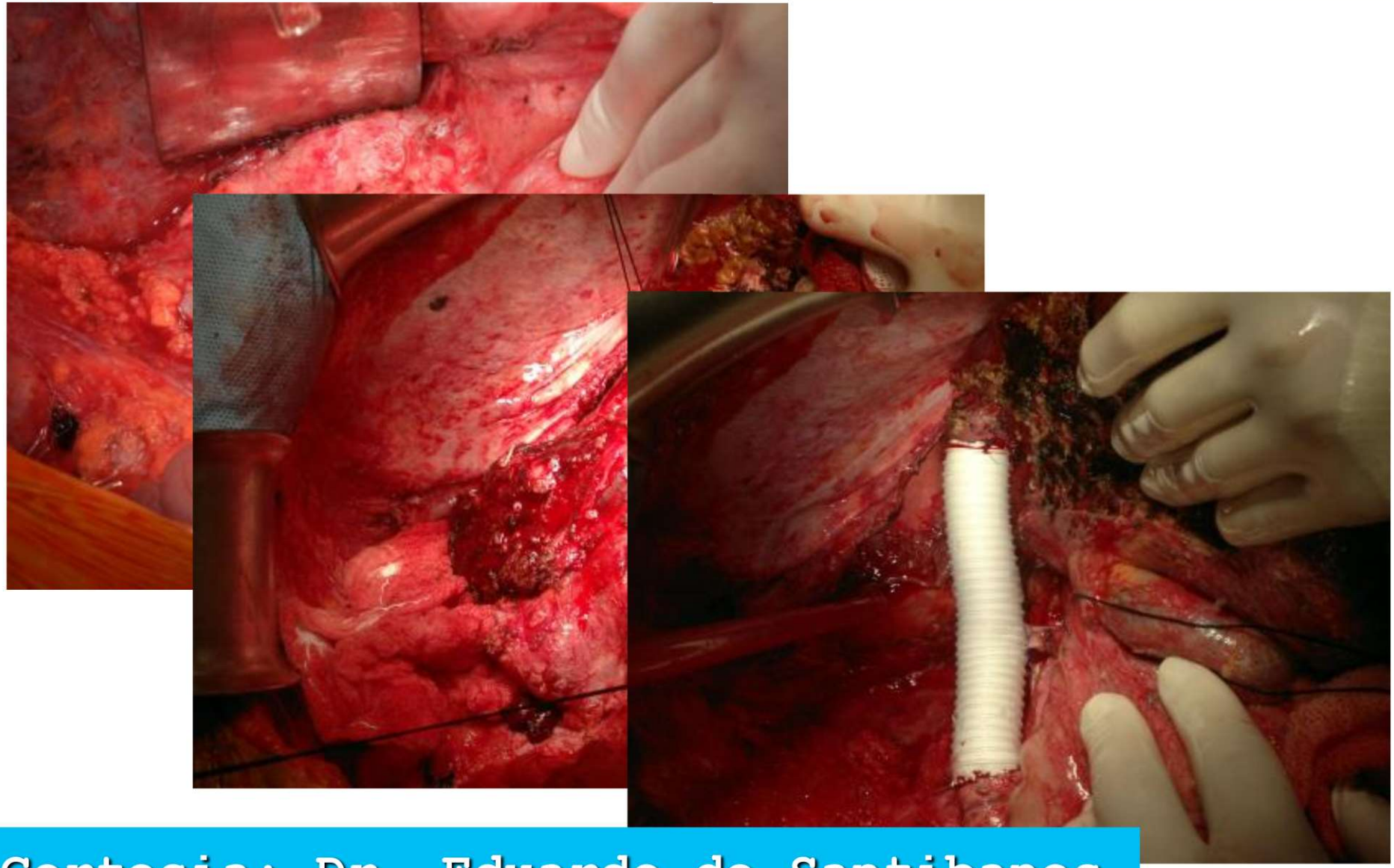

Cortesia: Dr. Eduardo de Santibanes

A Novel Concept for Partial Liver Transplantation in Nonresectable Colorectal Liver Metastases

The RAPID Concept

Pål-Dag Line, MD, PhD, Morten Hagness, MD, PhD,* Audun Elnaes Berstad, MD, PhD,† Aksel Foss, MD, PhD,*§ and Svein Dueland, MD, PhD‡*

Objective: Selected patients with nonresectable colorectal liver metastases

20% of the patients become surgically resectable. We have demon-

Transplante hepático

Line PD, et al. Ann Surg 2015;262:e5-e9

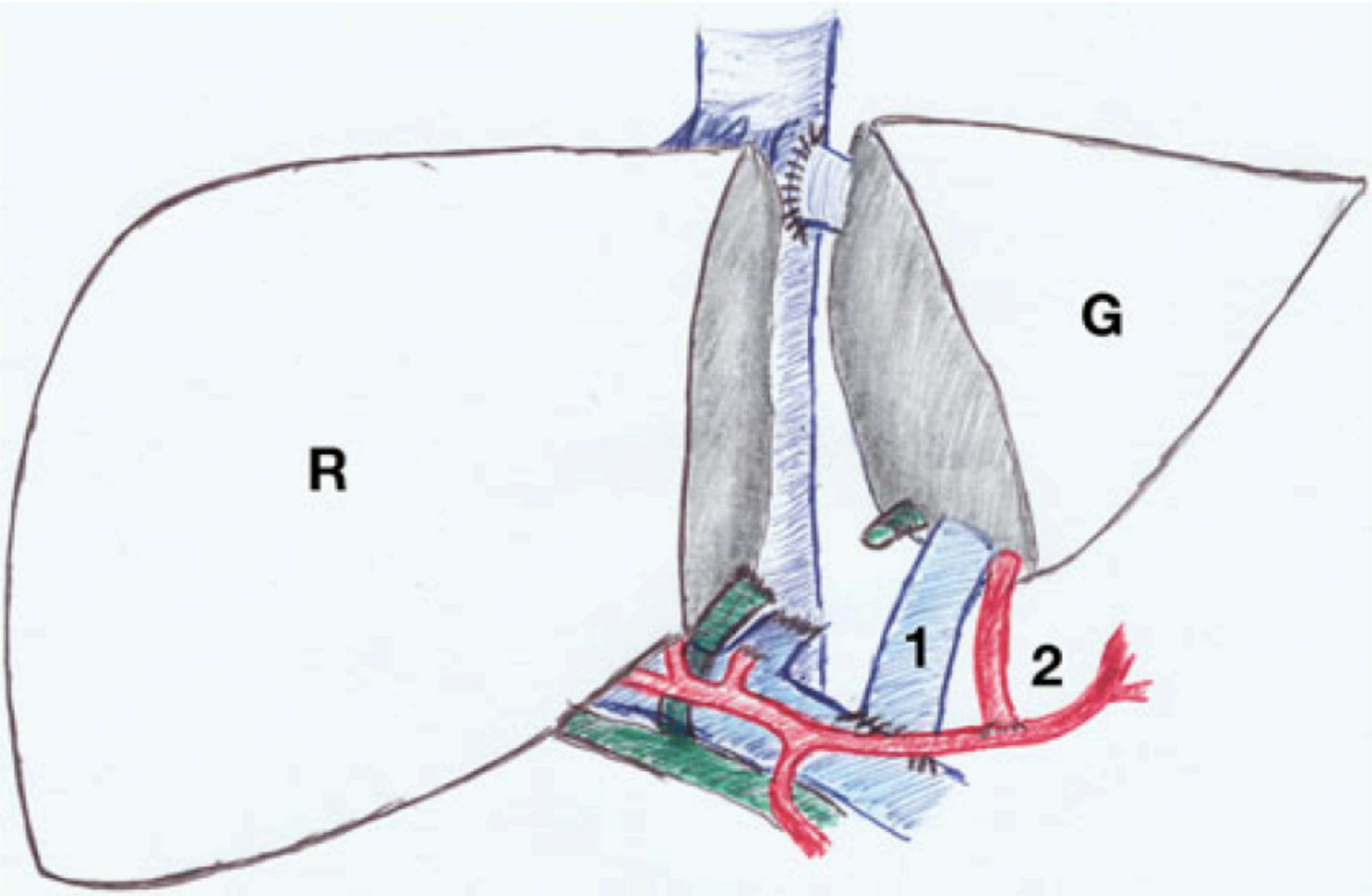

Line PD, et al. Ann Surg 2015;262:e5-e9

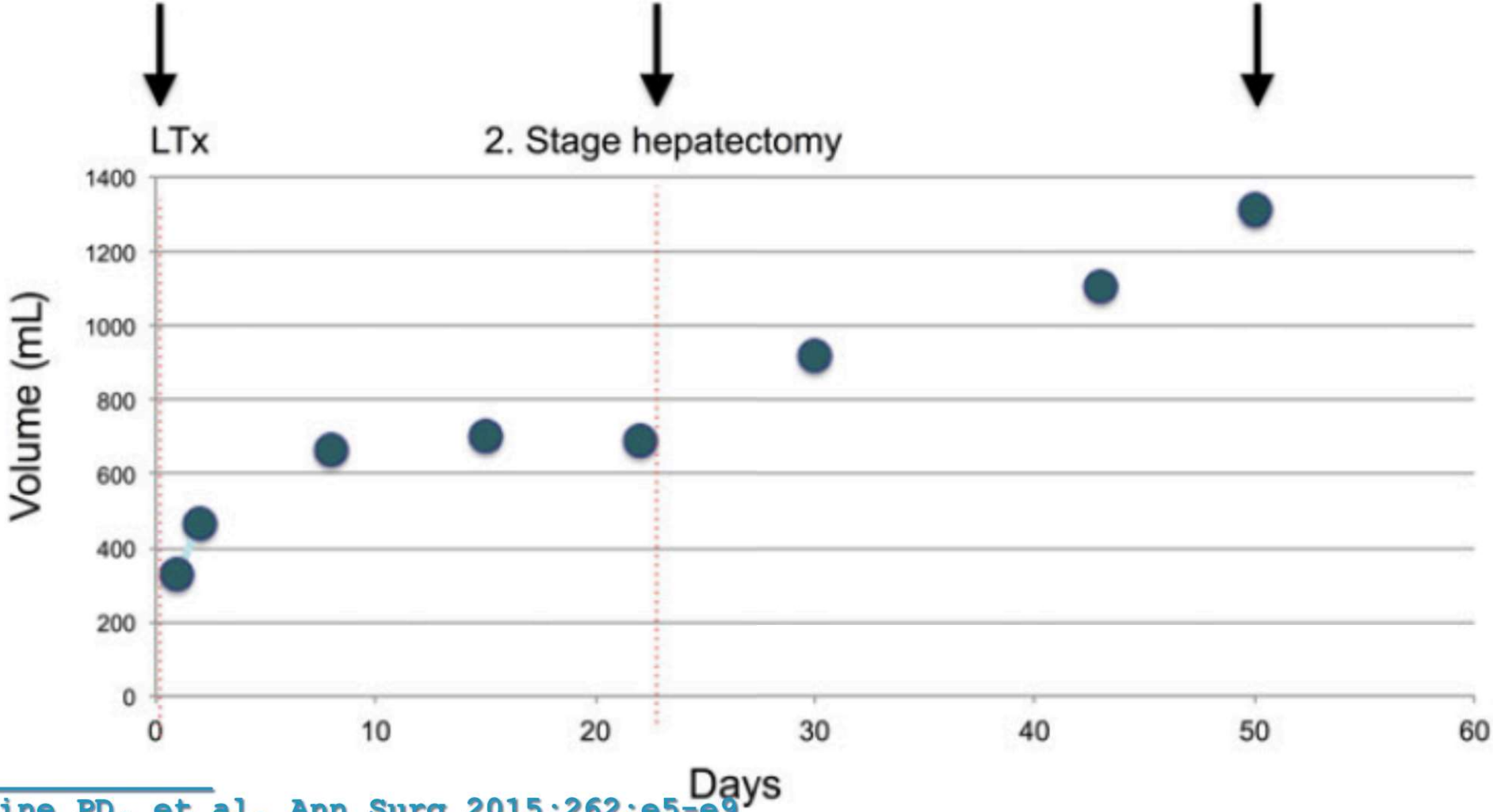

Line PD, et al. Ann Surg 2015;262:e5-e9

ALPPS

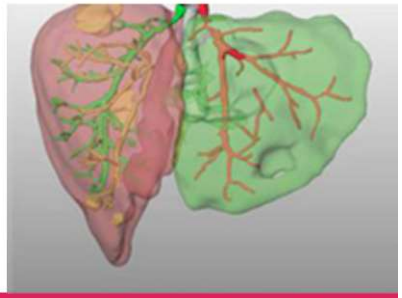

Cirurgia 1

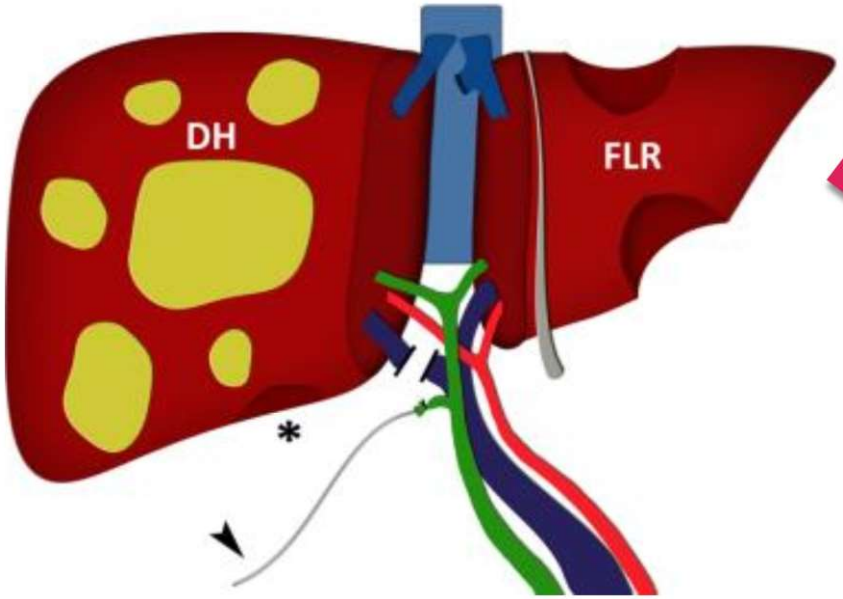

7-10 dias

Cirurgia 2

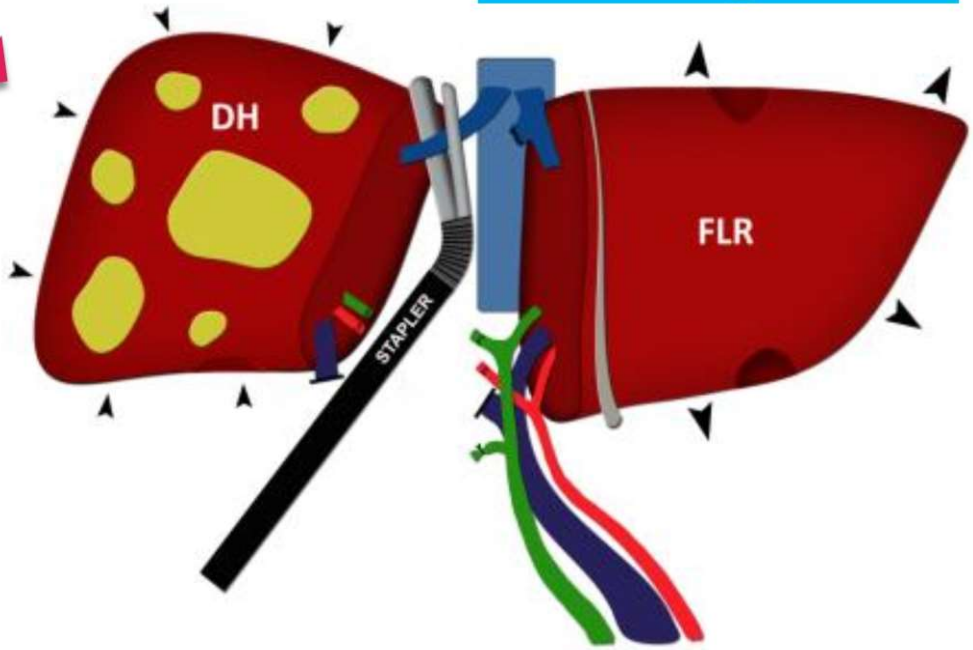

Alvarez FA, Ardiles V, de Santibañes E et al. J Gastrointest Surg. 2013

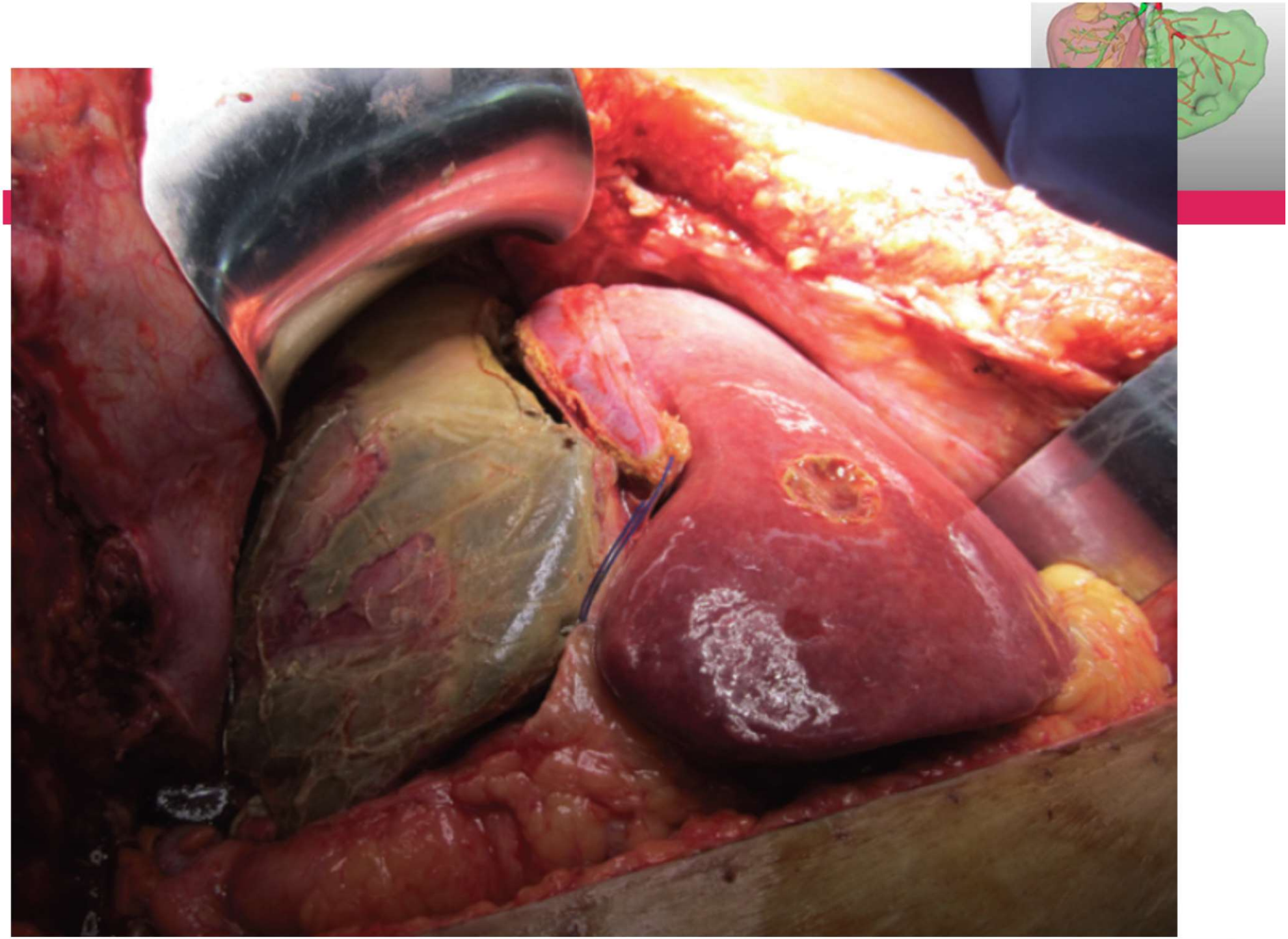

Cortesia Dr. Sanjay Govil – Bangalore (India)

FEATURE

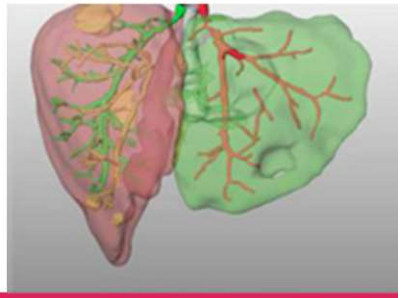

Right Portal Vein Ligation Combined With In Situ Splitting Induces Rapid Left Lateral Liver Lobe Hypertrophy Enabling 2-Staged Extended Right Hepatic Resection in Small-for-Size Settings

Andreas A. Schnitzbauer, MD, Sven A. Lang, MD,* Holger Goessmann, MD,† Silvio Nadalin, MD,§ Janine Baumgart, MD,|| Stefan A. Farkas, MD,* Stefan Fichtner-Feigl, MD,* Thomas Lorf, MD,¶ Armin Goralcyk, MD,¶ Rüdiger Hörbelt, MD,# Alexander Kroemer, MD,* Martin Loss, MD,* Petra Rümmele, MD,‡ Marcus N. Scherer, MD,* Winfried Padberg, MD,# Alfred Königsrainer, MD,§ Hauke Lang, MD,|| Aiman Obed, MD,¶ and Hans J. Schlitt, MD**

ABCDDV/898

ABCD Arq Bras Cir Dig
2013;26(1):40-43

Original Article

ASSOCIATING LIVER PARTITION AND PORTAL VEIN LIGATION FOR STAGED HEPATECTOMY (ALPPS): THE BRAZILIAN EXPERIENCE

Ligadura da veia porta associada à bipartição do fígado para hepatectomia em dois estágios (ALPPS): experiência Brasileira

Orlando Jorge Martins **TORRES**[1], Eduardo de Souza Martins **FERNANDES**[2] Cassio Virgilio Cavalcante **OLIV**
Cristiano Xavier **LIMA**[4], Fabio Luiz **WAECHTER**[5], Jose Maria Assunção **MORAES-JUNIOR**[1],
Marcelo Moura **LINHARES**[6], Rinaldo Danese **PINTO**[7], Paulo **HERMAN**[8], Marcel Autran Cesar **MACHAD**

12 e 12,8% Mortalidade

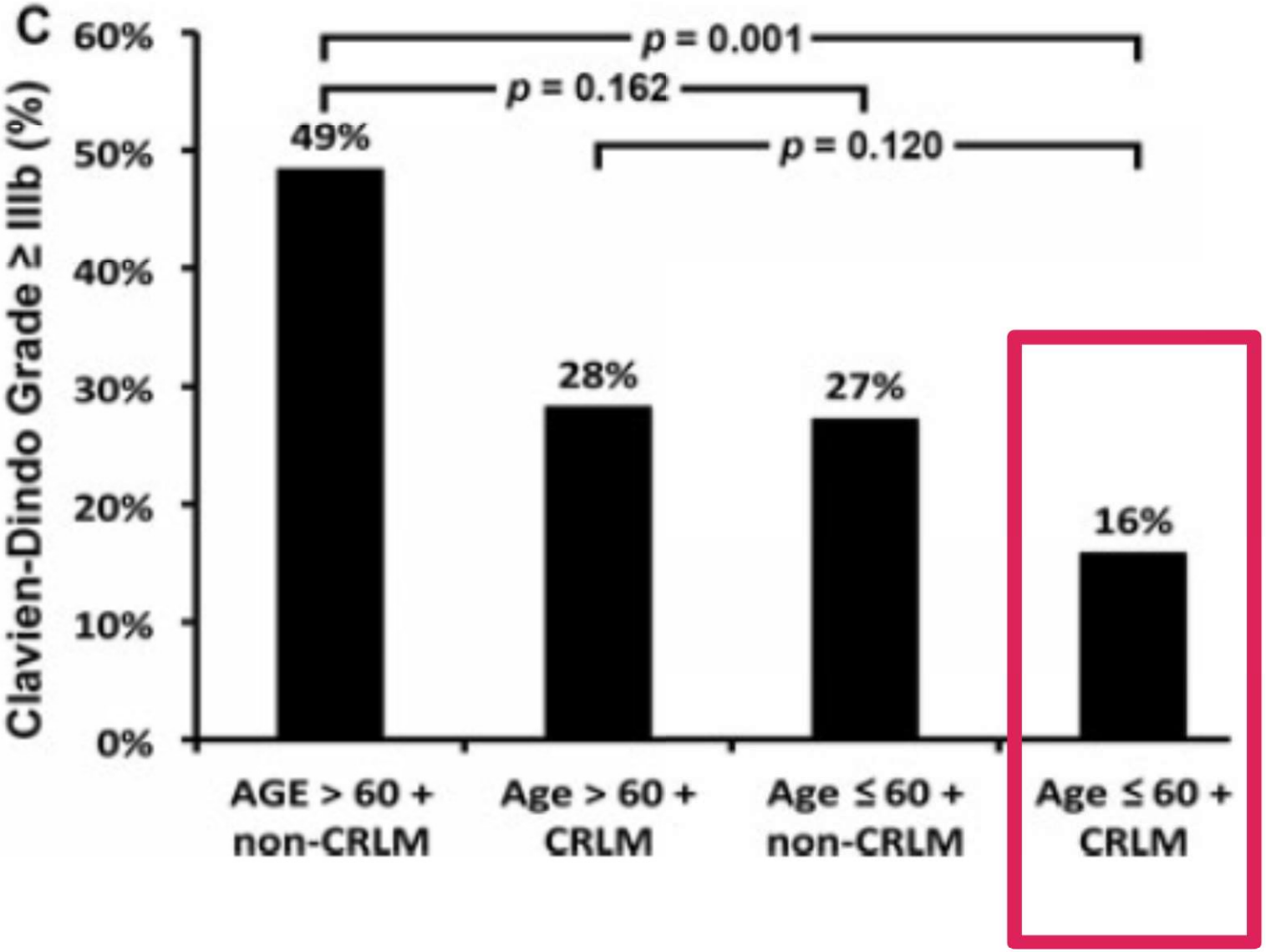

Schadde E, et al. Ann Surg 2014;260:829-38

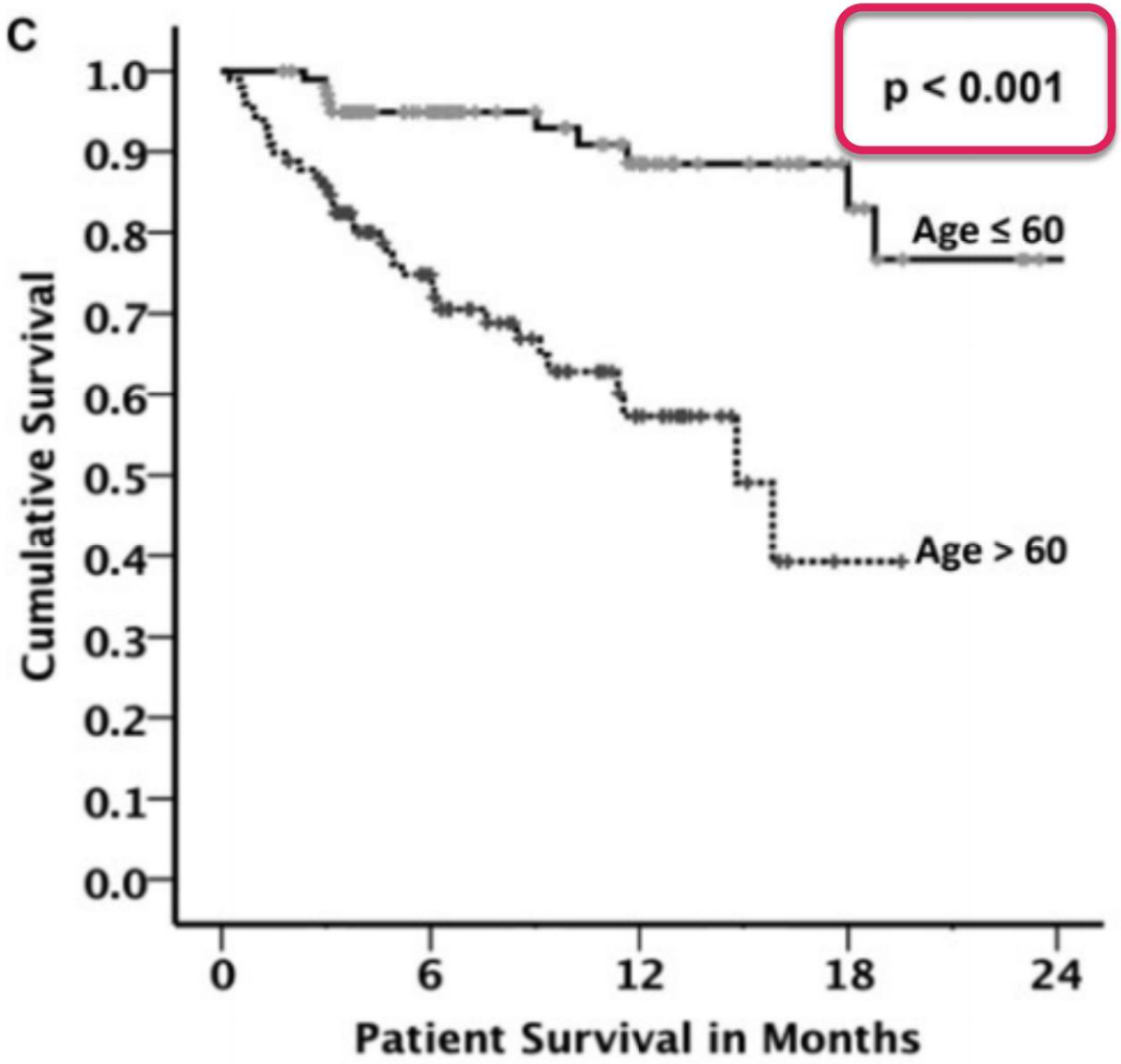

Numbers at risk				
Age ≤ 60 (n=101)	90	39	15	12
Age > 60 (n=98)	57	20	4	0

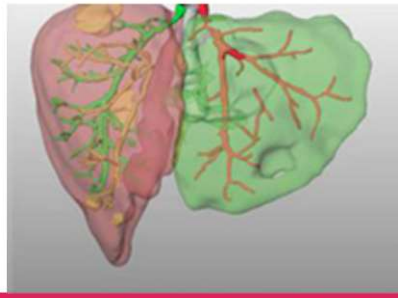

Schadde E, et al. Ann Surg 2014;260:829-38

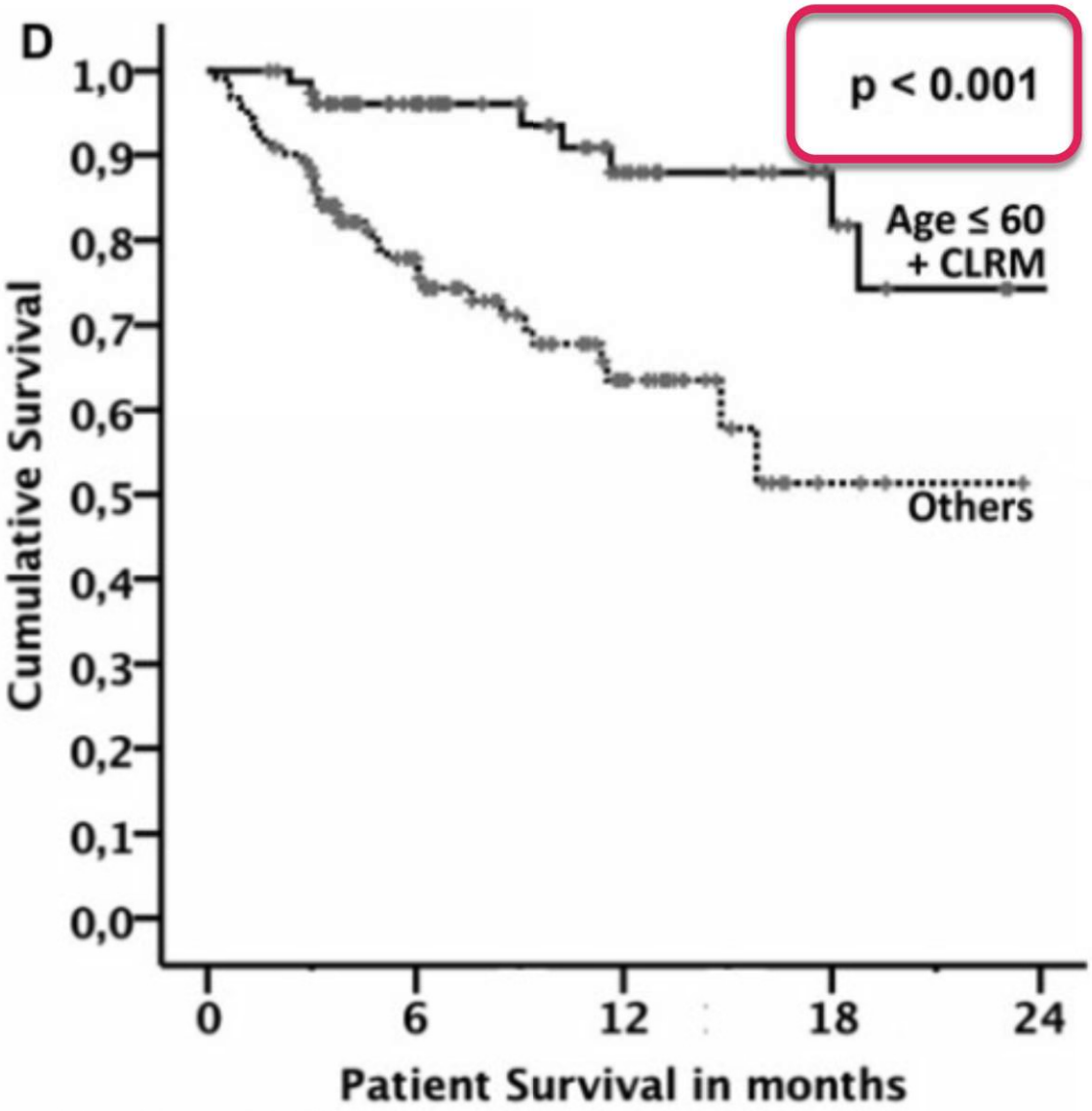

Numbers at risk				
Age≤60+CRLM (n=78)	71	30	13	10
Others (n=121)	72	29	8	0

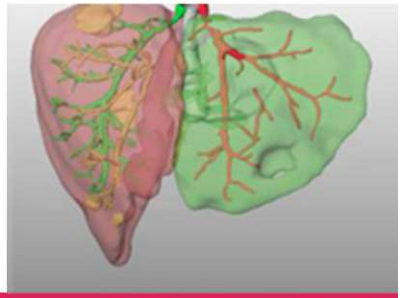

Schadde E, et al. Ann Surg 2014;260:829-38

ABCD Arq Bras Cir Dig
2016;29(3):173-179
DOI: /10.1590/0102-6720201600030011

Original Article

BRAZILIAN CONSENSUS FOR MULTIMODAL TREATMENT OF COLORECTAL LIVER METASTASES. MODULE 3: CONTROVERSIES AND UNRESECTABLE METASTASES

Consenso brasileiro de tratamento multidisciplinar de metástase hepática de origem colorretal
Módulo 3: Controvérsias e metástases irressecáveis

Orlando Jorge Martins **TORRES**[1,2,6], Márcio Carmona **MARQUES**[2,6], Fabio Nasser **SANTOS**[1], Igor Correia de **FARIAS**[2,6], Anelisa Kruschewsky **COUTINHO**[3], Cássio Virgílio Cavalcante de **OLIVEIRA**[1,4,5], Antonio Nocchi **KALIL**[1,2,4,6], Celso Abdon Lopes de **MELLO**[3], Jaime Arthur Pirola **KRUGER**[1,4,5,6], Gustavo dos Santos **FERNANDES**[3], Claudemiro **QUIREZE JR**[1,4,5,6], André M. **MURAD**[3], Milton José de **BARROS E SILVA**[3], Charles Edouard **ZURSTRASSEN**[*], Helano Carioca **FREITAS**[3], Marcelo Rocha **CRUZ**[3], Rui **WESCHENFELDER**[3], Marcelo Moura **LINHARES**[1,4,5,6], Leonaldson dos Santos **CASTRO**[1,2,6], Charles **VOLLMER**[6], Elijah **DIXON**[6], Héber Salvador de Castro **RIBEIRO**[1,2,6], Felipe José Fernandez **COIMBRA**[1,2,5,6]

ALPPS

- Alternative for two-stage hepatectomy
- Rescue surgery – after PVE

Torres OJ, et al. Arq Bras Cir Dig 2016;29 (3):173-9

ABCDDV/1112

ABCD Arq Bras Cir Dig
2015;28(3):155-156
DOI: /10.1590/S0102-67202015000300001

Editorial

ALPPS: PAST, PRESENT AND FUTURE

ALPPS: passado, presente e futuro

Orlando Jorge M **TORRES**[1], Eduardo S M **FERNANDES**[2], Paulo **HERMAN**[3]

[1]Universidade Federal do Maranhão (Federal University of Maranhão), São Luís, MA; [2] Hospital Adventista Silvestre, Rio de Janeiro, RJ, Brazil; [3]Universidade de São Paulo (University of São Paulo), São Paulo, SP, Brazil.

Complete tumor resection in the liver is the only chance to obtain long-term survival in patients with hepatic tumor or metastasis from other primary cancers. In patients with a large load of tumor within the liver, multiple strategies have been employed to improve resection, especially when a small liver remnant is expected. Staged hepatectomies, in

- Discutir em reunião multidisciplinar
- Remanescente < 30%
- Resgate após falha na embolização de veia porta
- Evitar em colangiocarcinoma
- Reduzir morbidade e mortalidade

Torres OJ, et al. Arq Bras Cir Dig 2015;28:155-6

International Journal of Surgery Case Reports 26 (2016) 113–117

Contents lists available at ScienceDirect

International Journal of Surgery Case Reports

journal homepage: www.casereports.com

The ALPPS procedure for hepatocellular carcinoma larger than 10 centimeters

Orlando Jorge M. Torres*, Rodrigo Rodrigues Vasques, Thiago Henrique S. Silva, Miguel Eugenio L. Castelo-Branco, Camila Cristina S. Torres

Department of Digestive Surgery, Federal University of Maranhão, São Luiz, MA, Brazil

ARTICLE INFO

Article history:
Received 10 June 2016

ABSTRACT

INTRODUCTION: The only means of achieving long-term survival in hepatocellular carcinoma is complete tumor resection or liver transplantation. Patients with large hepatocellular carcinomas are currently

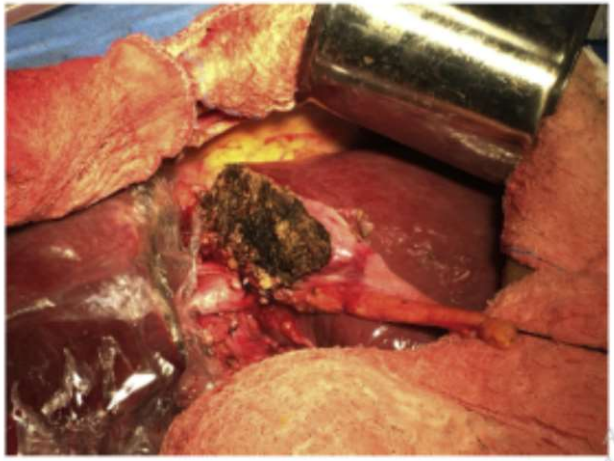

Fig. 2. ALPPS first procedure with plastic bag.

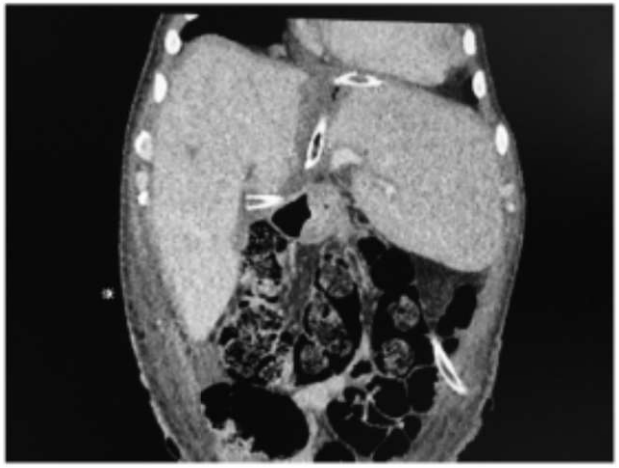

Fig. 3. CT 15 days after the first procedure.

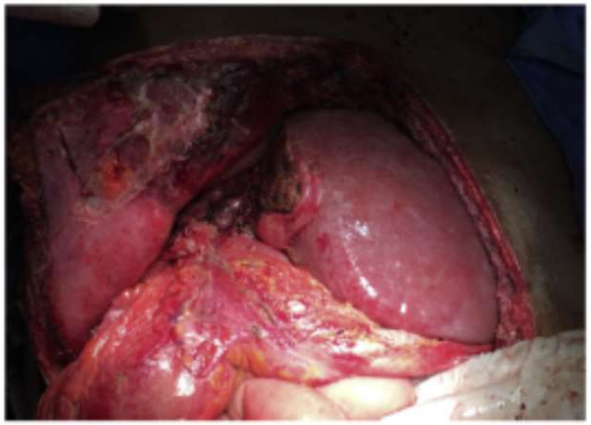

Fig. 4. Final aspect of the liver remnant.

Torres OJ, et al. Int J Surg Case Rep 2016;26:113-7

The ALPPS Risk Score

Avoiding Futile Use of ALPPS

Michael Linecker, MD, Gregor A. Stavrou, MD,†‡ Karl J. Oldhafer, MD,†‡ Robert M. Jenner, MD,†
Burkhardt Seifert, PhD,§ Georg Lurje, MD,¶ Jan Bednarsch, MD,¶ Ulf Neumann, MD,¶
Ivan Capobianco, MD,|| Silvio Nadalin, MD,|| Ricardo Robles-Campos, MD,**
Eduardo de Santibañes, MD, PhD, FACS,†† Massimo Malagó, MD,‡‡ Mickael Lesurtel, MD, PhD,*
Pierre-Alain Clavien, MD, PhD, FACS,* and Henrik Petrowsky, MD, FACS**

Objectives: To create a prediction model identifying futile outcome in

Conclusions: Both models have an excellent prediction to assess the individual risk of futile outcome after ALPPS surgery and can be used to avoid

Linecker M, et al. Ann Surg 2016;264:763-71

TABLE 3. Risk Modeling

	Risk Points	Regression Coefficient	Odds Ratio (95% CI)	*P*
Pre-stage 1 variables*				
Tumor type†				
CRLM (reference)	0	0.000	1.000	
Non-CRLM/nonbiliary	1	0.655	1.925 (0.808–4.585)	0.139
Biliary	2	1.326	3.767 (1.800–7.882)	<0.001
Age ≥67 yr	3	1.735	5.668 (2.843–11.30)	<0.001
Intercept pre-stage 1		−5.3		
Pre-stage 2 variables‡				
Pre-stage 1 score, per point	0.66	0.665	1.925 (1.527–2.426)	<0.001
Interstage complications ≥3b	1.2	1.209	3.350 (1.280–8.769)	0.014
Pre-stage 2 bilirubin§	1.5	1.496	4.439 (1.699–11.60)	0.002
Pre-stage 2 creatinine‖	1.7	1.696	5.454 (1.606–18.52)	0.007
Intercept pre-stage 2		−6.8		

- Pre-stage I — Ponto
  - Não coloretal/biliar — 1
  - Biliary surgery (Cholangiocarcinoma) — 2
  - Age ≥ 67 yr — 3
- Pre-stage II
  - Complications ≥ 3b
  - Bilirubin
  - Creatinine

Linecker M, et al. Ann Surg 2016;264:763-71

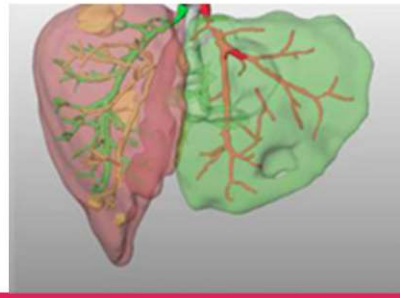

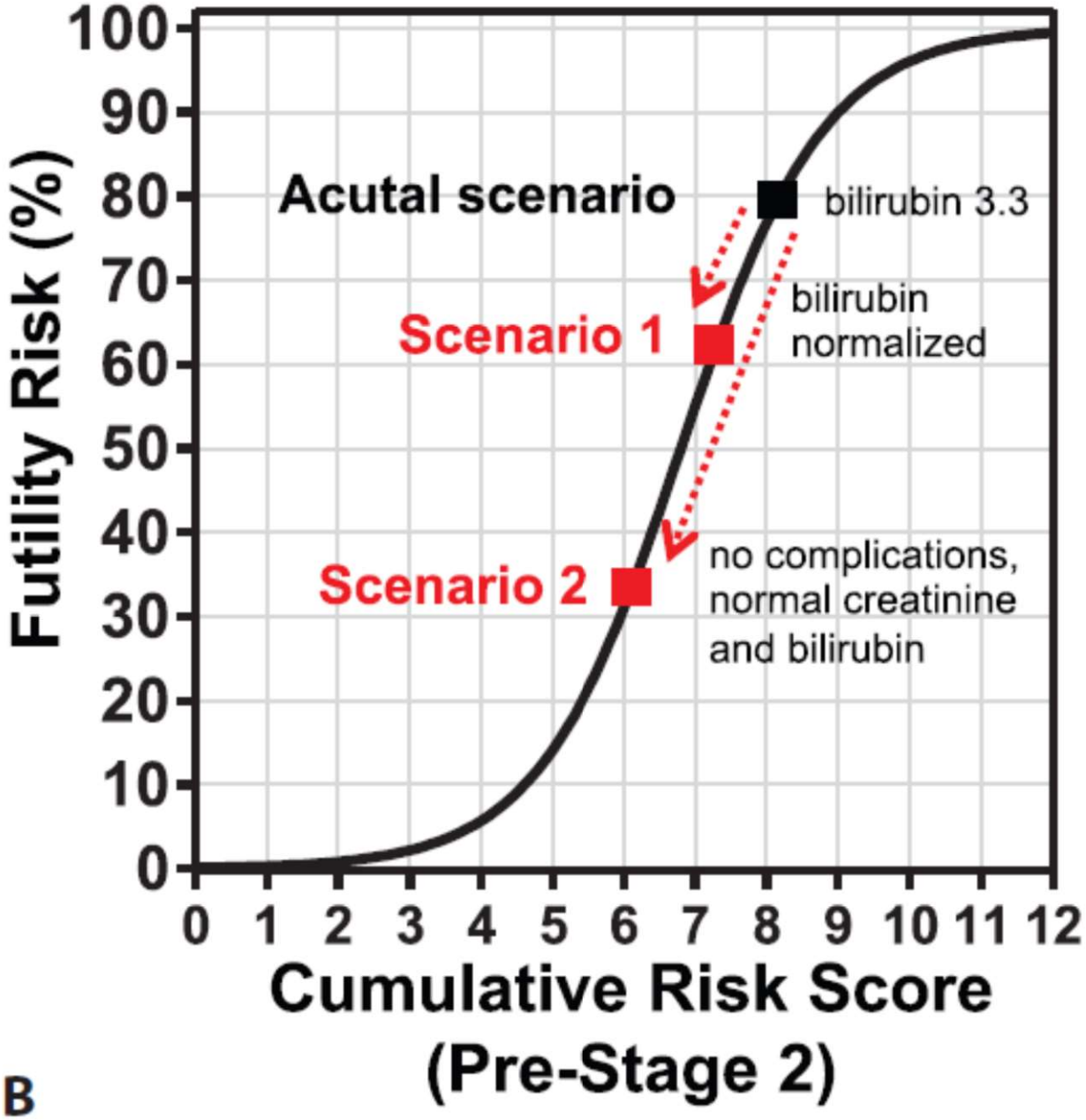

Linecker M, et al. Ann Surg 2016;264:763-71

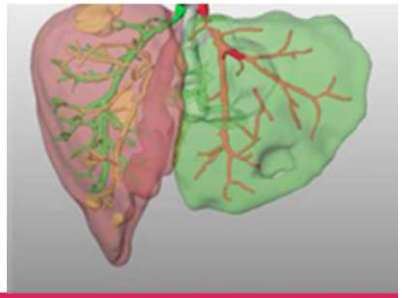

Risk	Score
5%	3.9
10%	4.7
20%	5.5
50%	6.9

Linecker M, et al. Ann Surg 2016;264:763-71

12th Biennial E-AHPBA Congress 2017
European-African Hepato Pancreato Biliary Association
23 May – 26 May, 2017

Liver surgery: Clinical
FP26.08

Performance Validation of the ALPPS Risk Model

M. Linecker[1], P. Kambakamba[1], A. Schlegel[2], P. Muiesan[2], I. Capobianco[3], S. Nadalin[3], O. Torres[4], A. Mehrabi[5], G.A. Stavrou[6, 7], K.J. Oldhafer[6, 7], G. Lurje[8], U. Neumann[8], R. Robles-Campos[9], R. Hernandez-Alejandro[10, 11], M. Malago[12], E. De Santibanes[13], P.-A. Clavien[1], H. Petrowsky[1]
[1]University Hospital Zurich, Department of Surgery and Transplantation, Zurich, Switzerland, [2]University Hospitals Birmingham NHS Foundation Trust, Liver Unit, Queen Elizabeth Hospital Birmingham, Birmingham, United Kingdom, [3]University Hospital Tübingen, Department for General, Visceral and Transplant Surgery, Tübingen, Germany, [4]Universidade Federal do Maranhão, Department of Surgery, Sao Luis-MA, Brazil, [5]University of Heidelberg, Department of General, Visceral, and Transplantation Surgery, Heidelberg, Germany, [6]Asklepios Hospital Barmbek, Department of General and Abdominal Surgery, Hamburg, Germany, [7]Semmelweis University Budapest, Campus Hamburg, Germany, [8]University Hospital Aachen, RWTH Aachen, Department of General, Visceral and Transplantation Surgery, Aachen, Germany, [9]Virgen de la Arrixaca Clinic and University Hospital, Department of Surgery and Liver and Pancreas Transplantation, Murci, Spain, [10]London Health Sciences Centre, Department of Surgery, Division of HPB Surgery and Liver Transplantation, London, Ontario, Canada, [11]University of Rochester, Division of Transplantation, Hepatobiliary Surgery, Rochester, United States, [12]University College London, Royal Free Hospitals, Department of HPB- and Liver Transplantation Surgery, London, United Kingdom, [13]Italian Hospital Buenos Aires, Department of Surgery, Division of HPB Surgery, Liver Transplant Unit, Buenos Aires, Argentina

- Autores de 8 países (1 Brasileiro)
- Estratégia para tornar o procedimento mais seguro

Linecker M, et al. E-AHPBA 2017

ABCDDV/898

ABCD Arq Bras Cir Dig
2013;26(1):40-43

Original Article

ASSOCIATING LIVER PARTITION AND PORTAL VEIN LIGATION FOR STAGED HEPATECTOMY (ALPPS): THE BRAZILIAN EXPERIENCE

Ligadura da veia porta associada à bipartição do fígado para hepatectomia em dois estágios (ALPPS): experiência Brasileira

Orlando Jorge Martins **TORRES**[1], Eduardo de Souza Martins **FERNANDES**[2] Cassio Virgilio Cavalcante **OLIVEIRA**[3], Cristiano Xavier **LIMA**[4], Fabio Luiz **WAECHTER**[5], Jose Maria Assunção **MORAES-JUNIOR**[1], Marcelo Moura **LINHARES**[6], Rinaldo Danese **PINTO**[7], Paulo **HERMAN**[8], Marcel Autran Cesar **MACHADO**[9]

- 83 yr
- Sarcoma
- Additional surgery:
  - Colectomy
  - Pancreatoduodenectomy

- 12.8 % Mortality

Torres OJ, et al. Arq Bras Cir Dig 2013;26:40-3

ABCD Arq Bras Cir Dig
2013;26(1):40-43

Original Article

ASSOCIATING LIVER PARTITION AND PORTAL VEIN LIGATION FOR STAGED HEPATECTOMY (ALPPS): THE BRAZILIAN EXPERIENCE

Ligadura da veia porta associada à bipartição do fígado para hepatectomia em dois estágios (ALPPS): experiência Brasileira

Orlando Jorge Martins **TORRES**[1], Eduardo de Souza Martins **FERNANDES**[2] Cassio Virgilio Cavalcante **OLIVEIRA**[3], Cristiano Xavier **LIMA**[4], Fabio Luiz **WAECHTER**[5], Jose Maria Assunção **MORAES-JUNIOR**[1], Marcelo Moura **LINHARES**[6], Rinaldo Danese **PINTO**[7], Paulo **HERMAN**[8], Marcel Autran Cesar **MACHADO**[9]

TABLE 1 - Complications after ALPPS approach

Complications	n	%
Surgical site infection	8	20.5
Ascites	5	12.8
Biliary fistula	4	10.2
Pneumonia	4	10.2
Abdominal hernia	4	10.2
Sepsis	3	7.7
Acute renal failure	2	5.1
Bile duct injury	1	2.5
Hepatic artery thrombosis	1	2.5
Acute liver failure	1	2.5
Others	9	23.0

- High risk score
- 4 patients

- 35 pacientes
- 1 óbito
- Mortal 2,86%

Torres OJ, et al. Arq Bras Cir Dig 2013;26:40-3

Obrigado !

Lençóis Maranhenses