



I CONGRESSO REGIONAL DE CIRURGIA **DELTA DO PARNAÍBA** 2025

INOVAÇÃO, TECNOLOGIA
E HUMANIZAÇÃO DA CIRURGIA

05 E 06 DE JUNHO | LUIS CORREIA - SESC PRAIA

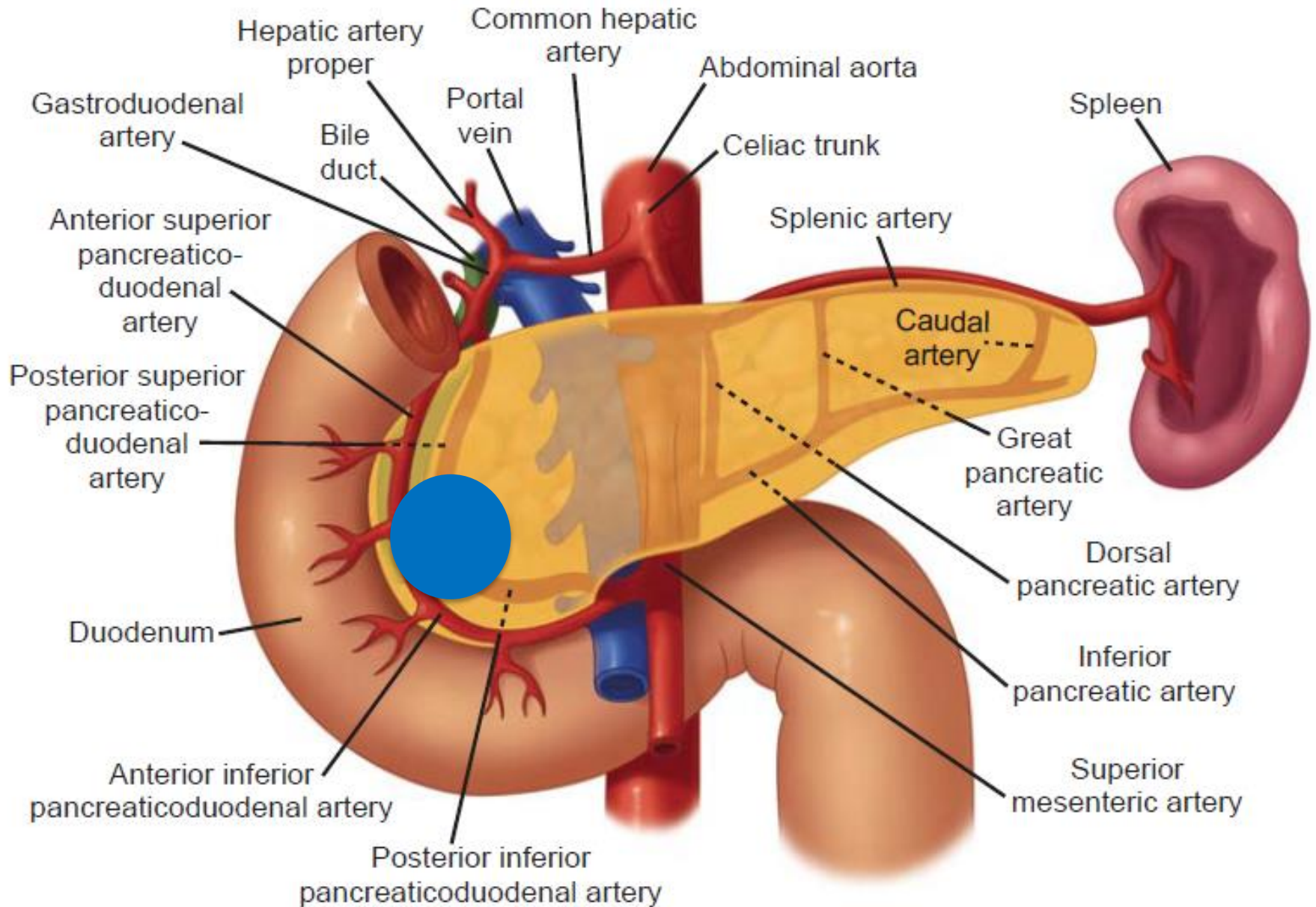


DUODENOPANCREATECTOMIA: PADRONIZAÇÃO TÉCNICA

Orlando Jorge M. Torres

Department of Gastrointestinal Surgery
Hepatopancreatobiliary Unit
Universidade Federal do Maranhão - Brazil

ANATOMY



DUODENOPANCREATECTOMIA

- SANGRAMENTO
- FÍSTULA PANCREÁTICA
- GASTROPARESIA
- PADRÃO ONCOLÓGICO

ARTERY FIRST

Abordagem da artéria mesentérica superior

SUPERIOR
(Makino et al, 2008)

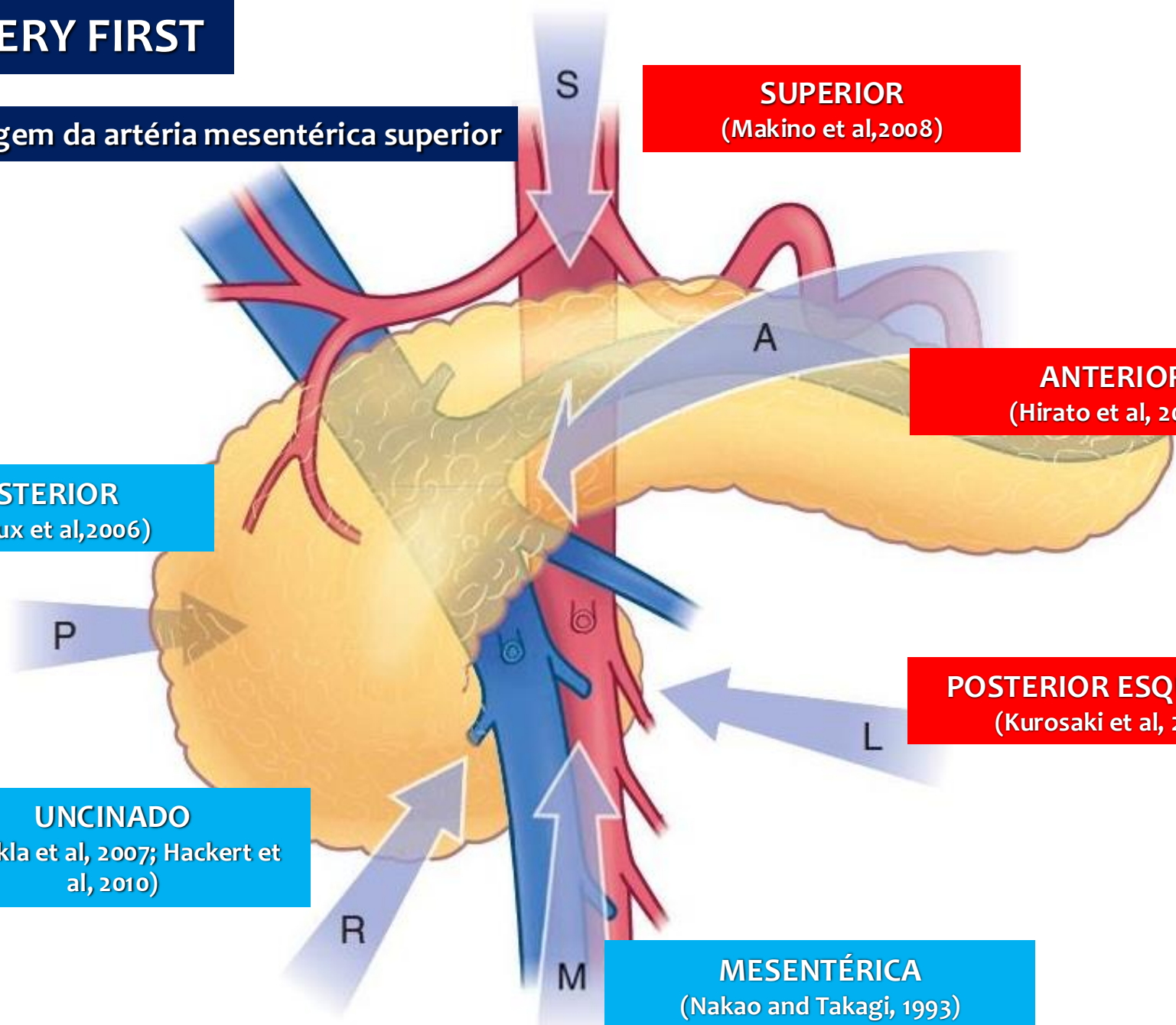
ANTERIOR
(Hirato et al, 2010)

POSTERIOR
(Pessaux et al, 2006)

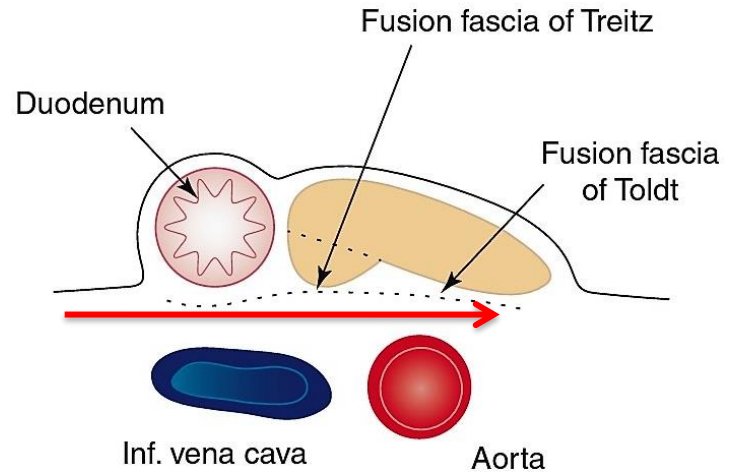
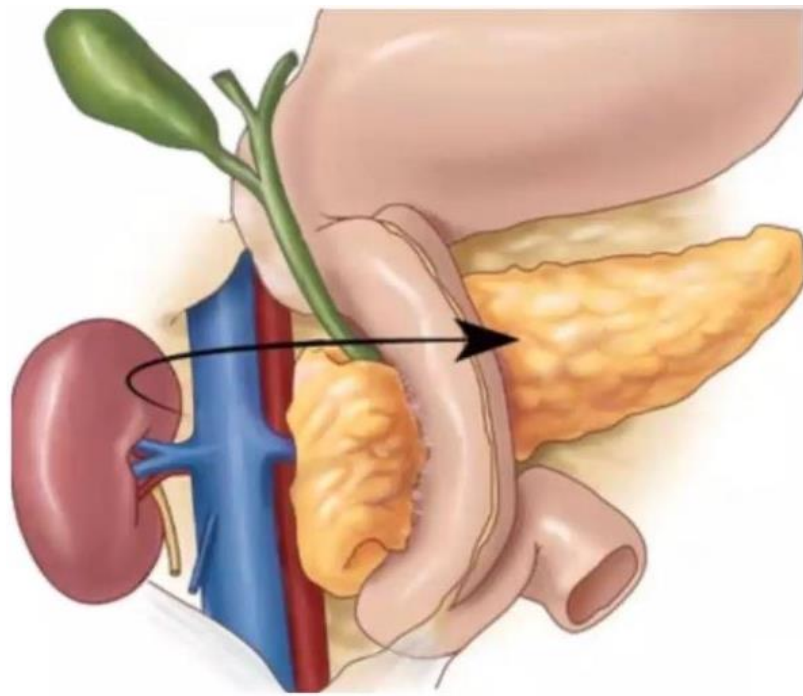
POSTERIOR ESQUERDA
(Kurosaki et al, 2011)

UNCINADO
(Shukla et al, 2007; Hackert et al, 2010)

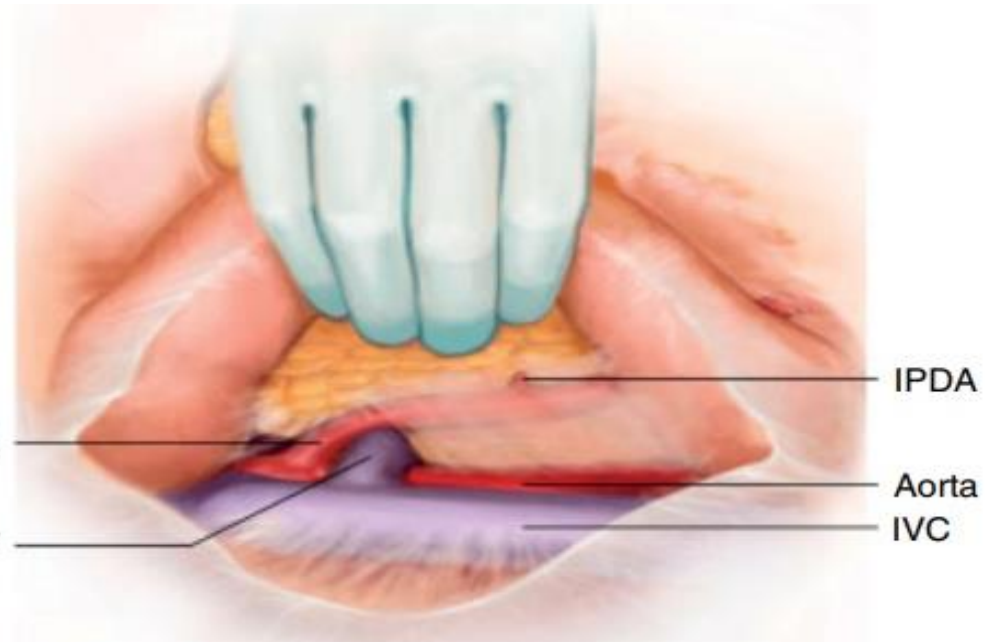
MESENTÉRICA
(Nakao and Takagi, 1993)

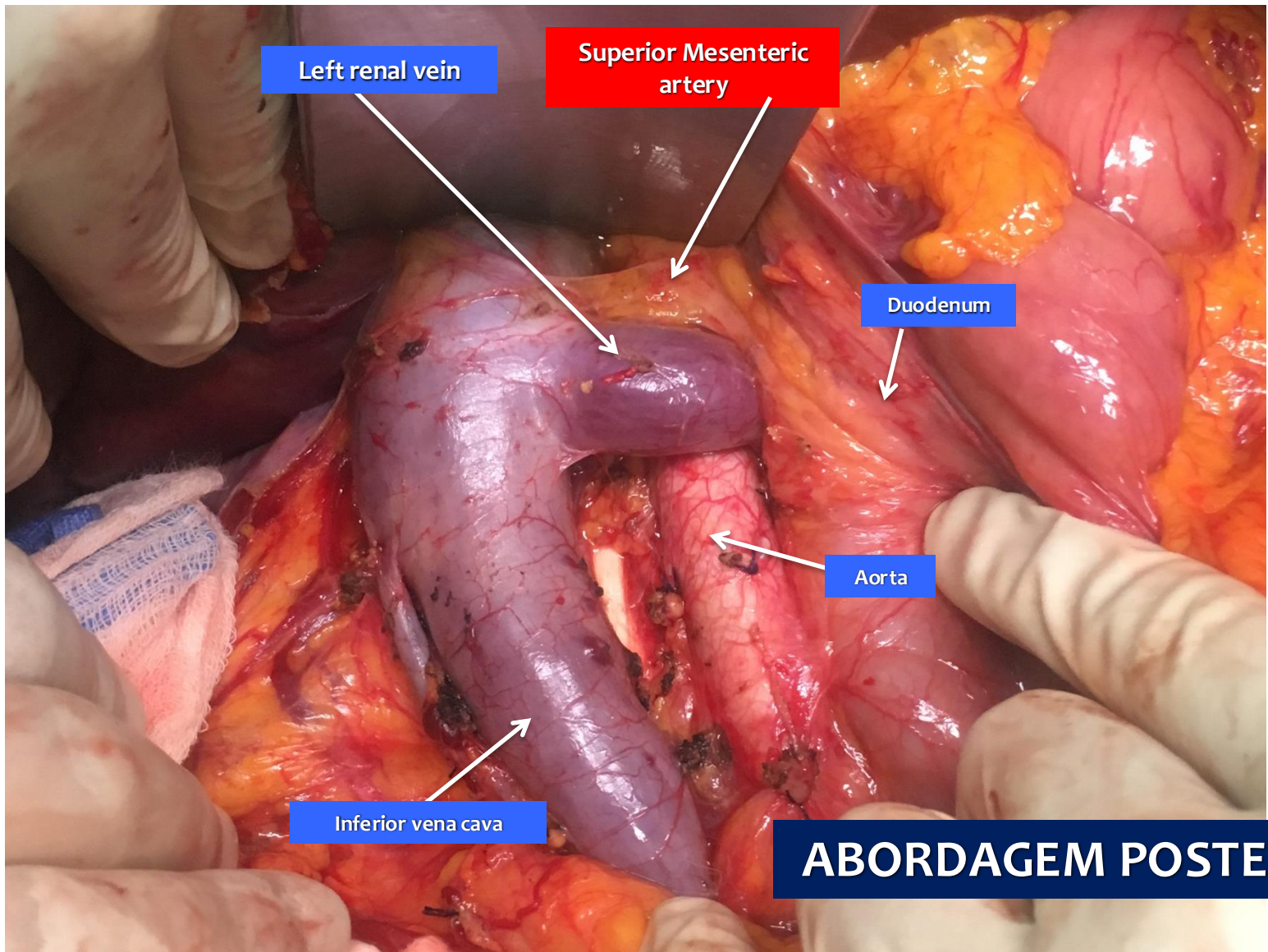


ARTERY FIRST



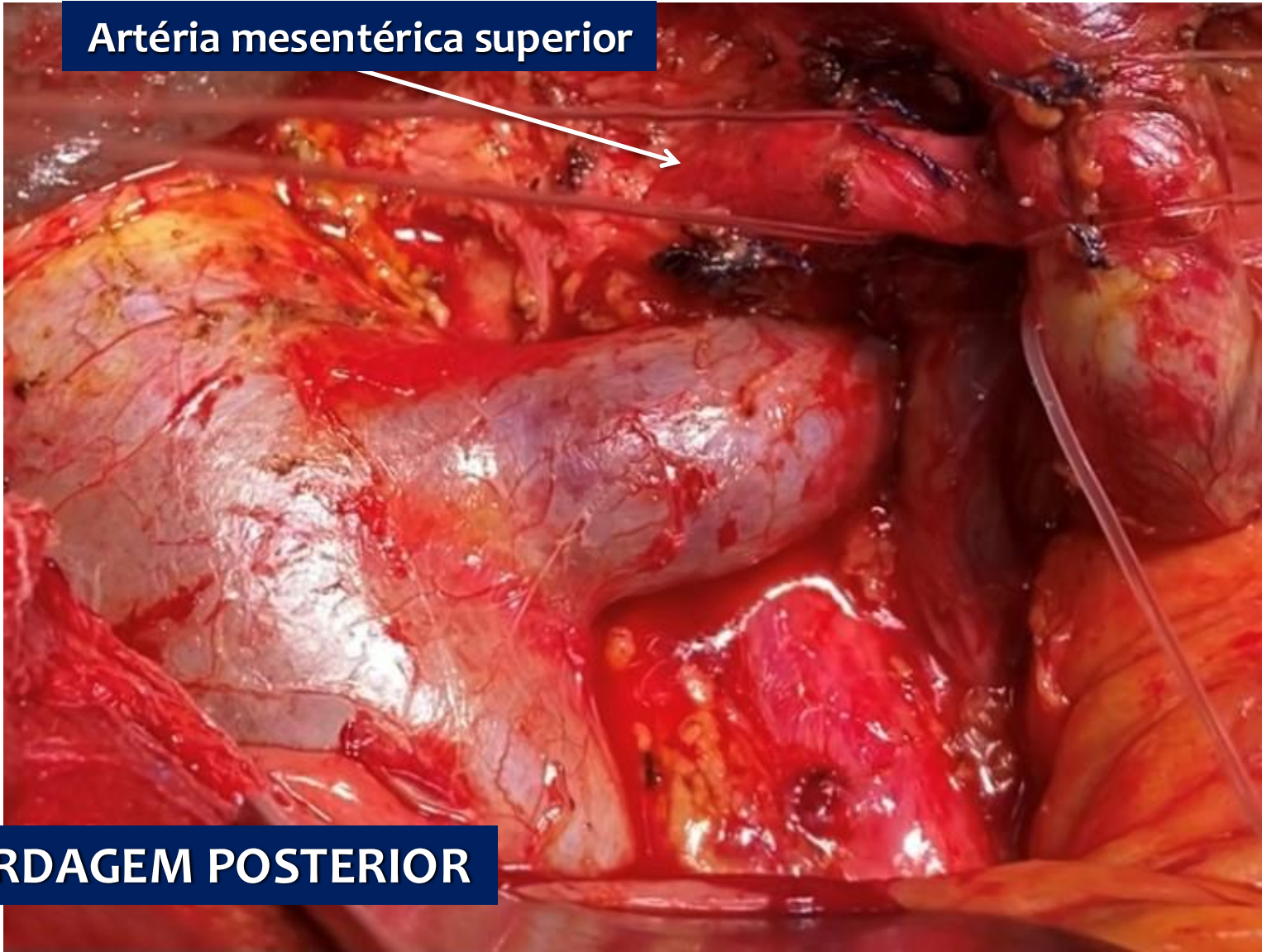ABORDAGEM POSTERIOR





ABORDAGEM POSTERIOR

Artéria mesentérica superior



ABORDAGEM POSTERIOR



What do surgeons need to know about the mesopancreas


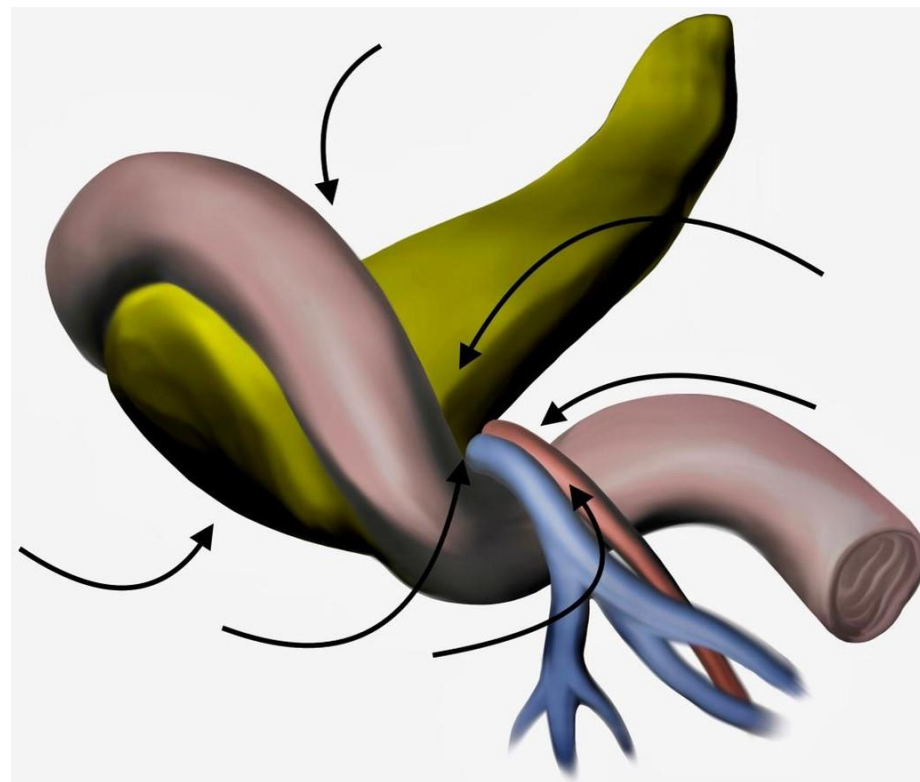
Eduardo de Souza M. Fernandes^{1,2} · Oliver Strobel^{3,4} · Camila Girão^{1,2} · Jose Maria A. Moraes-Junior^{5,6} · Orlando Jorge M. Torres^{5,6} 

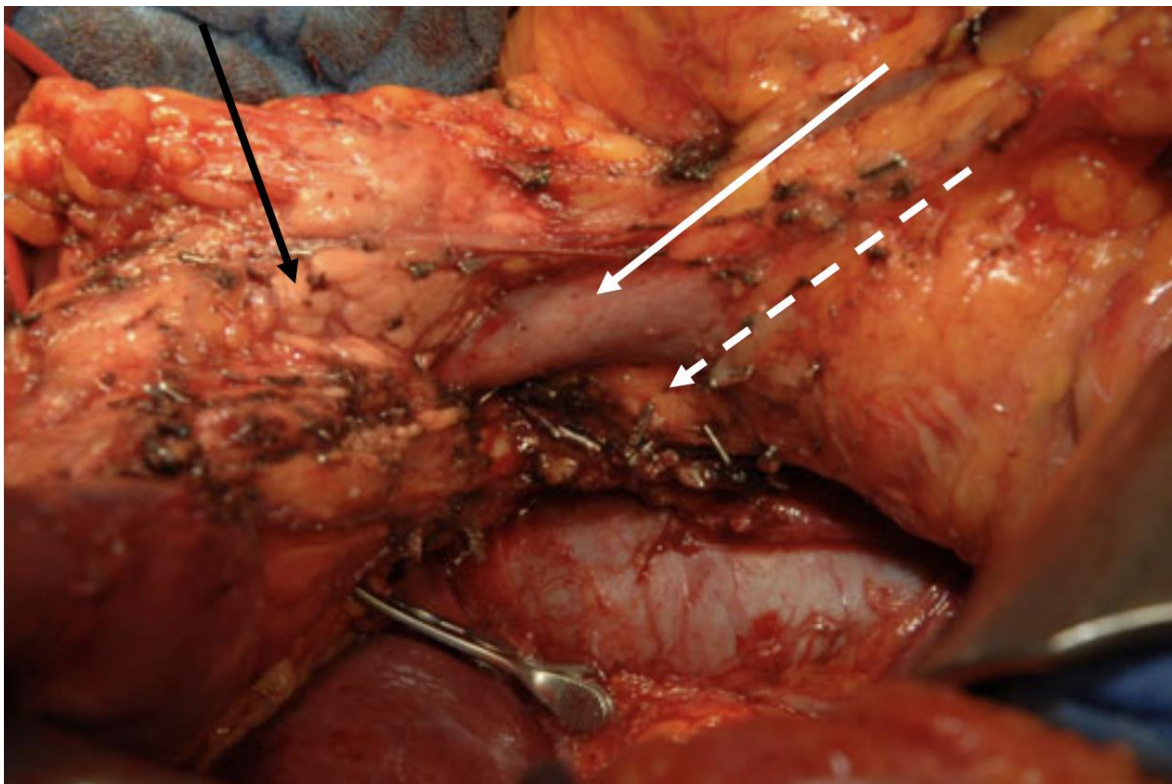
Table 3 Advantages of the artery-first approach (SHARMA) [35]

1. Resection without breaching the tumor extension plane, thereby minimizing cell spillage
2. Increases curative (R0) resection, decreases local recurrence
3. Complete resection of peripancreatic retroperitoneal tissue around the plexuses
4. Increased lymph nodal clearance
5. Early assessment of non-resectability (SMA involvement), avoiding useless R2 resections
6. Better delineation of SMA and identification of RHA anomalies
7. Easier en bloc resection and reconstruction of SMV-PV by “no touch” technique
8. Reduced need for graft substitutions
9. Reduced operative time and blood loss (early ligation of IPDA/JA1)

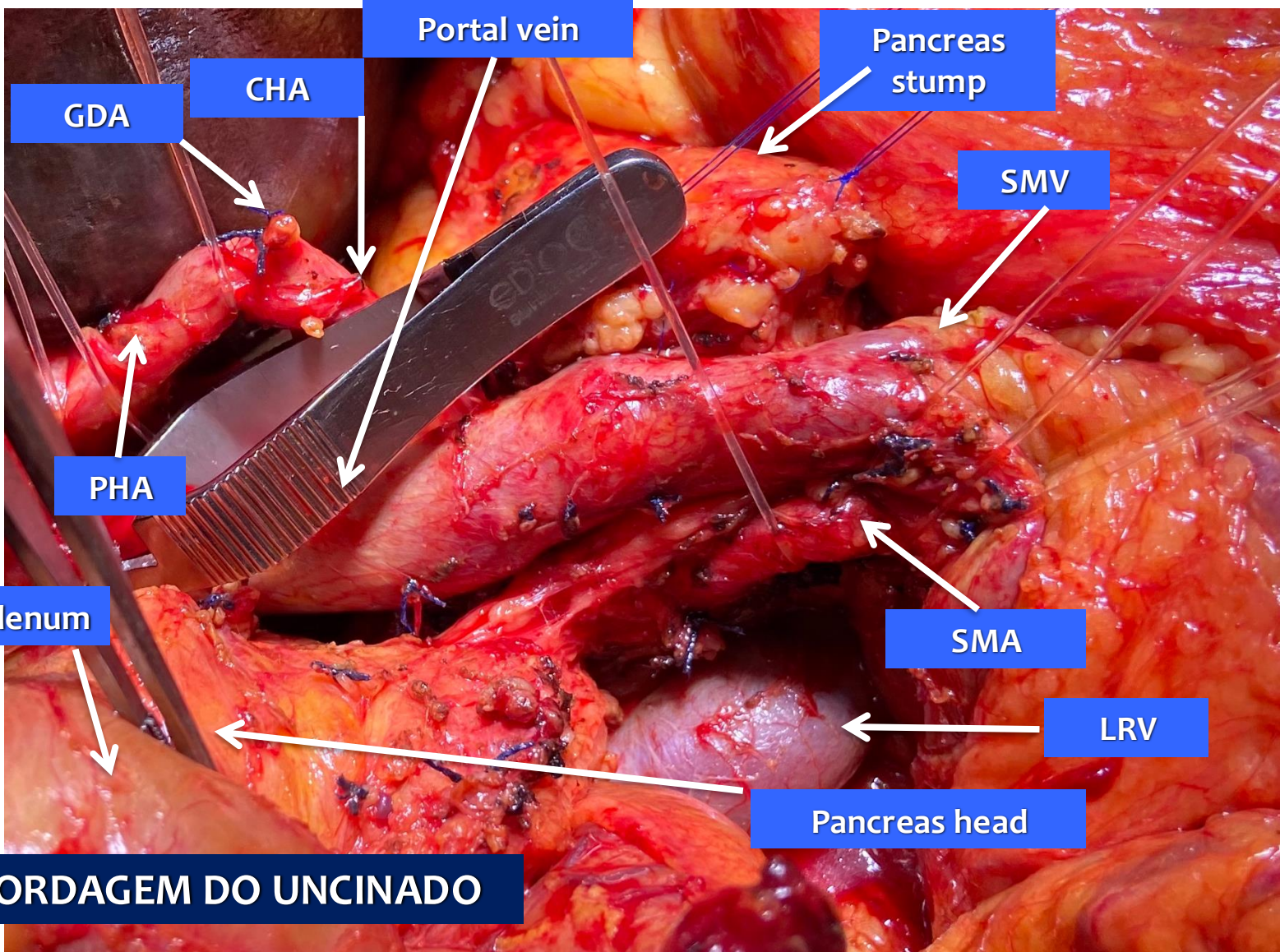


HOW TO DO IT

Uncinate process first—a novel approach for pancreatic head resection

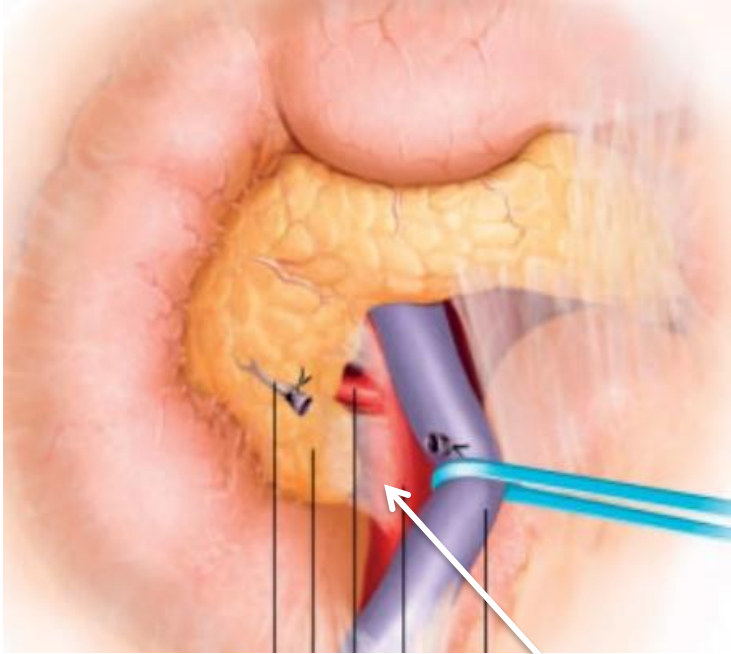


ABORDAGEM DO UNCINADO

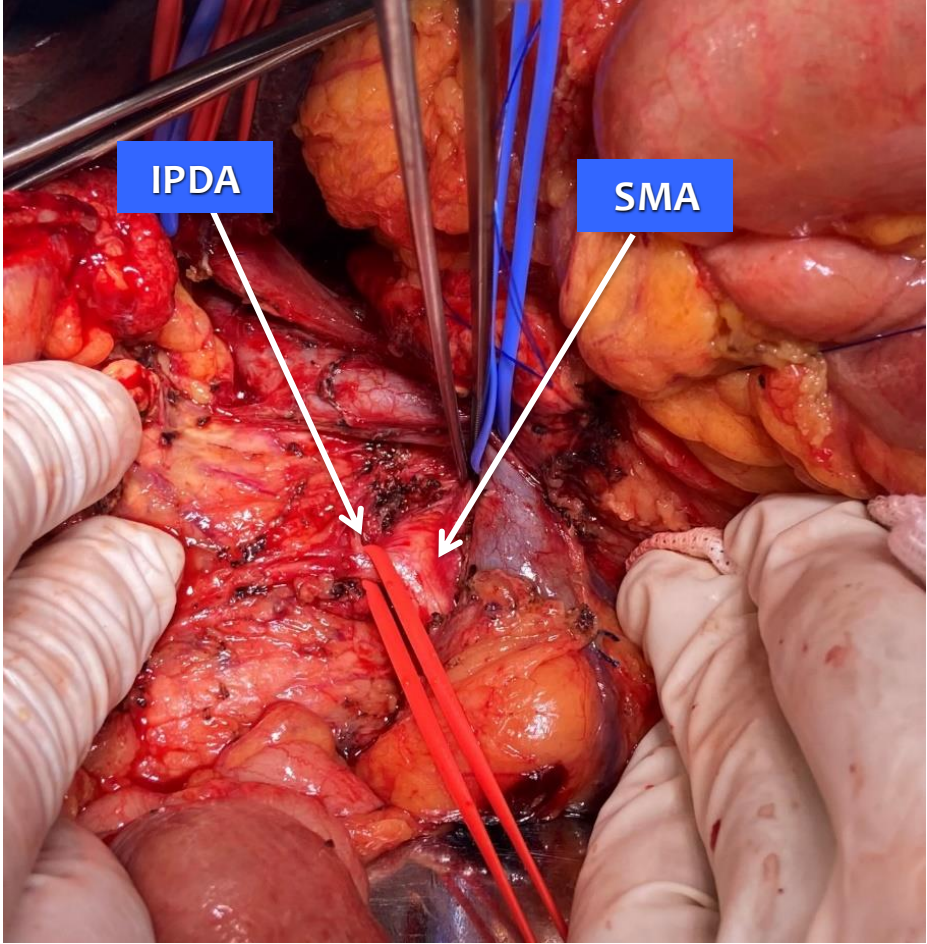
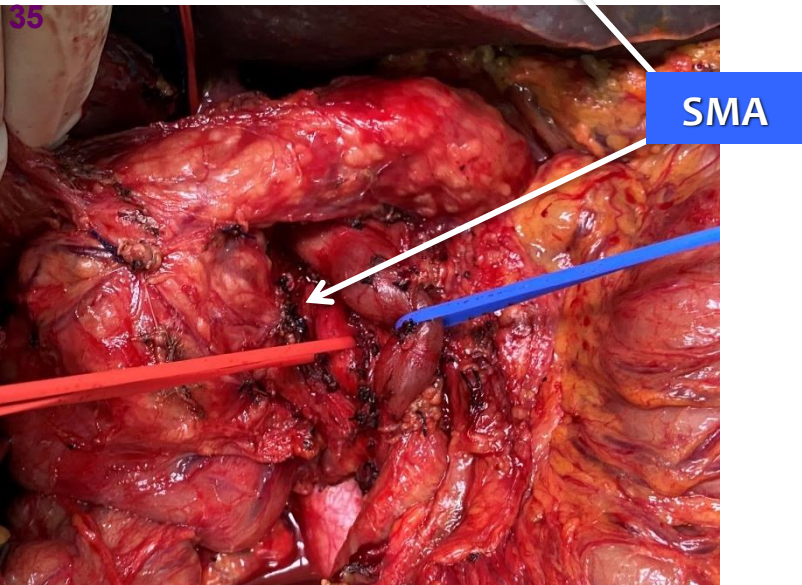


ABORDAGEM DO UNCINADO

ARTERY FIRST

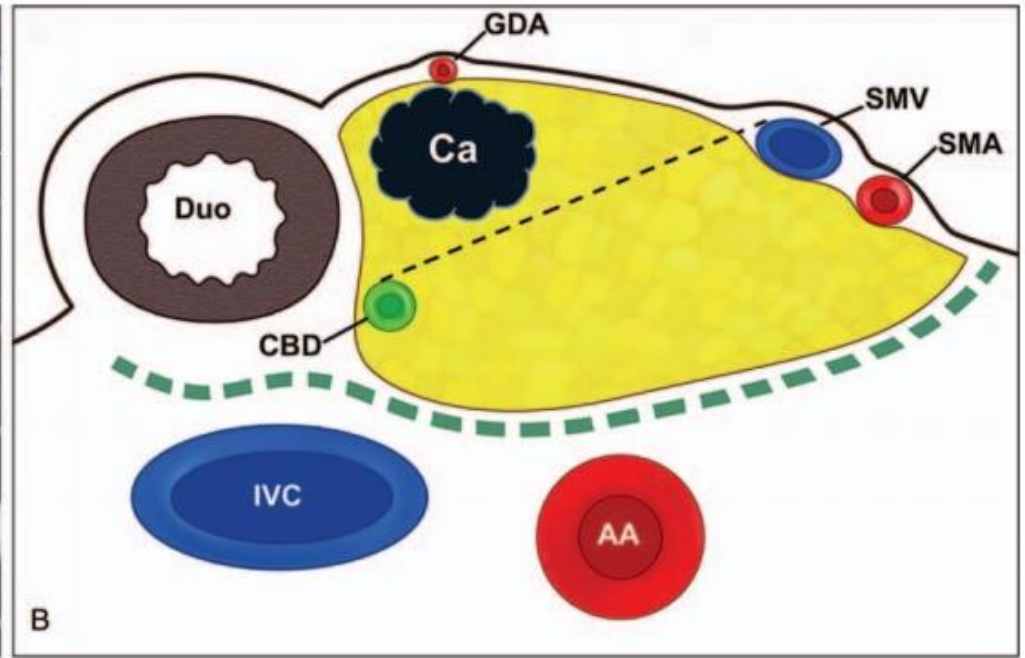
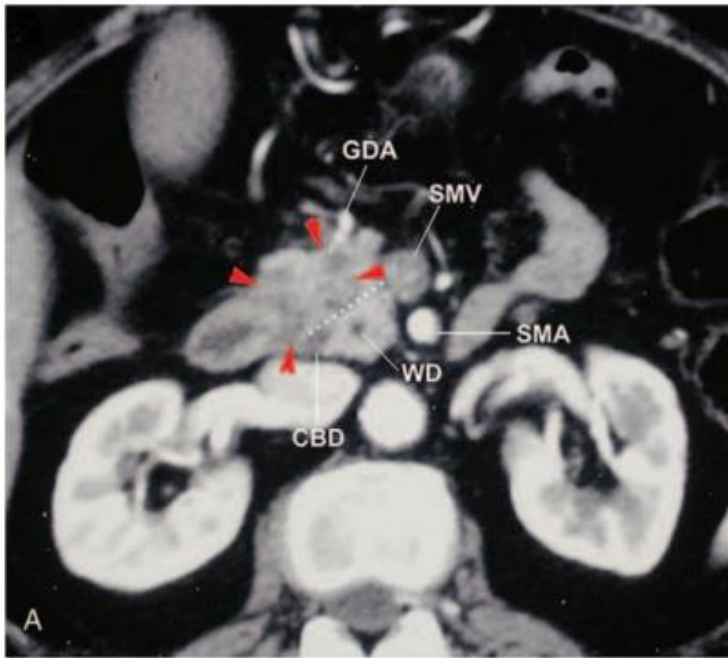


Pandanaboyana S, et al. Br J Surg 2012;99:1027-35



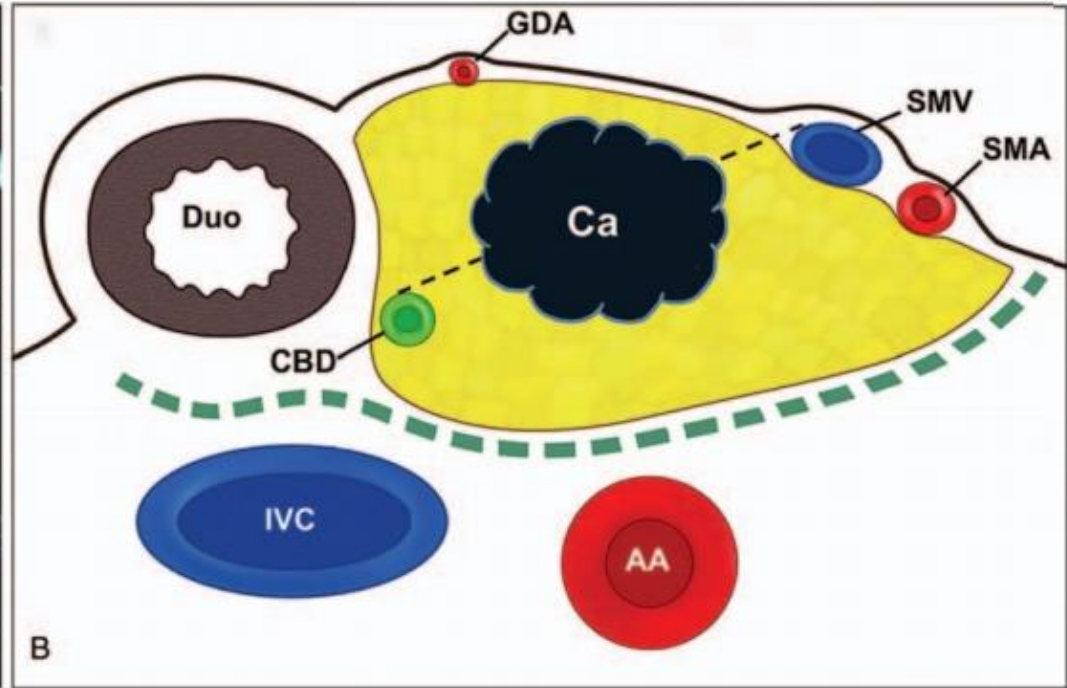
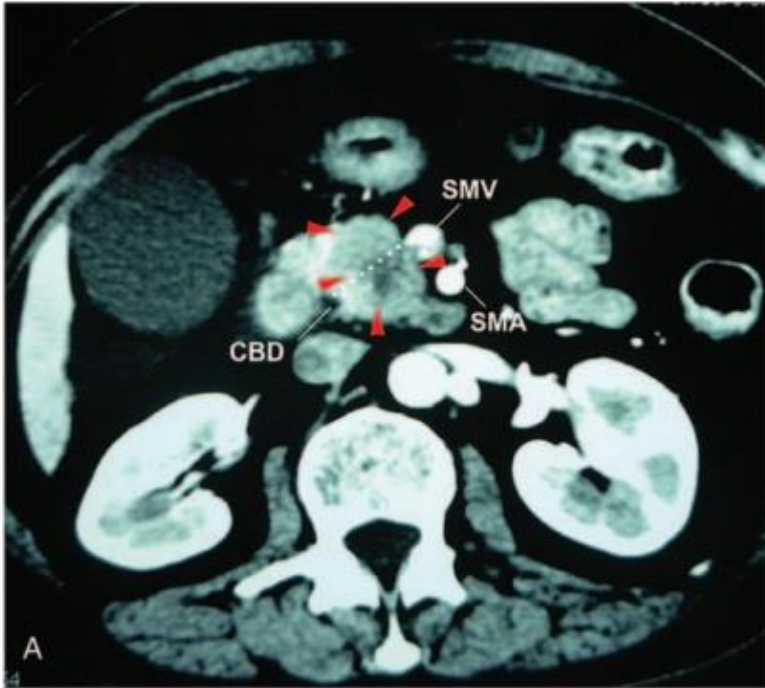
ABORDAGEM DO UNCINADO

KOCHER MANEUVER



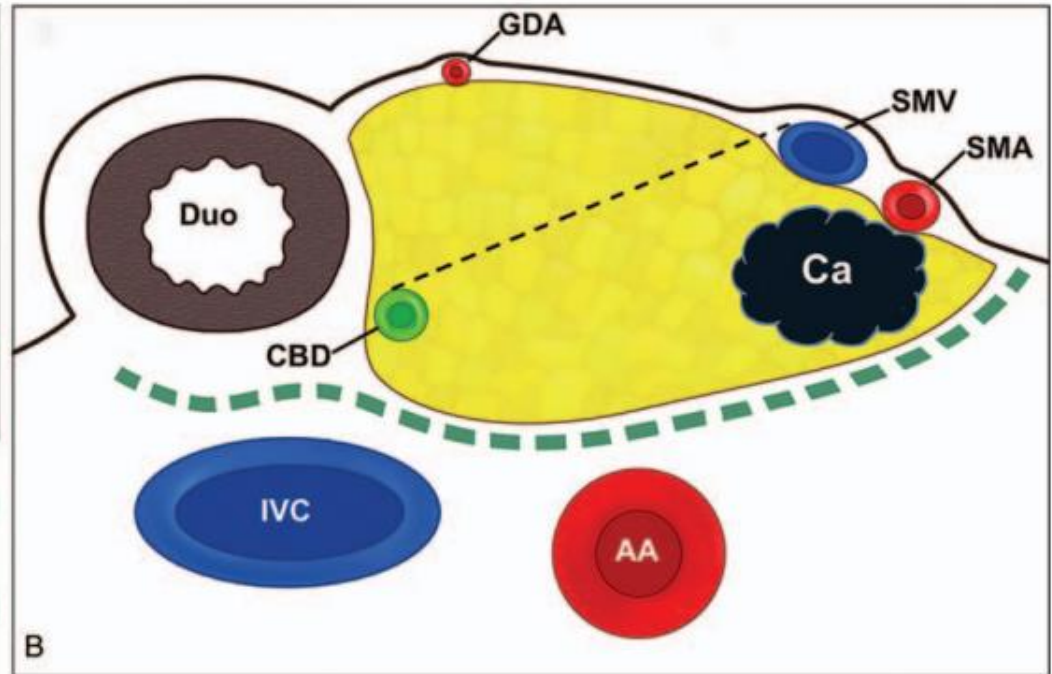
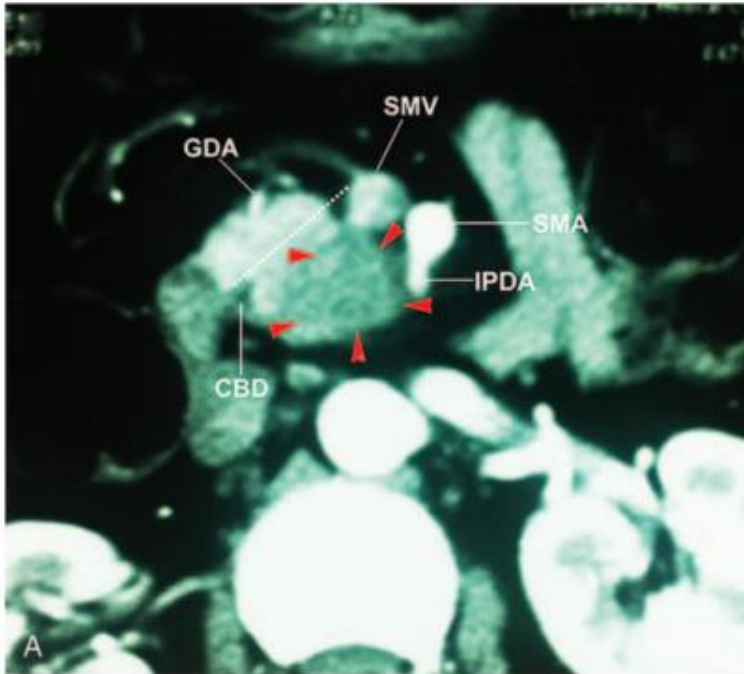
Tumor location: anterior

KOCHER MANEUVER



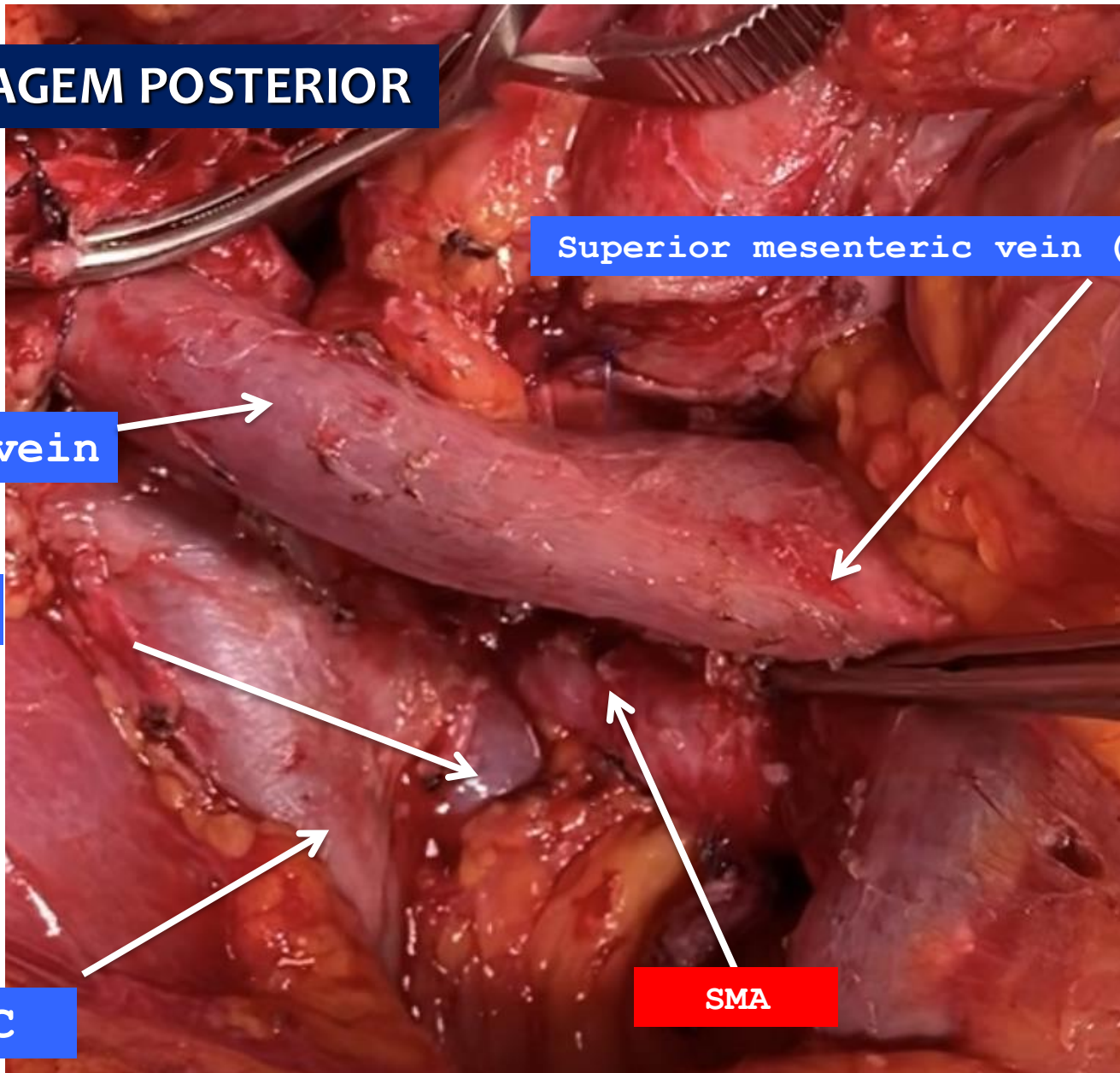
Tumor location: central head

KOCHER MANEUVER



Tumor location: uncinate

ABORDAGEM POSTERIOR



Superior mesenteric vein (SMV)

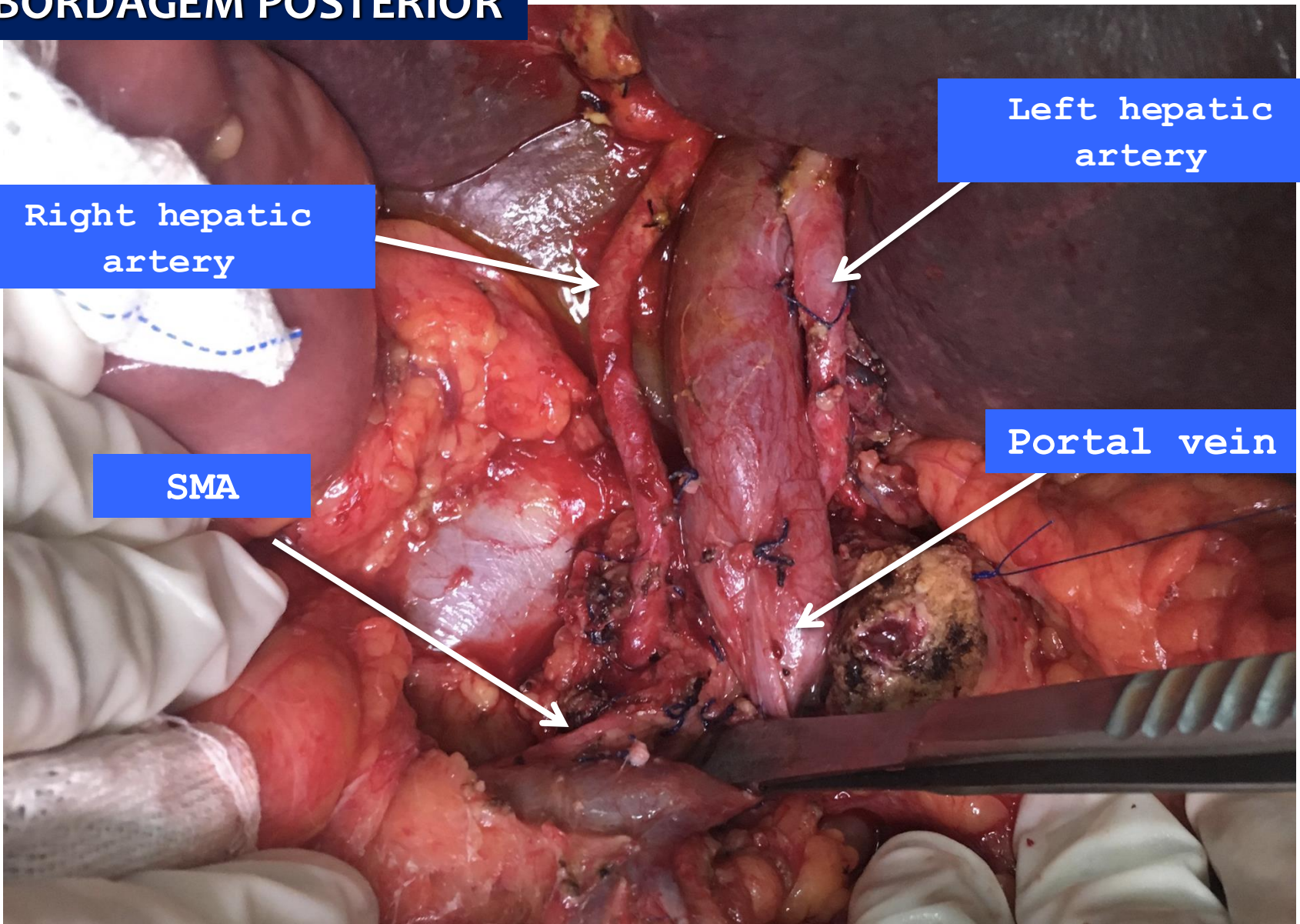
Portal vein

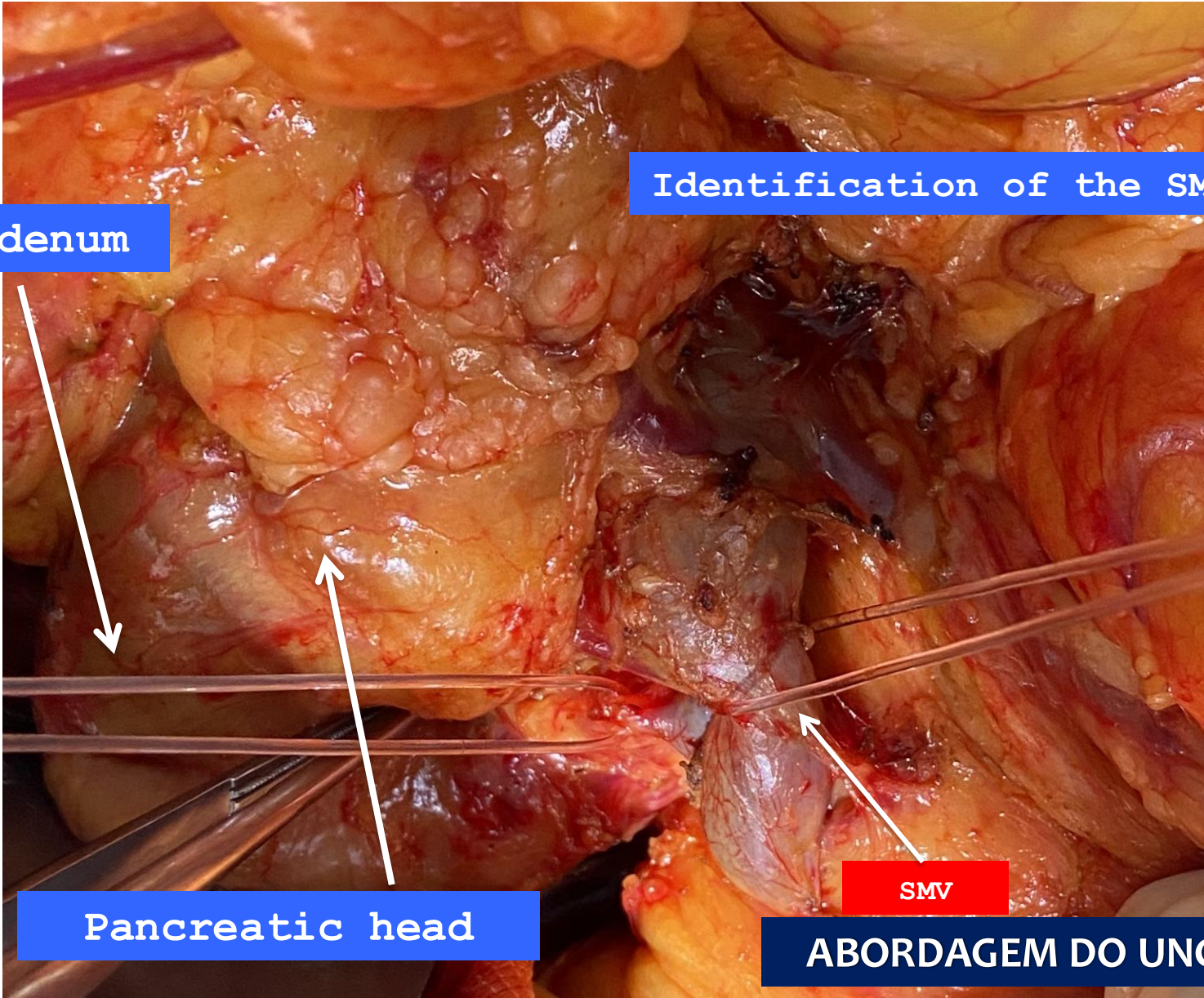
LRV

IVC

SMA

ABORDAGEM POSTERIOR





Duodenum

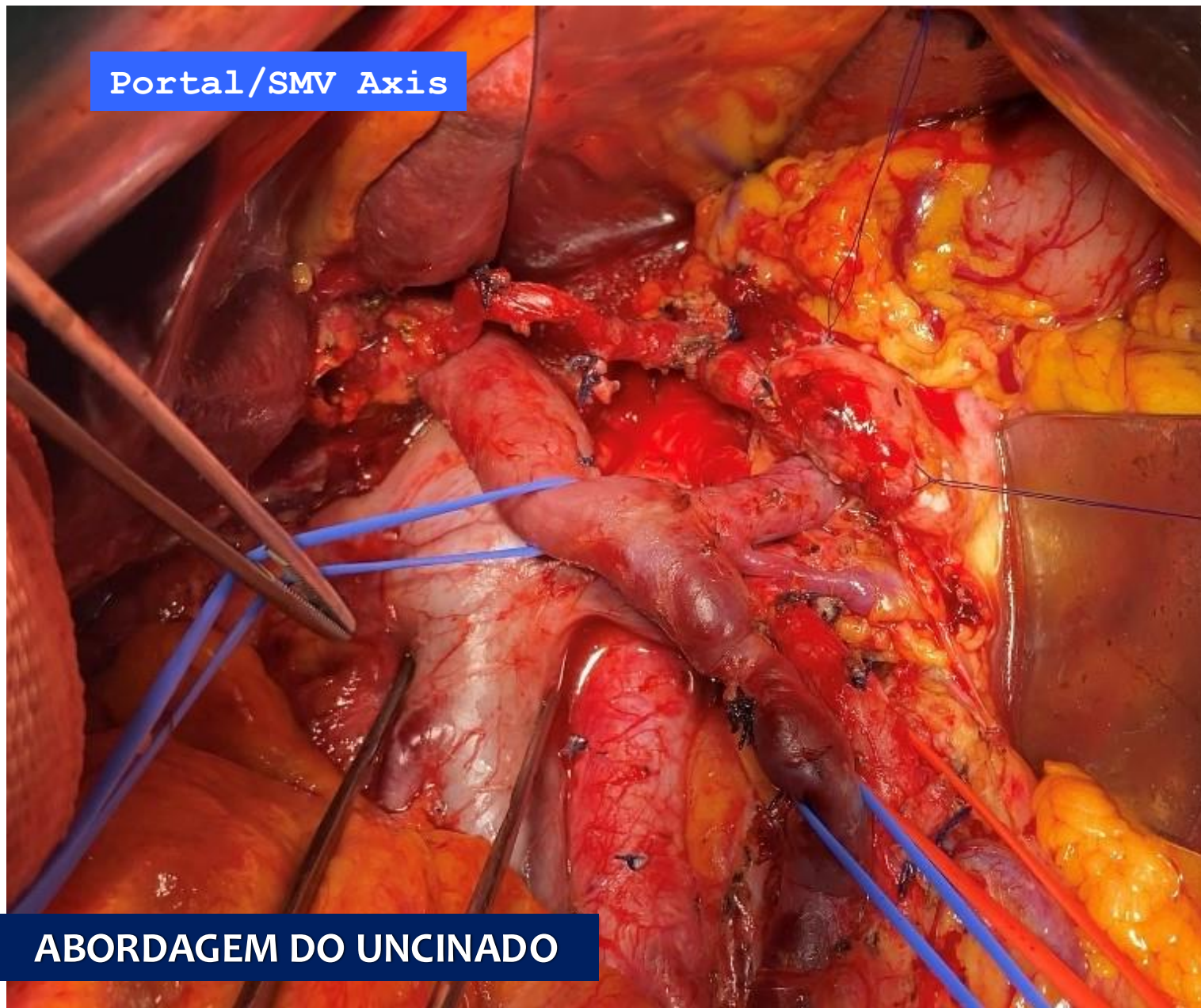
Identification of the SMV

Pancreatic head

SMV

ABORDAGEM DO UNCINADO

Portal/SMV Axis



ABORDAGEM DO UNCINADO

CENTRAL VASCULAR LIGATION

CELIAC AXIS SYSTEM

GDA

PORTAL/SMV SYSTEM

GTH
IPDV



IPDA

SMA SYSTEM

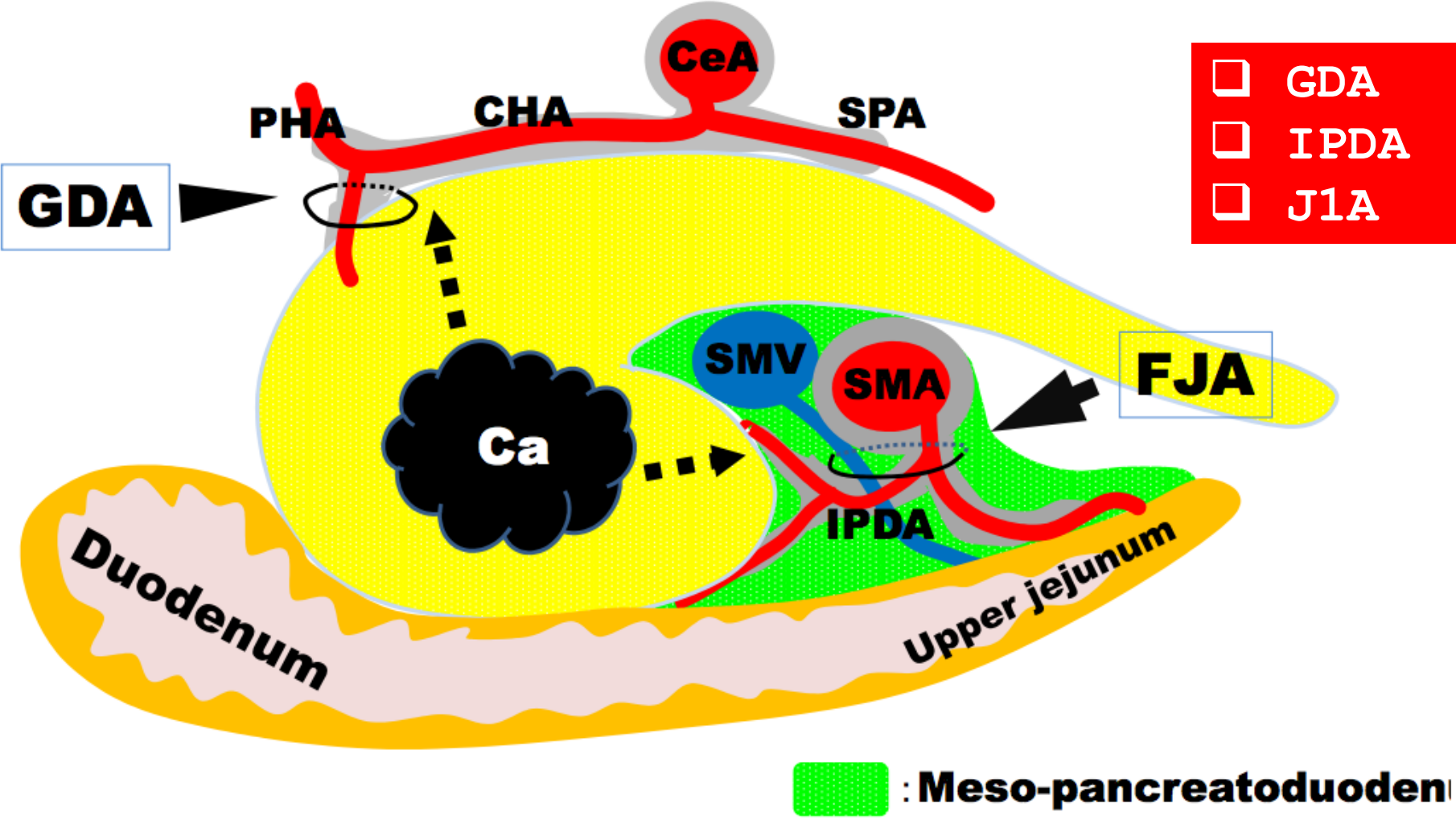
CELIAC GANGLION

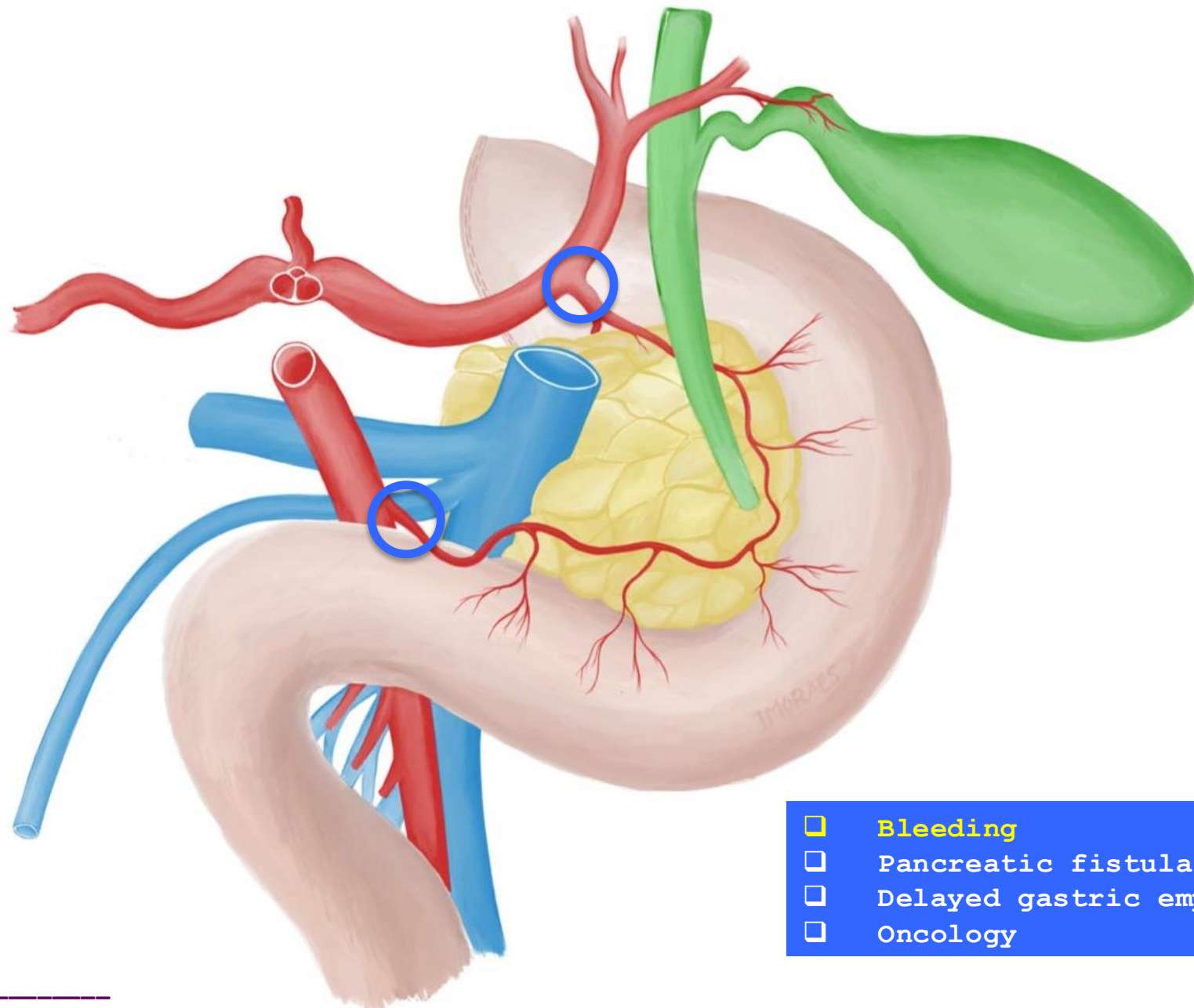
CENTRAL VASCULAR LIGATION

- ❑ **Bleeding**
- ❑ Pancreatic fistula
- ❑ Delayed gastric emptying
- ❑ Oncology

- ❑ Gastrooduodenal artery (GDA)
- ❑ Inferior pancreatoduodenal artery (IPDA)
- ❑ First jejunal artery (J1A)

CENTRAL VASCULAR LIGATION





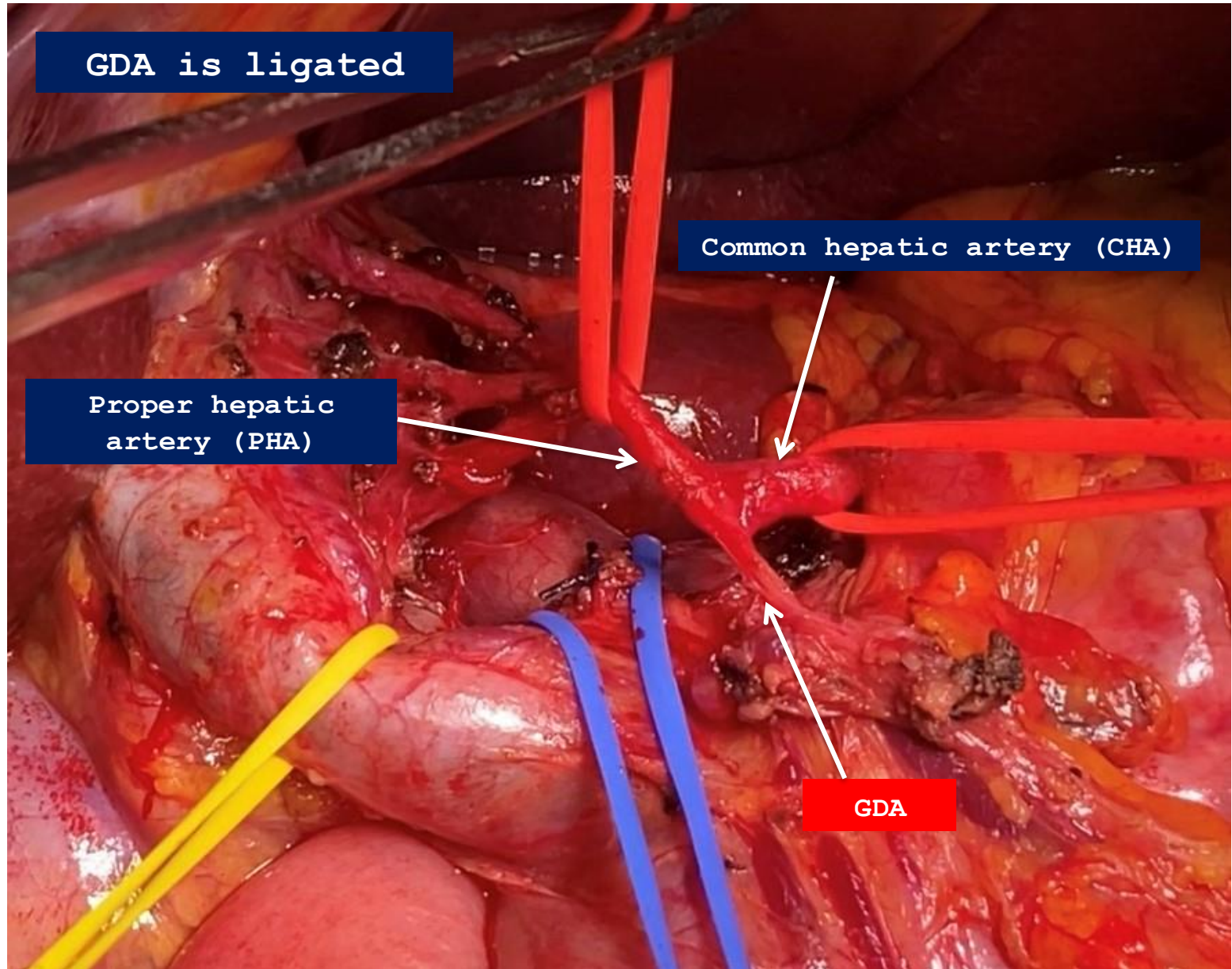
- Bleeding
- Pancreatic fistula
- Delayed gastric emptying
- Oncology

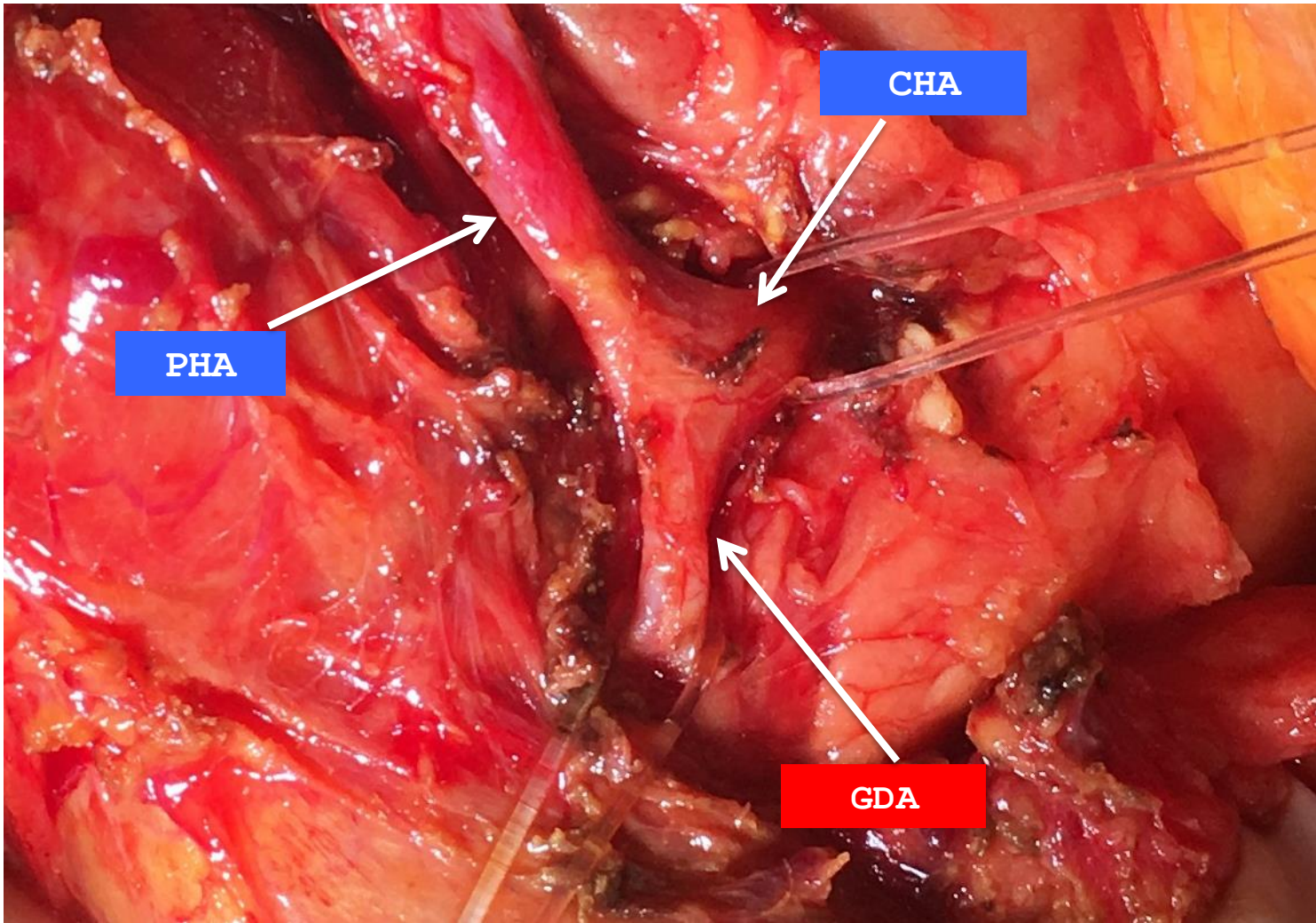
GDA is ligated

Common hepatic artery (CHA)

Proper hepatic artery (PHA)

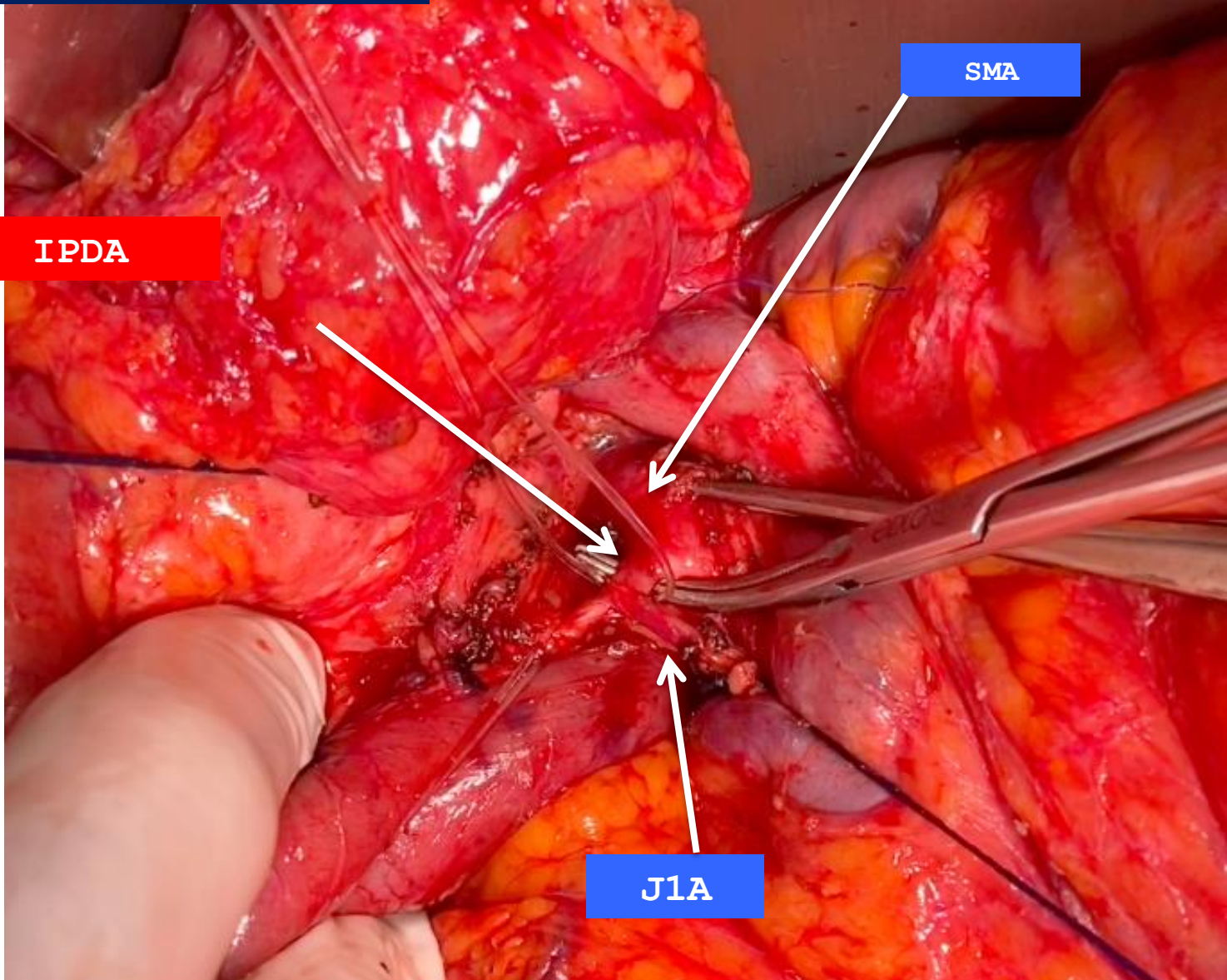
GDA





UNCINATE FIRST

IPDA



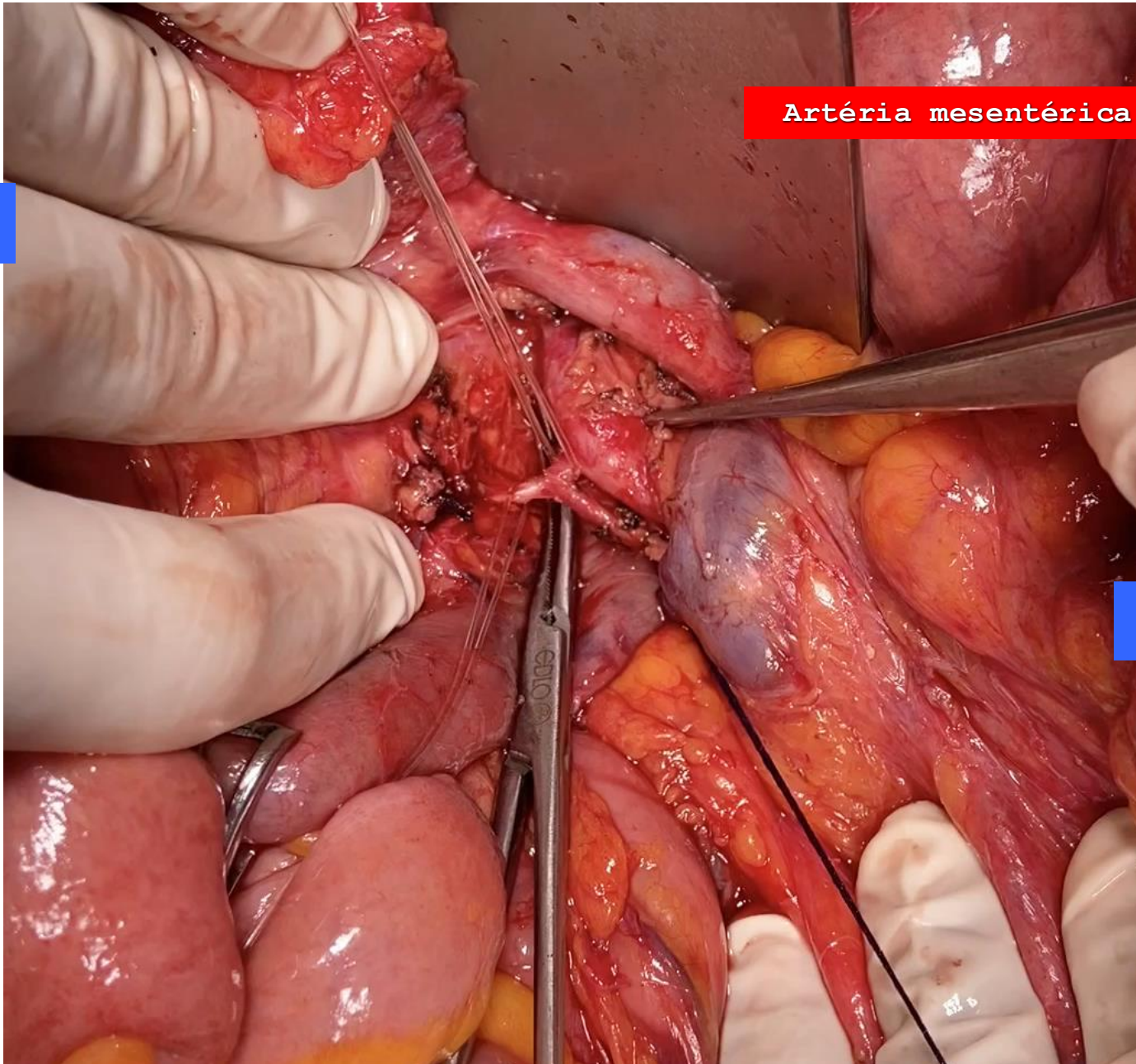
SMA

J1A

IPDA

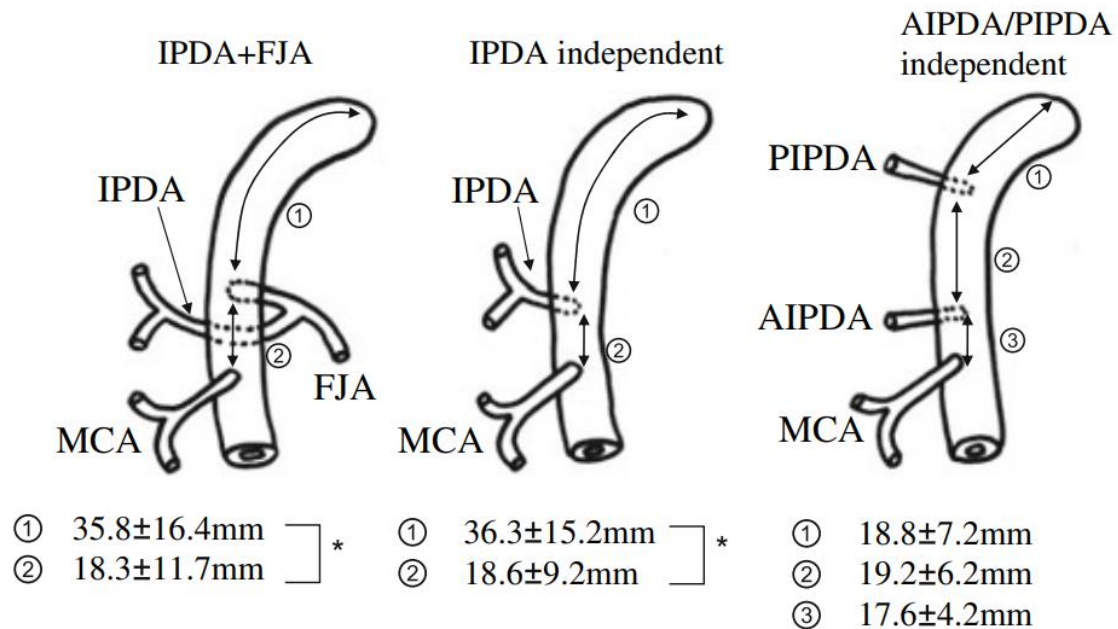
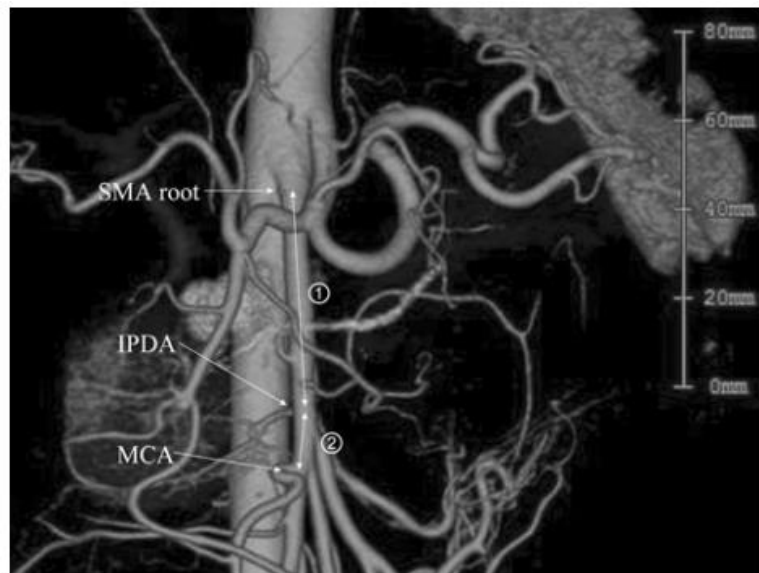
Artéria mesentérica Superior

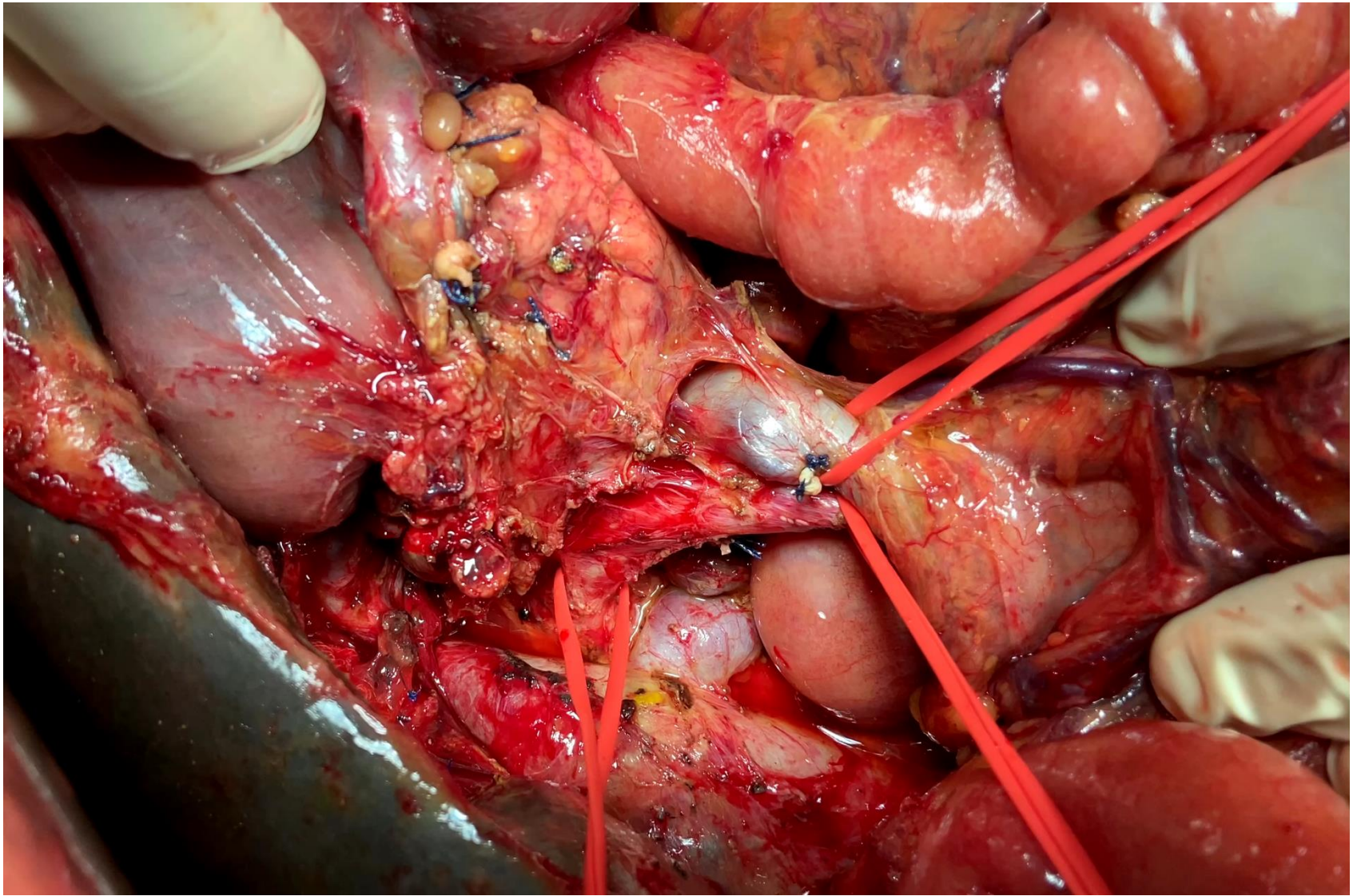
J1A



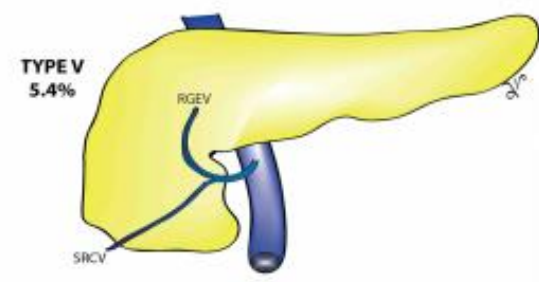
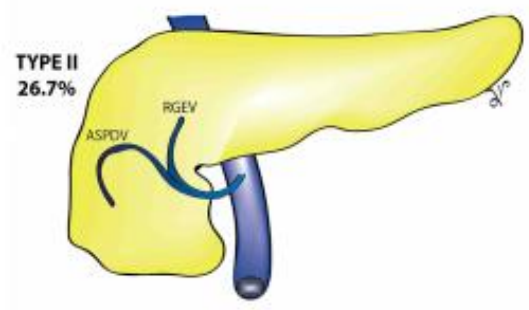
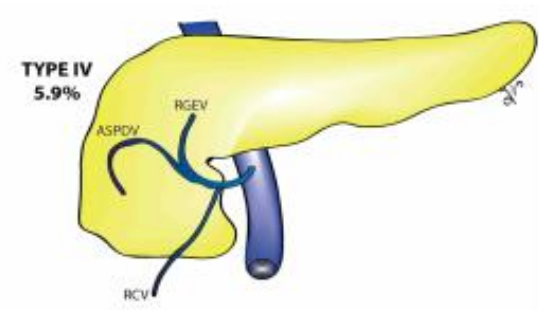
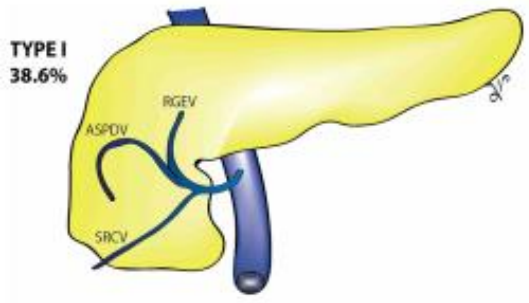
Three-dimensional models of arteries constructed using multidetector-row CT images to perform pancreatoduodenectomy safely following dissection of the inferior pancreaticoduodenal artery

IPDA

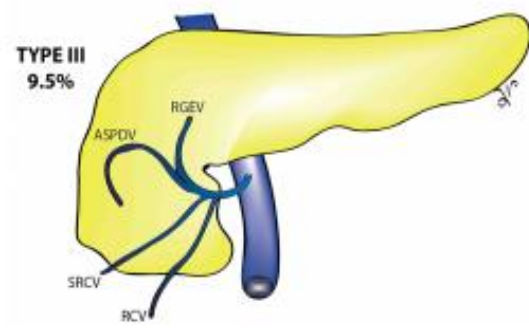




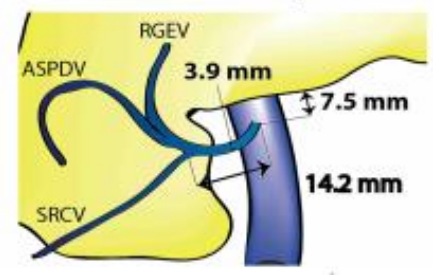
CENTRAL VENOUS LIGATION



TYPE VI - all the others

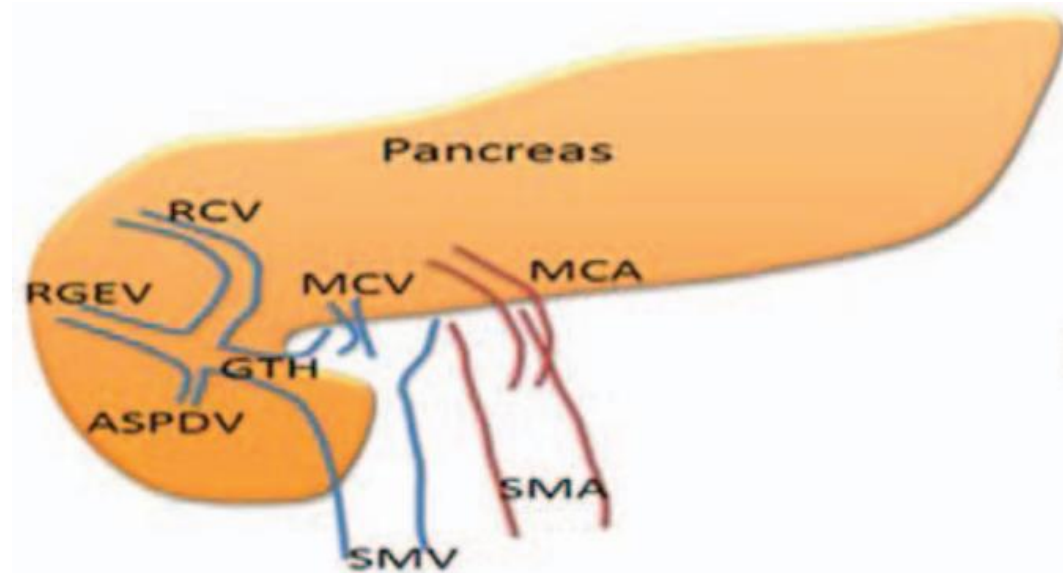
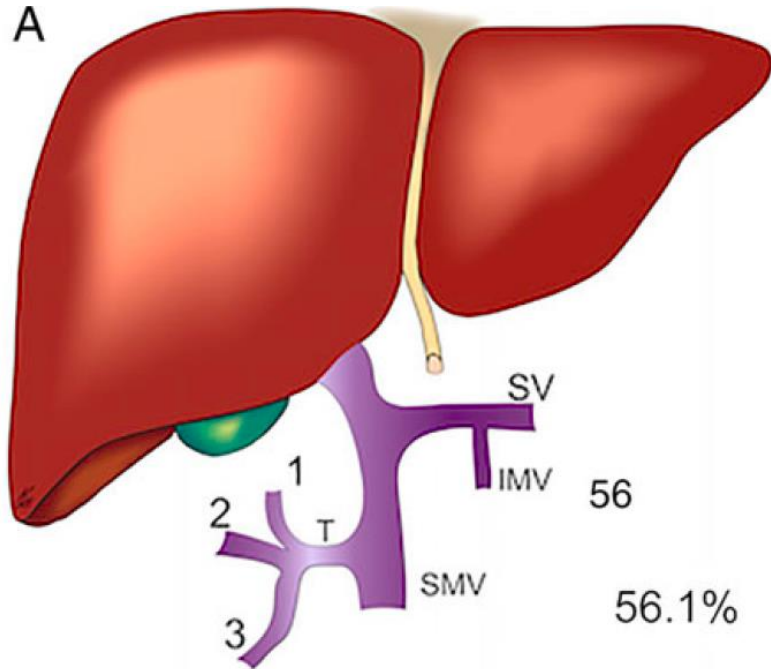


Diameter, length, distance from inferior border of the pancreas



- ❑ GASTROCOLIC TRUNK OF HENLE
- ❑ INFERIOR PANCREATODUODENAL VEIN (IPDV)

☐ GASTROCOLIC TRUNK OF HENLE



- ☐ RIGHT GASTROEPIPLOIC VEIN (RGEV)
- ☐ ANTERIOR SUPERIOR PANCREATODUODENAL VEIN (ASPDV)
- ☐ RIGHT COLIC VEIN RCV (Should be ligated)

UNCINATE FIRST

Duodenum

SMV

Isolated


☐ J1V (Ligated)

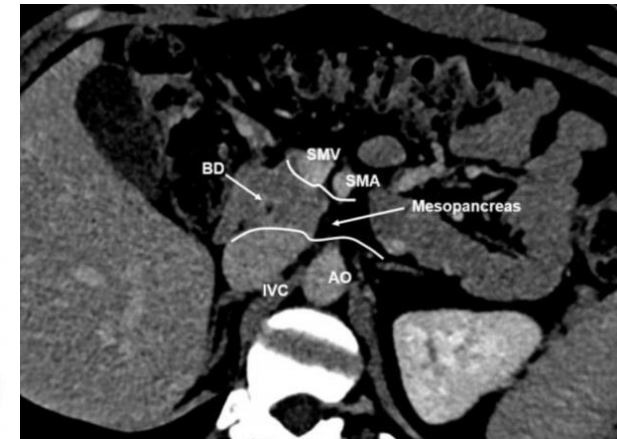
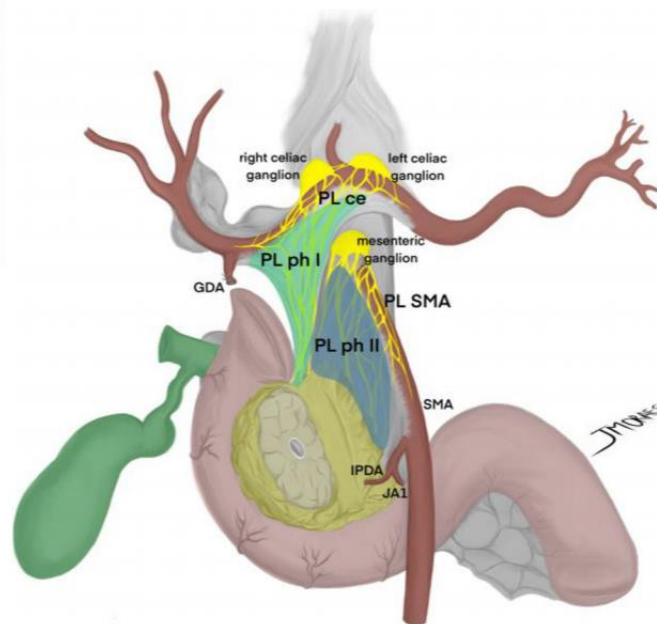
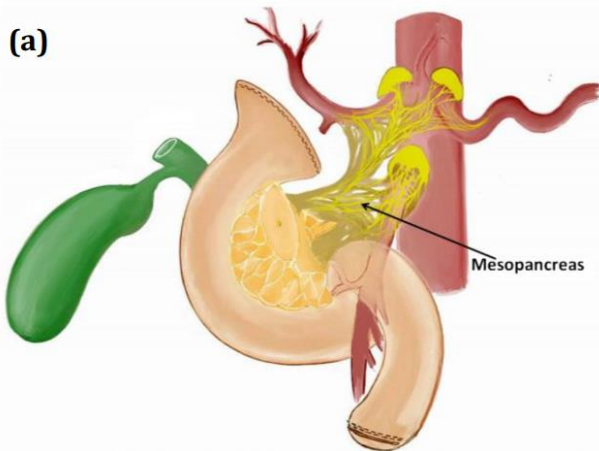
Pancreatic head





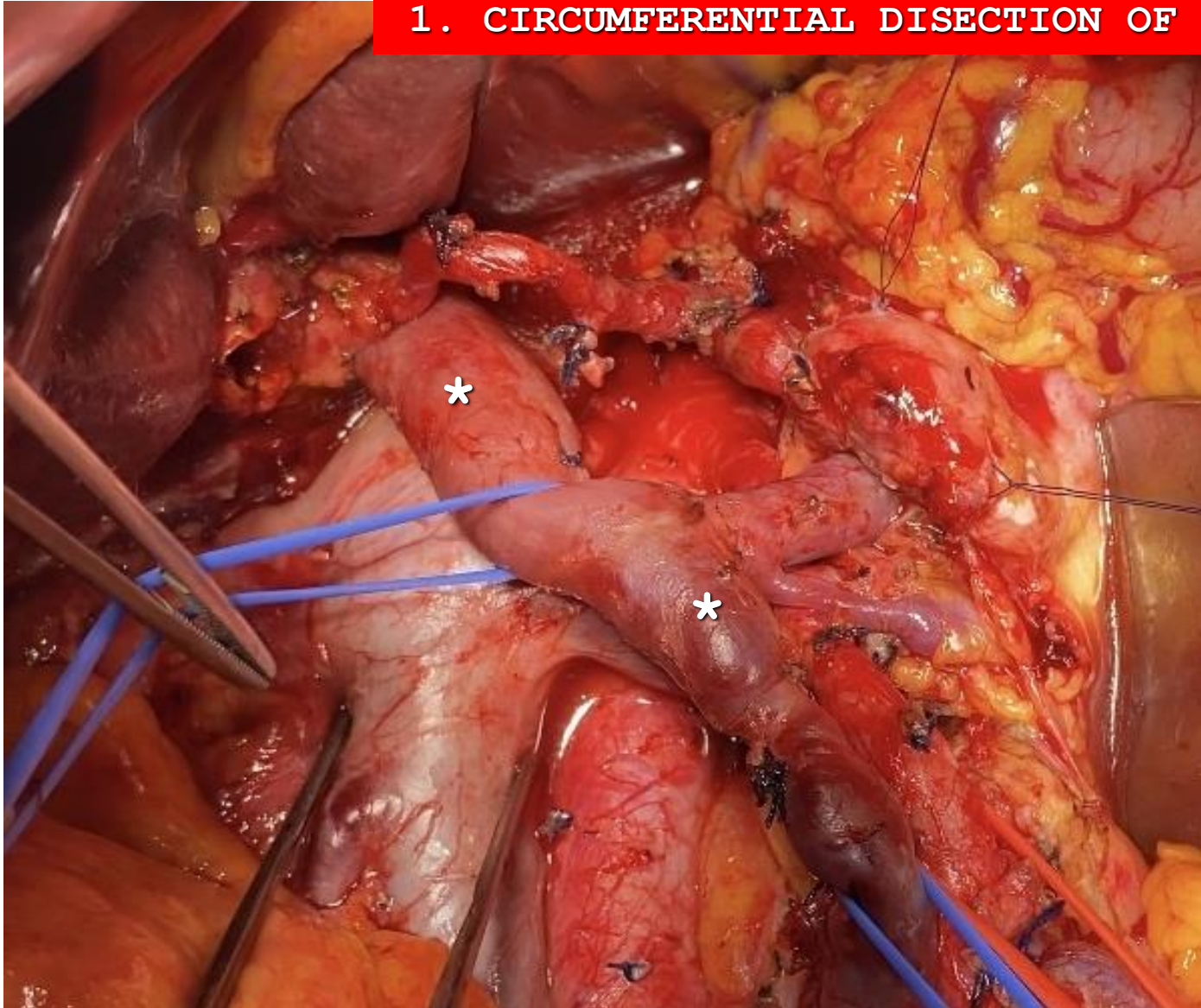
What do surgeons need to know about the mesopancreas

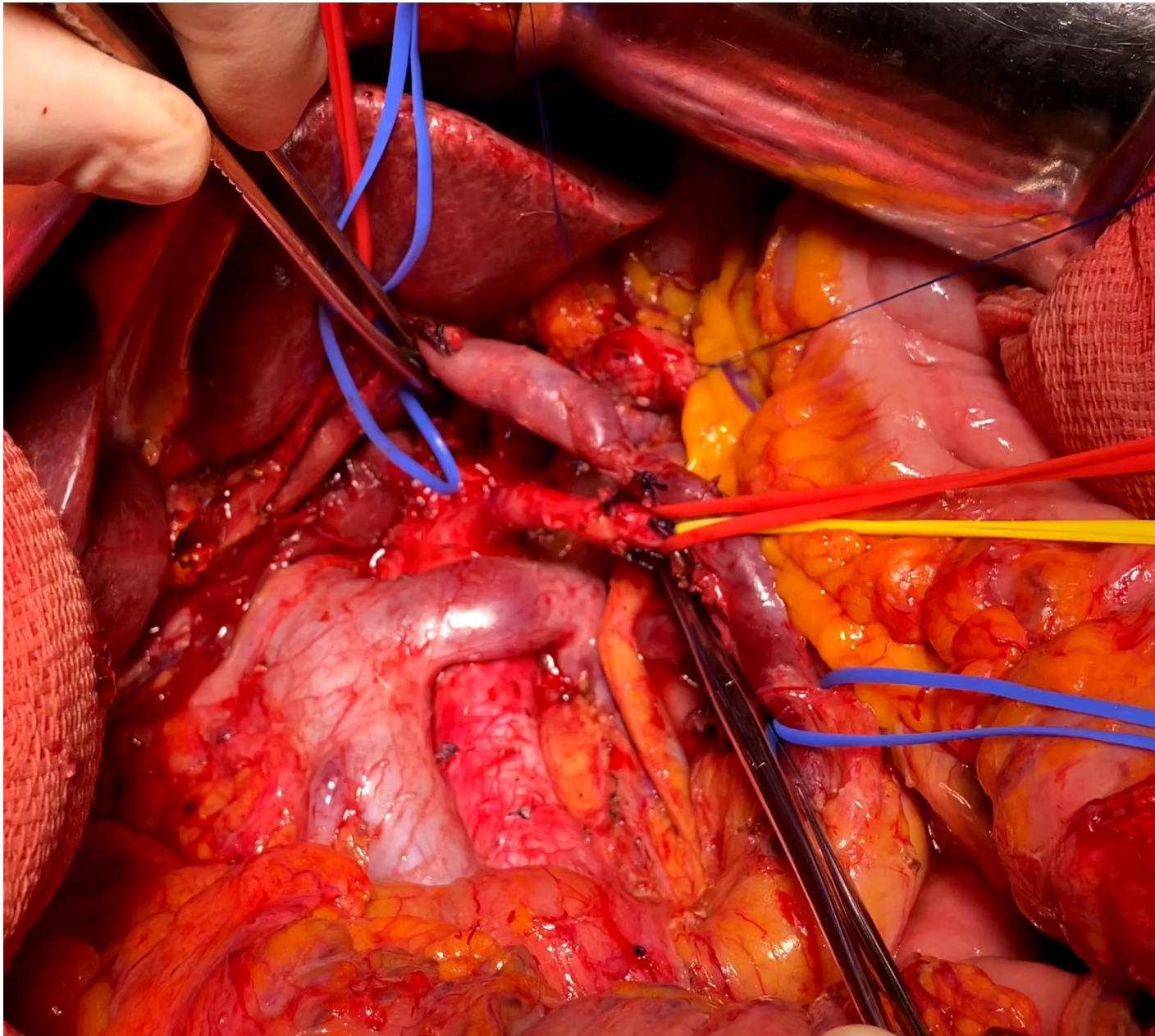
Eduardo de Souza M. Fernandes^{1,2} · Oliver Strobel^{3,4} · Camila Girão^{1,2} · Jose Maria A. Moraes-Junior^{5,6} · Orlando Jorge M. Torres^{5,6} 

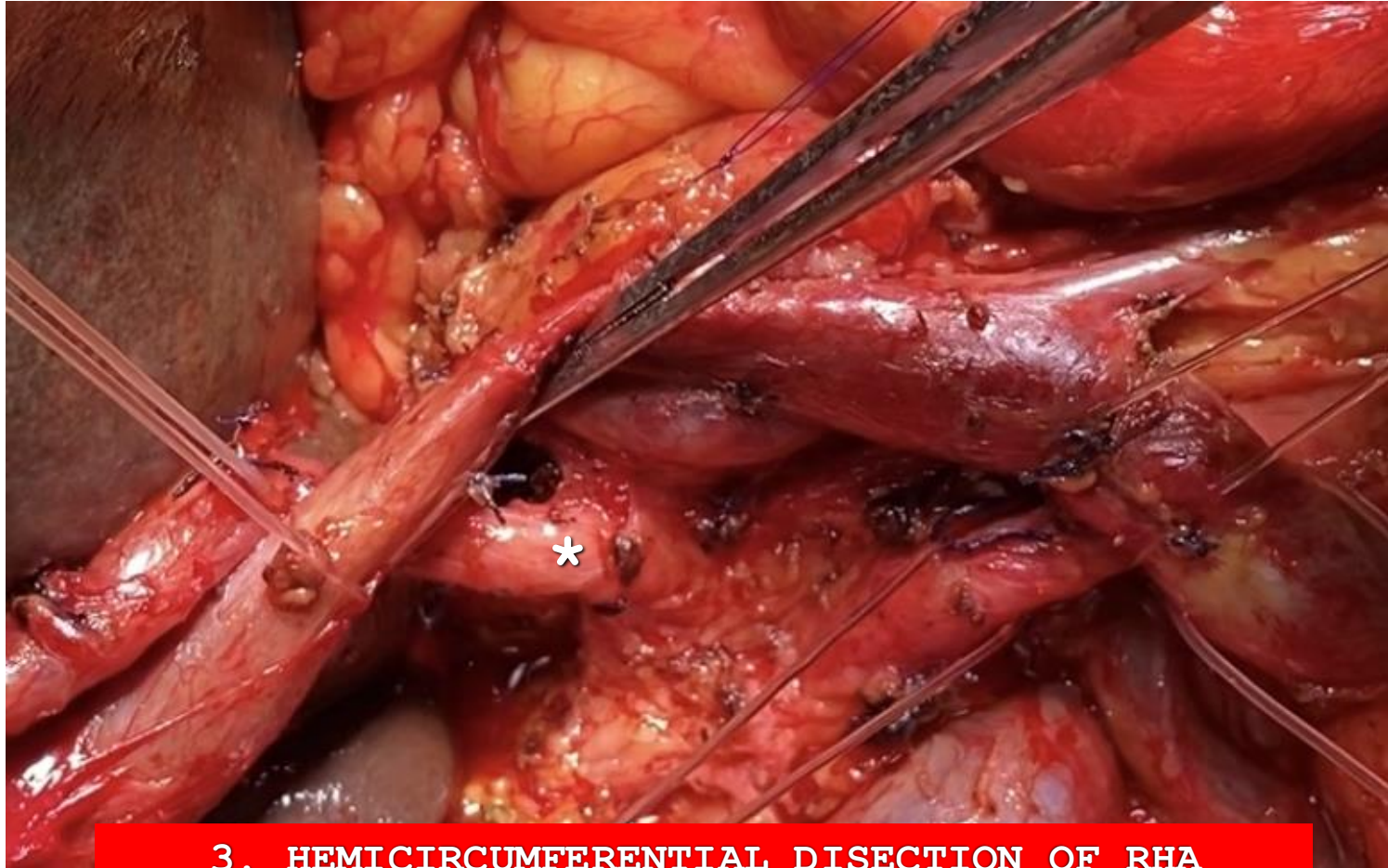

Technique

1. CIRCUMFERENTIAL DISECTION OF SMV/PV







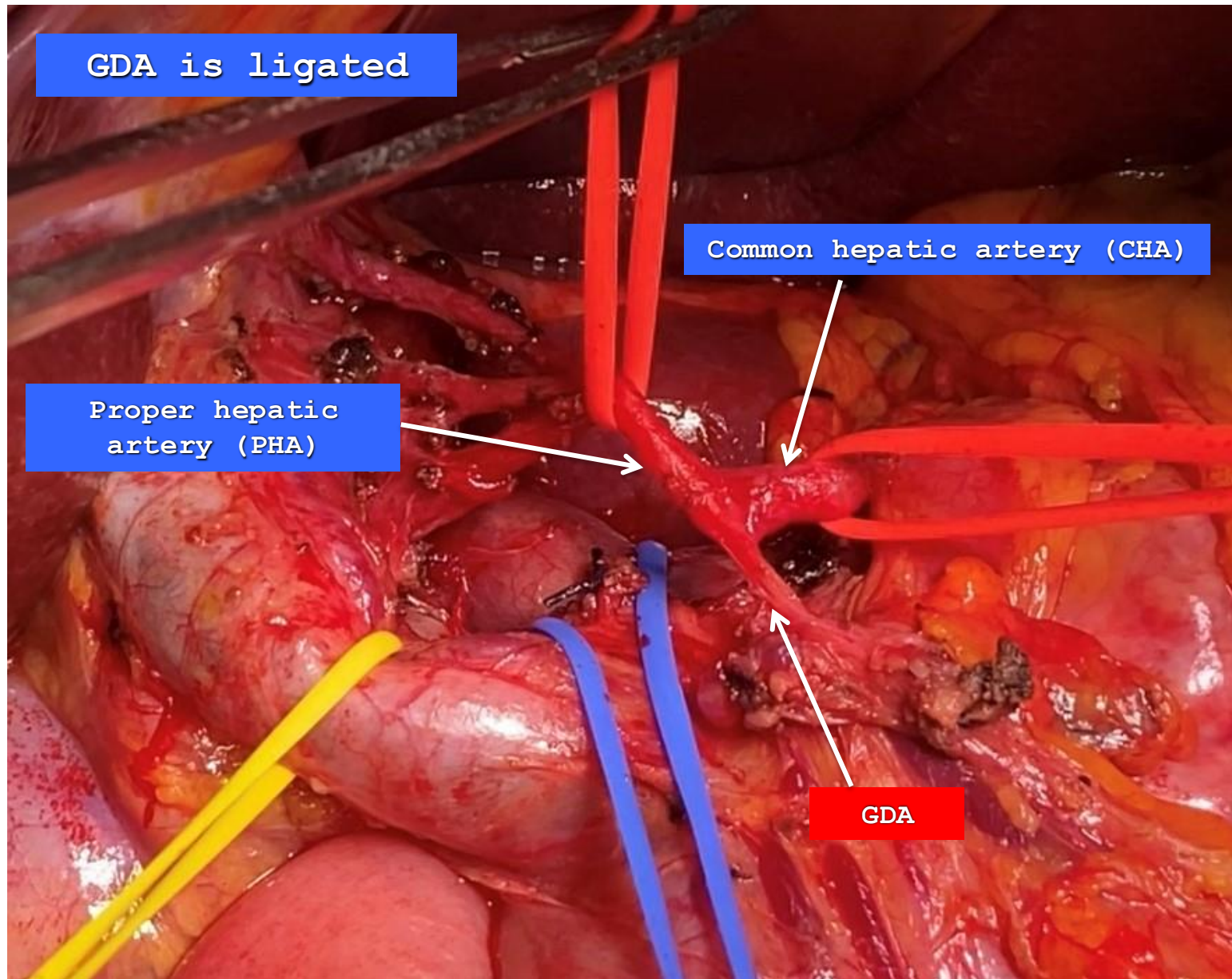
3. HEMICIRCUMFERENTIAL DISECTION OF RHA

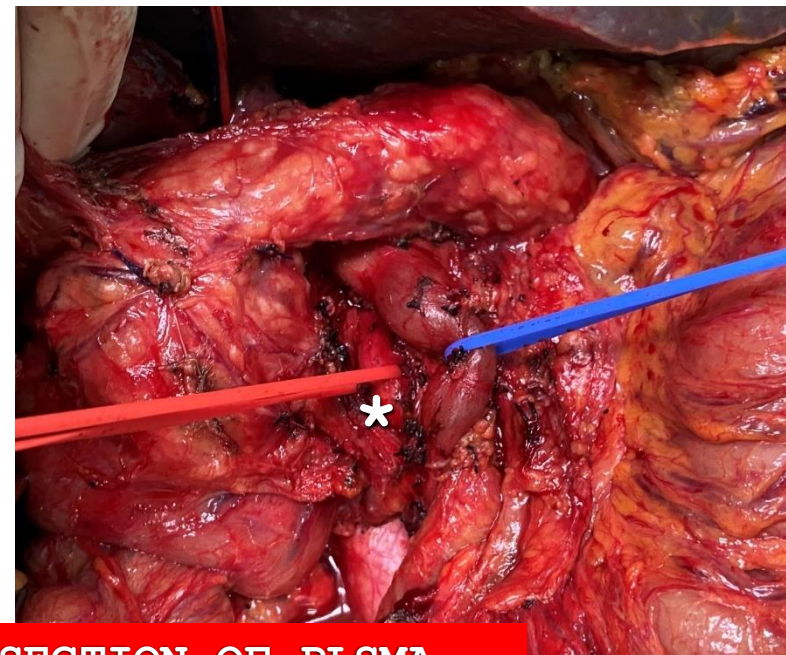
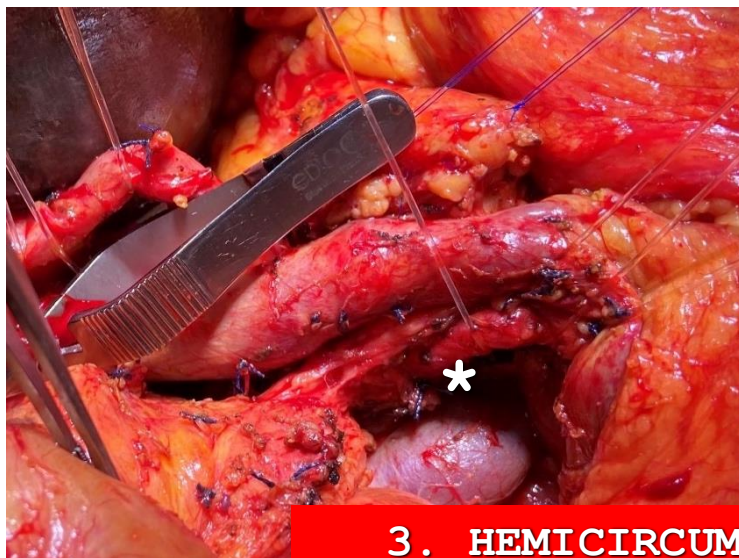
GDA is ligated

Common hepatic artery (CHA)

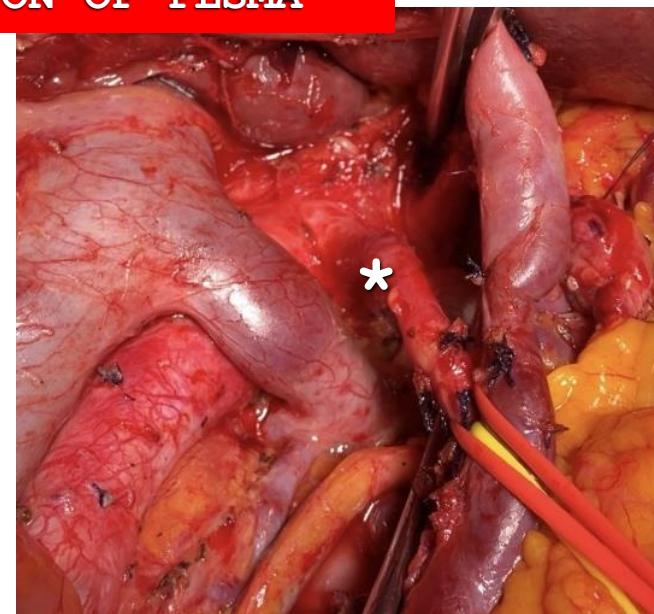
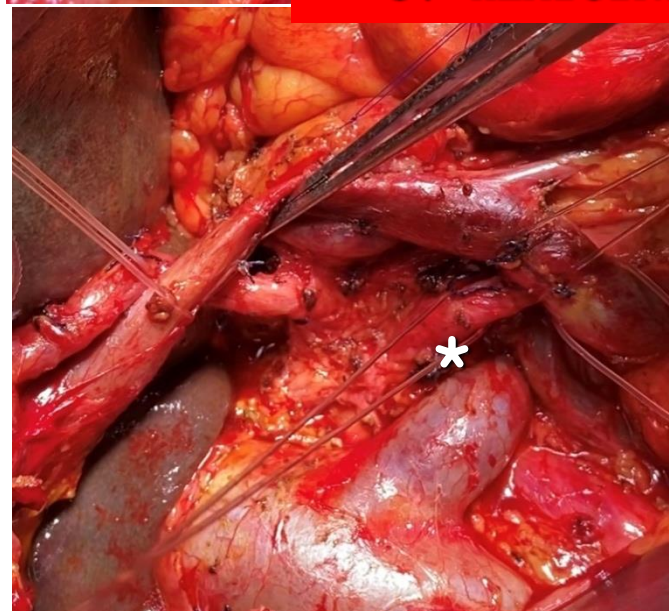
Proper hepatic artery (PHA)

GDA



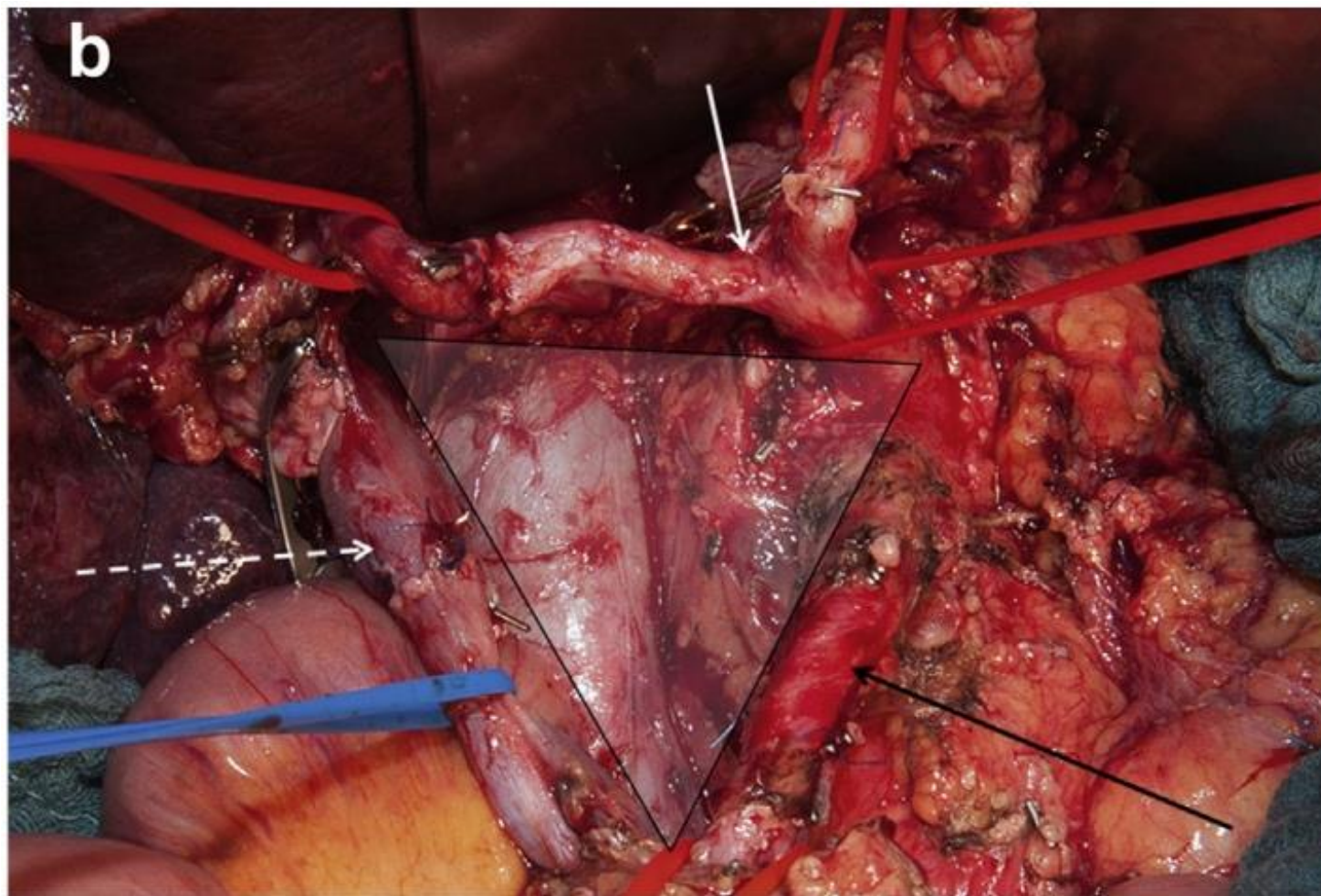


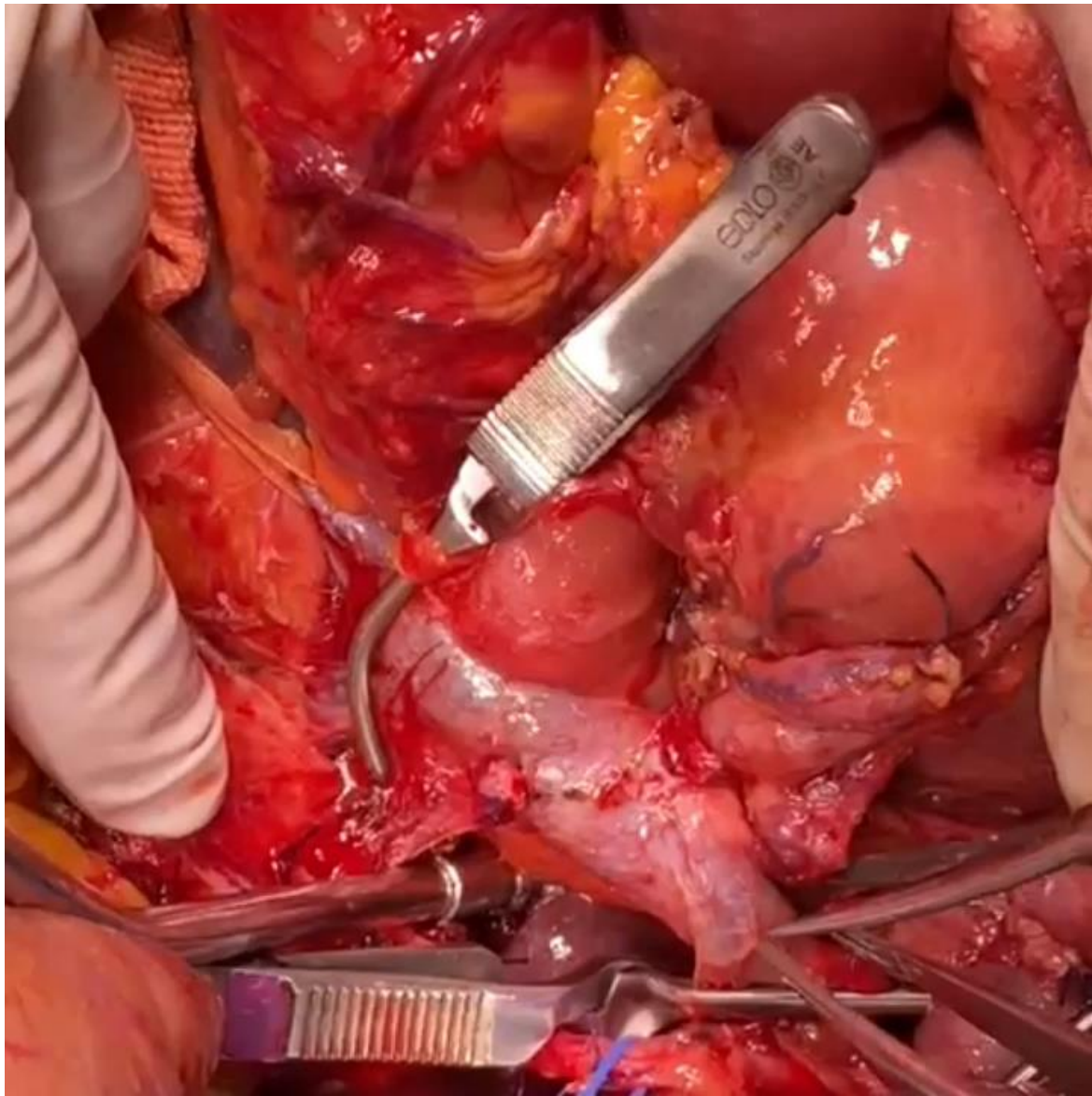
3. HEMICIRCUMFERENTIAL DISECTION OF PL SMA

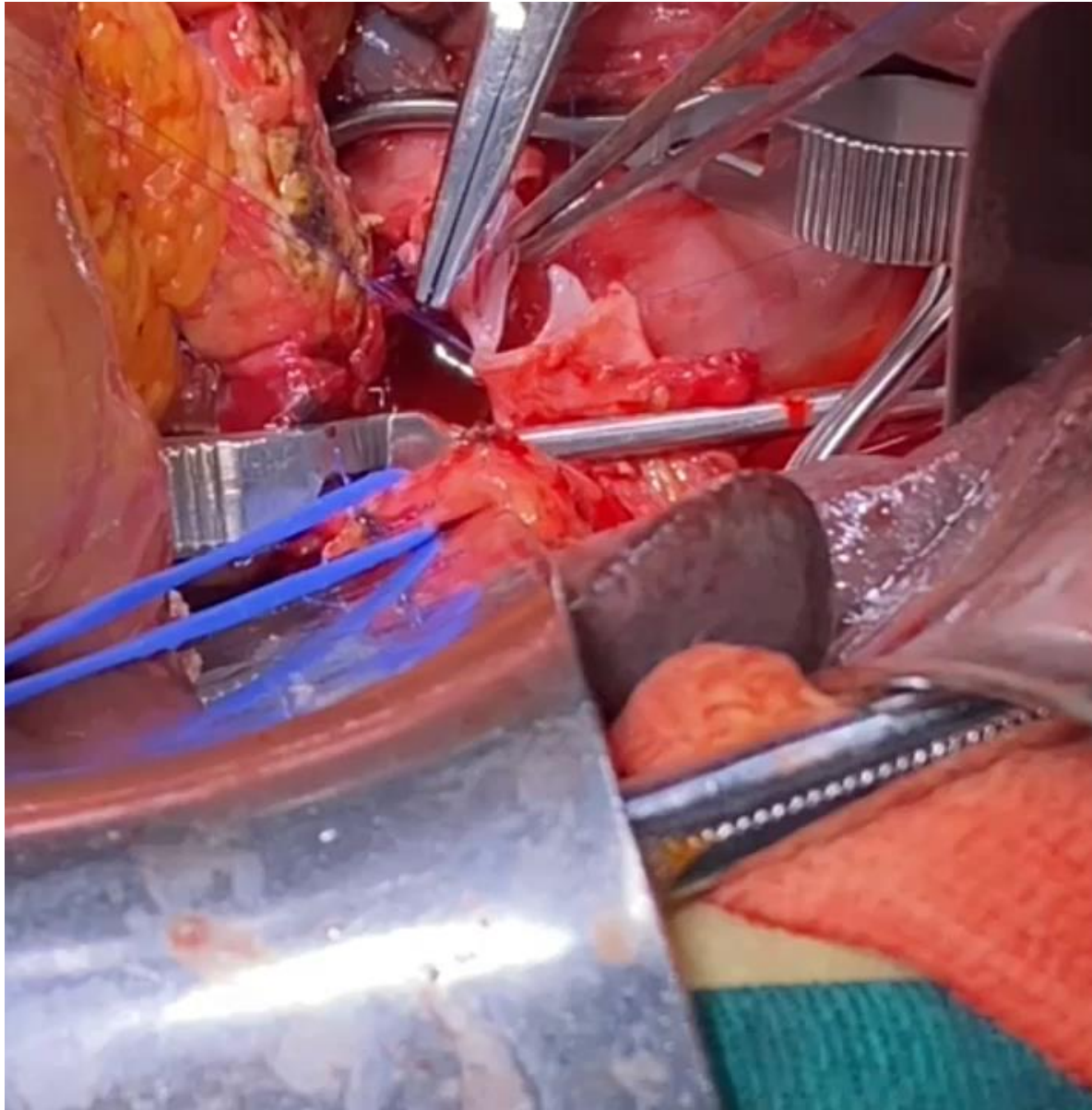


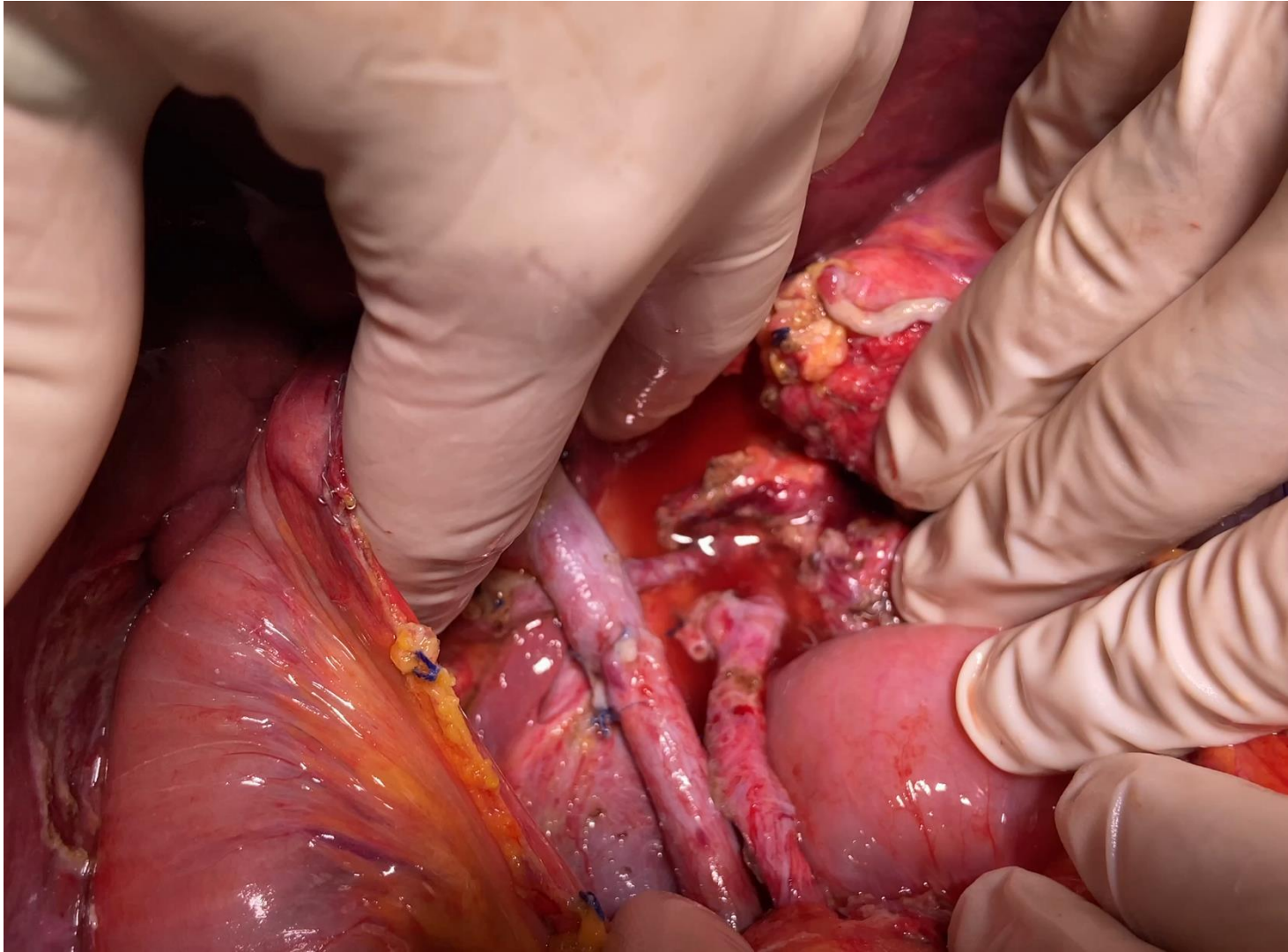
ORIGINAL ARTICLE

The TRIANGLE operation – radical surgery after neoadjuvant treatment for advanced pancreatic cancer: a single arm observational study







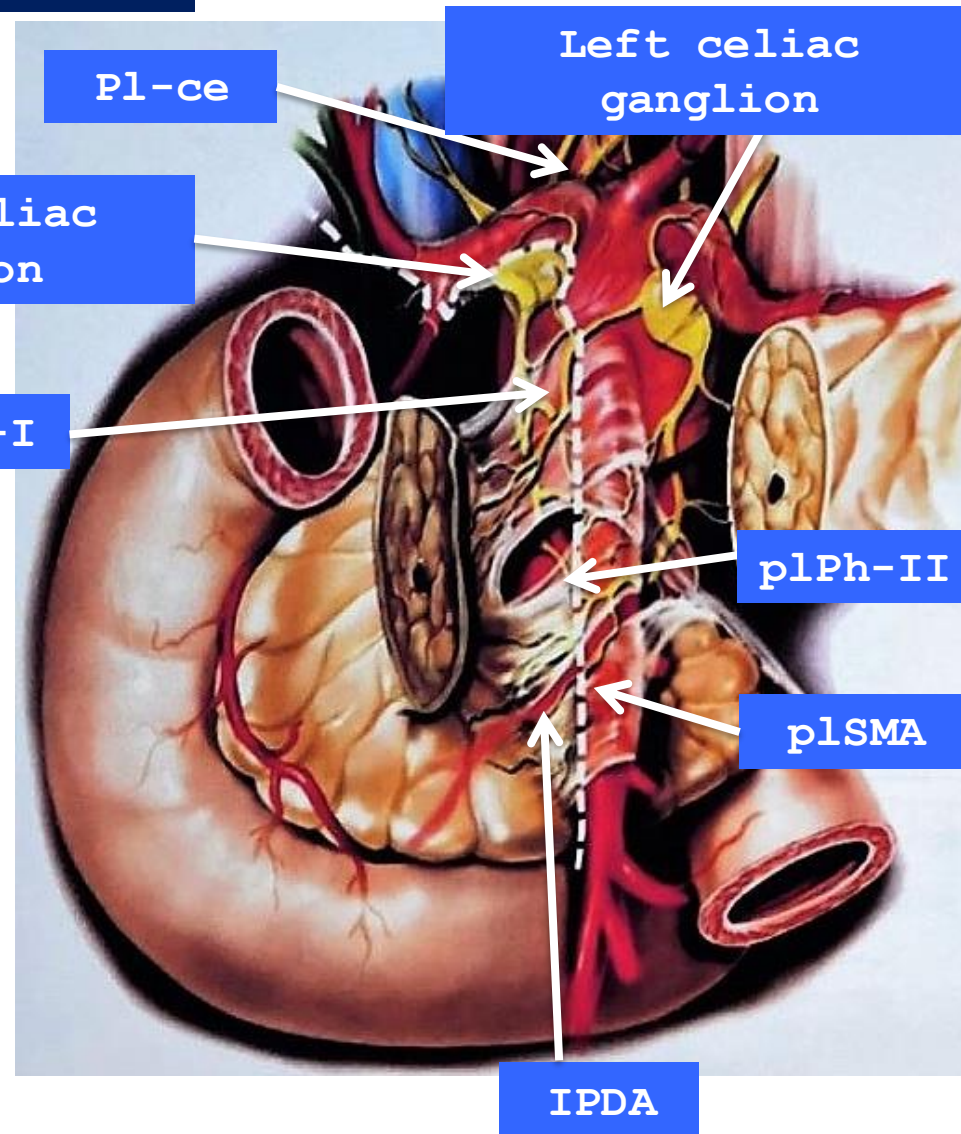


TOTAL MESOPANCREAS EXCISION

- Bleeding
- Pancreatic fistula
- Delayed gastric emptying
- Oncology

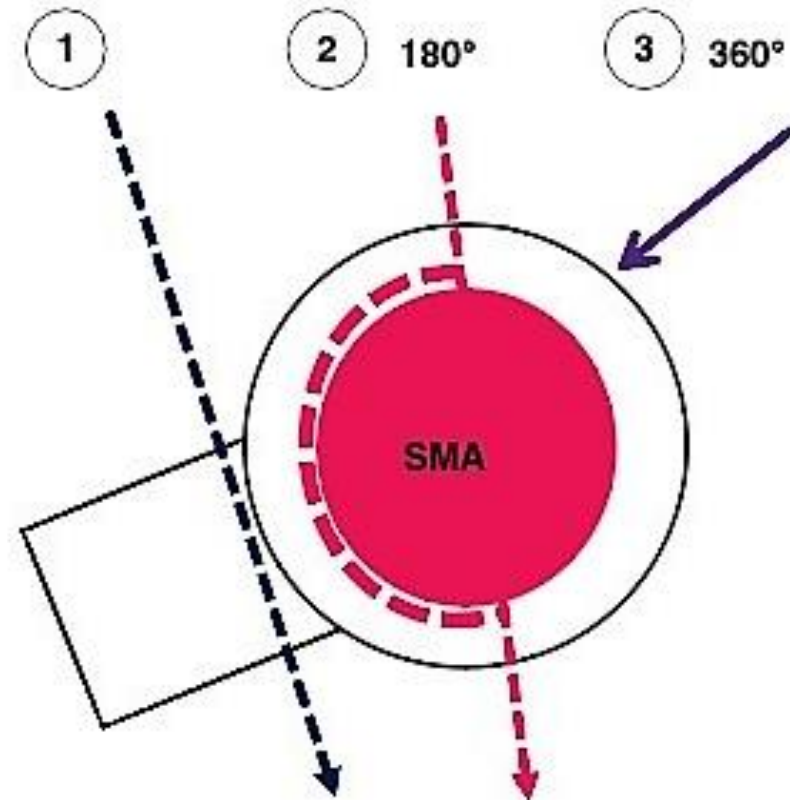
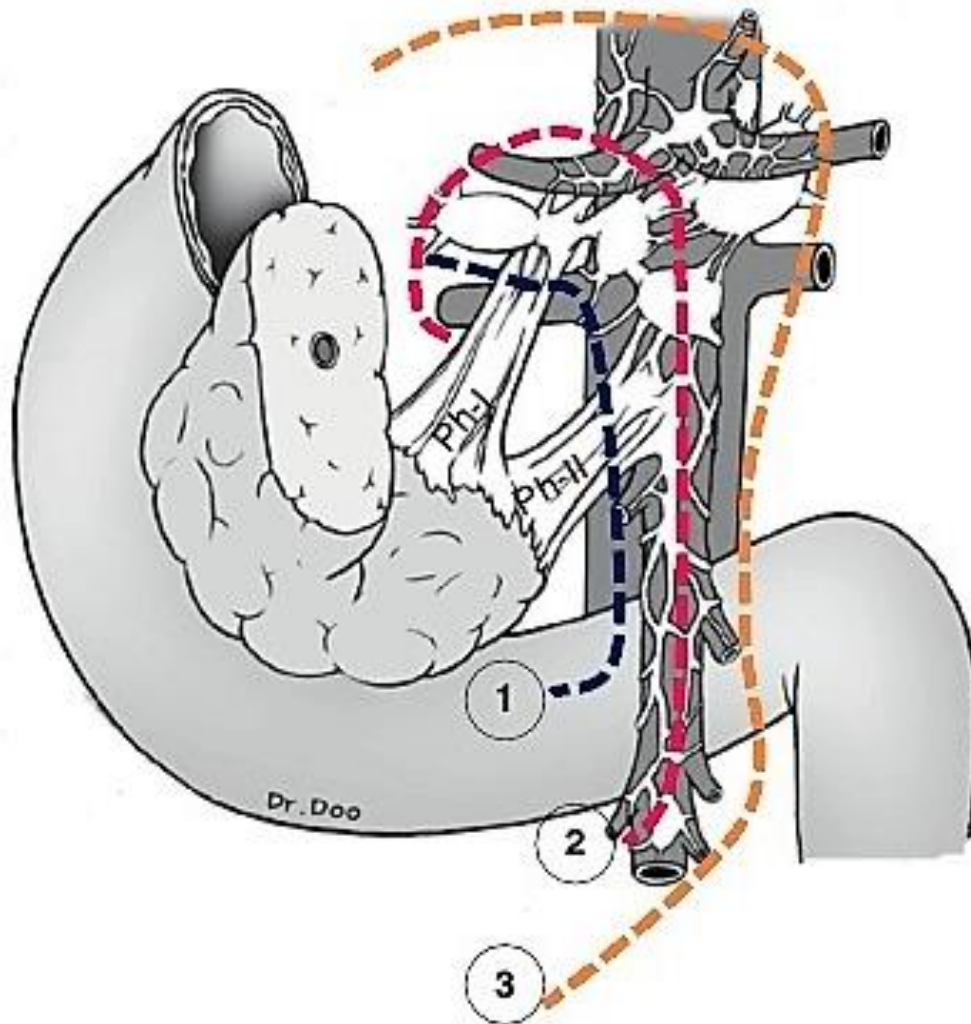
MESOPANCREAS

- p1Ph-I
- p1Ph-II
- IPDA inferior
- Jejunal arteries
- Jejunal veins
- Lymph nodes



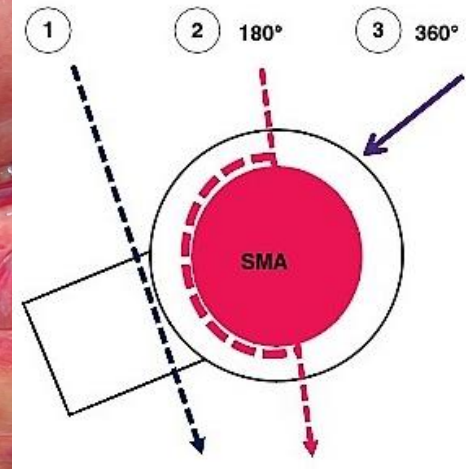
Mesopancreas

Level 2

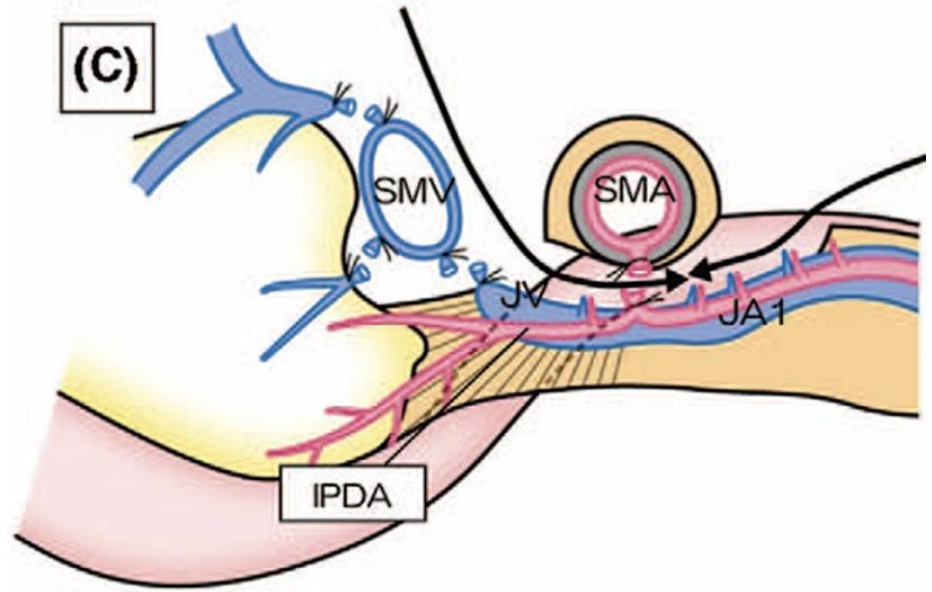
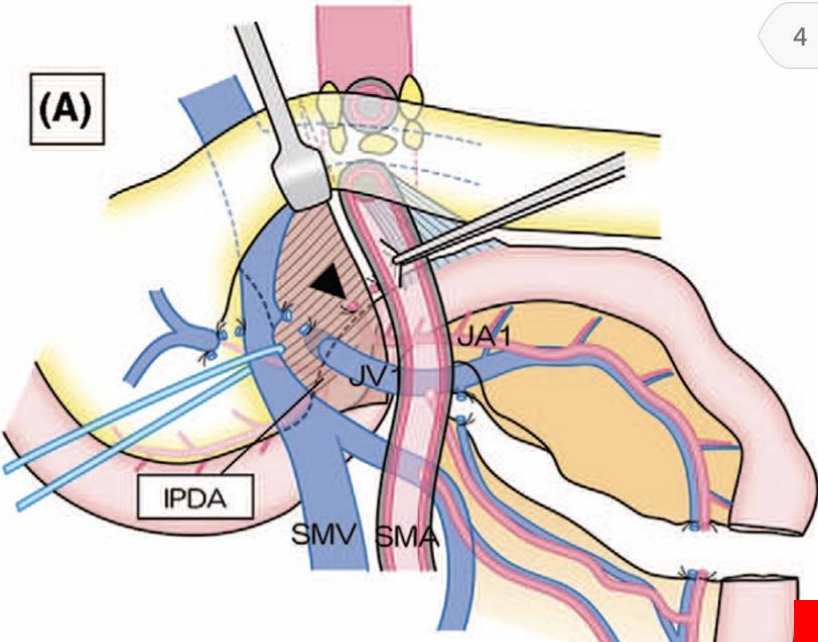


□ Right margin of the SMA

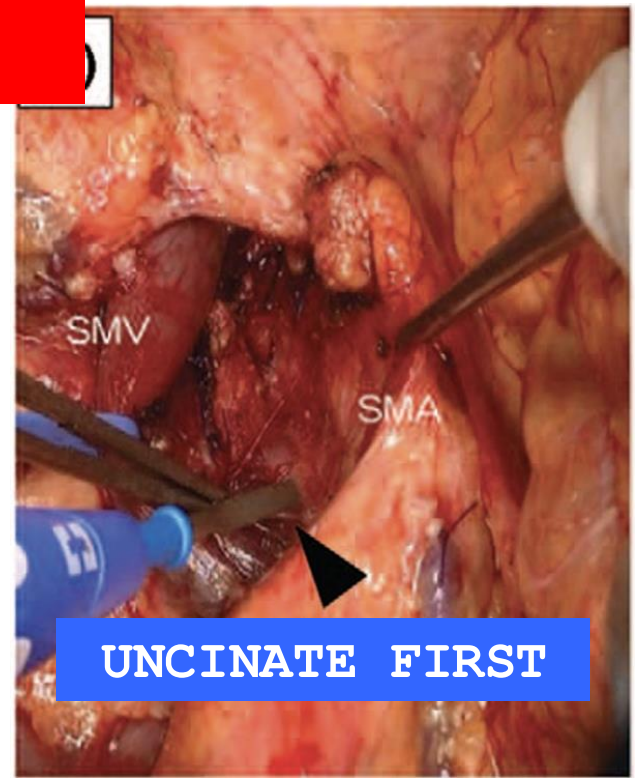
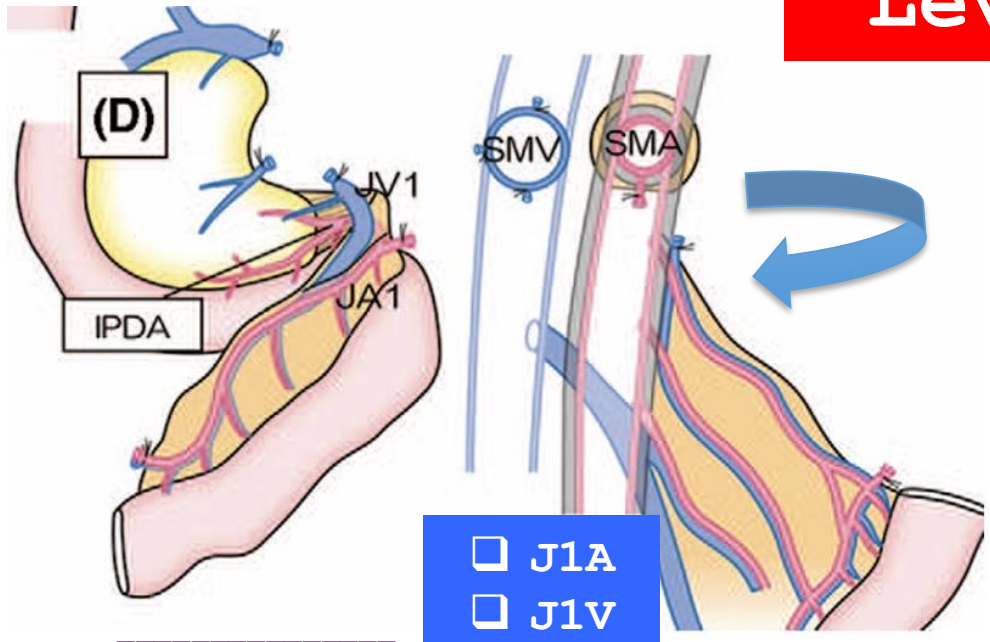
SMA

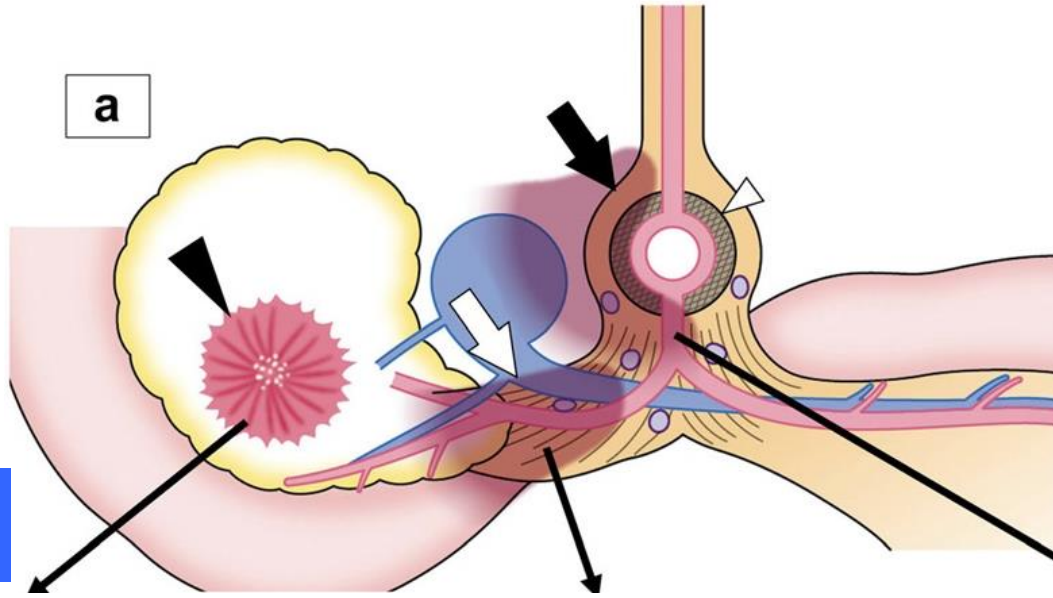


Right margin
(5 o'clock - 11 o'clock)

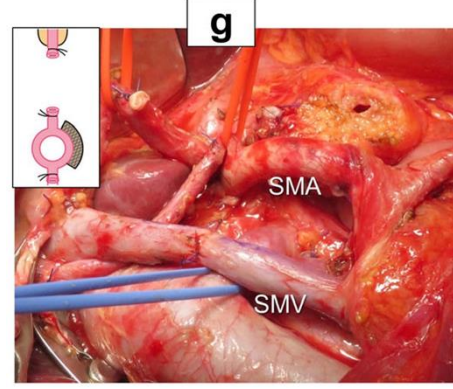
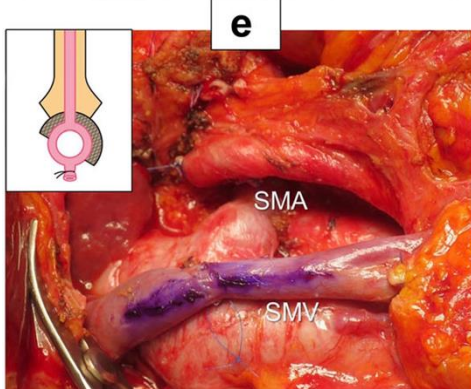
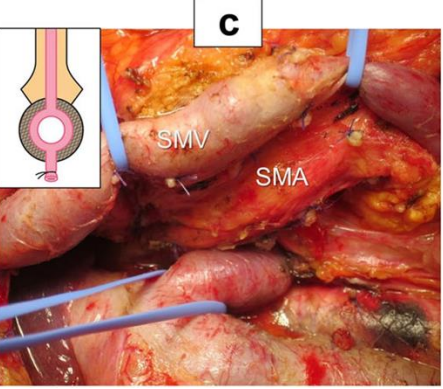
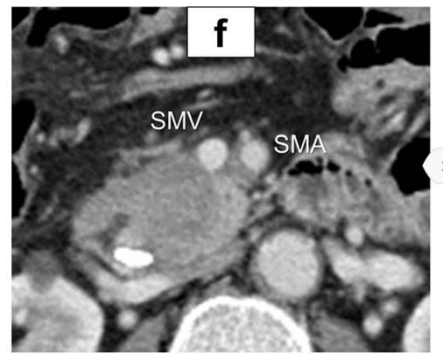
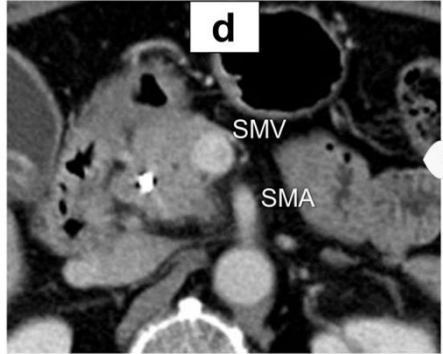
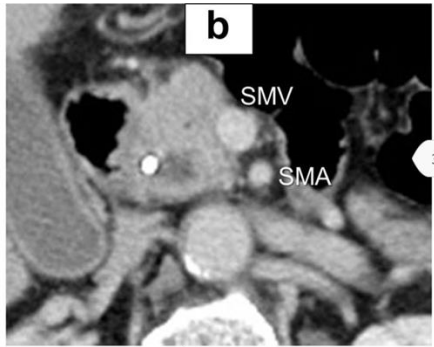


Level 2

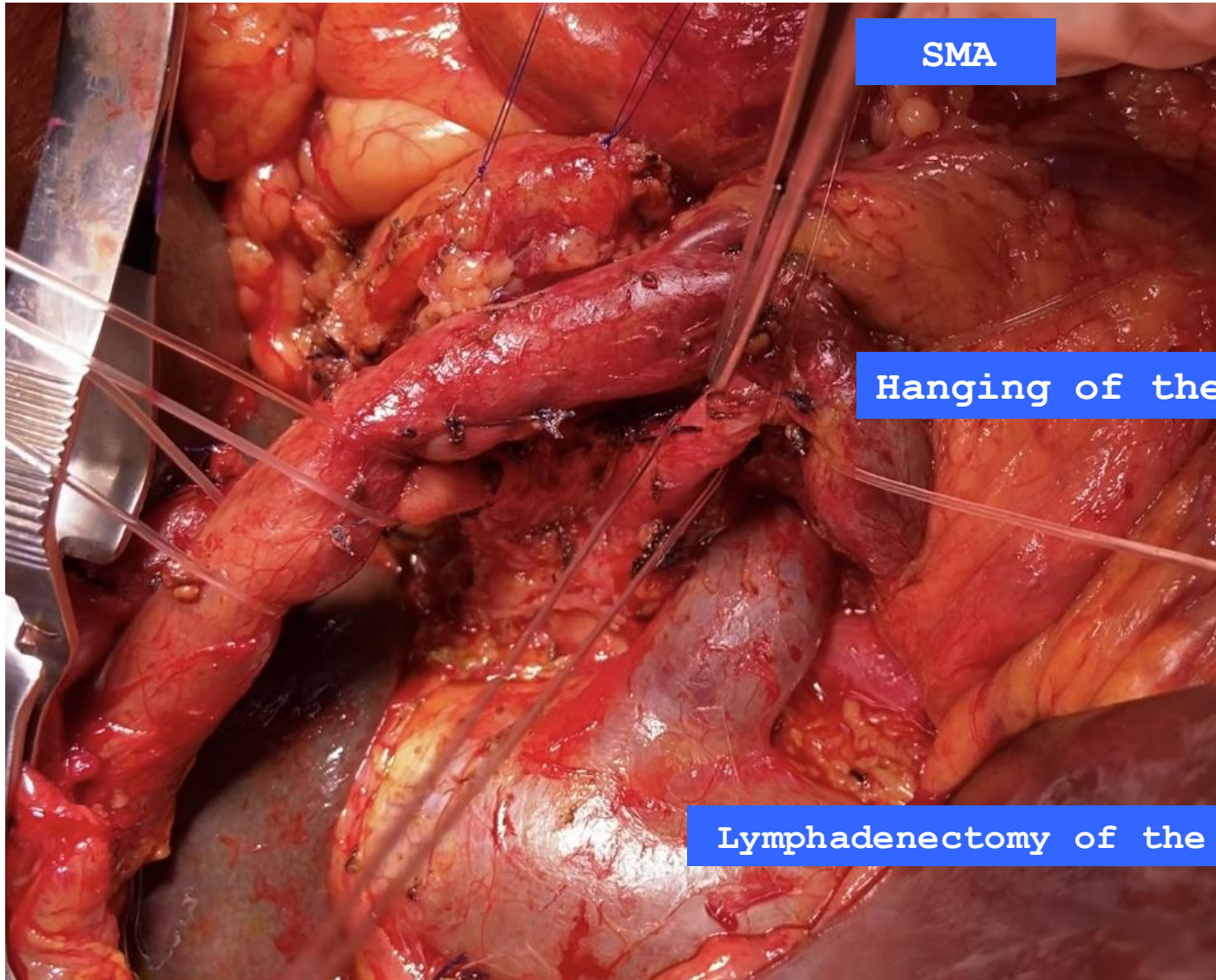




Level 2



MESOPANCREAS



SMA

Hanging of the SMA

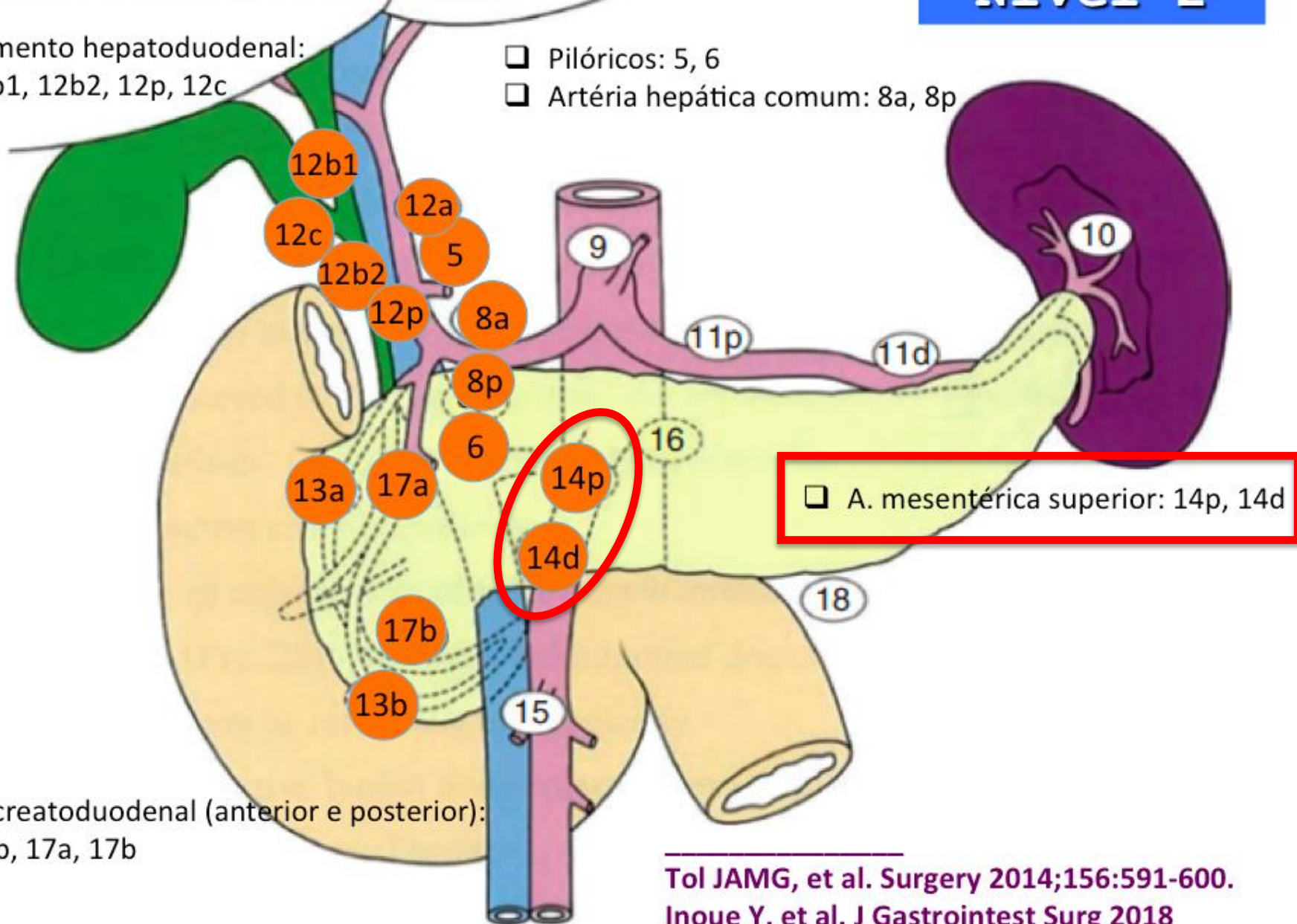
Lymphadenectomy of the SMA

Linfadenectomia

Nível 2

☐ Ligamento hepatoduodenal:
12a, 12b1, 12b2, 12p, 12c

☐ Pilóricos: 5, 6
☐ Artéria hepática comum: 8a, 8p

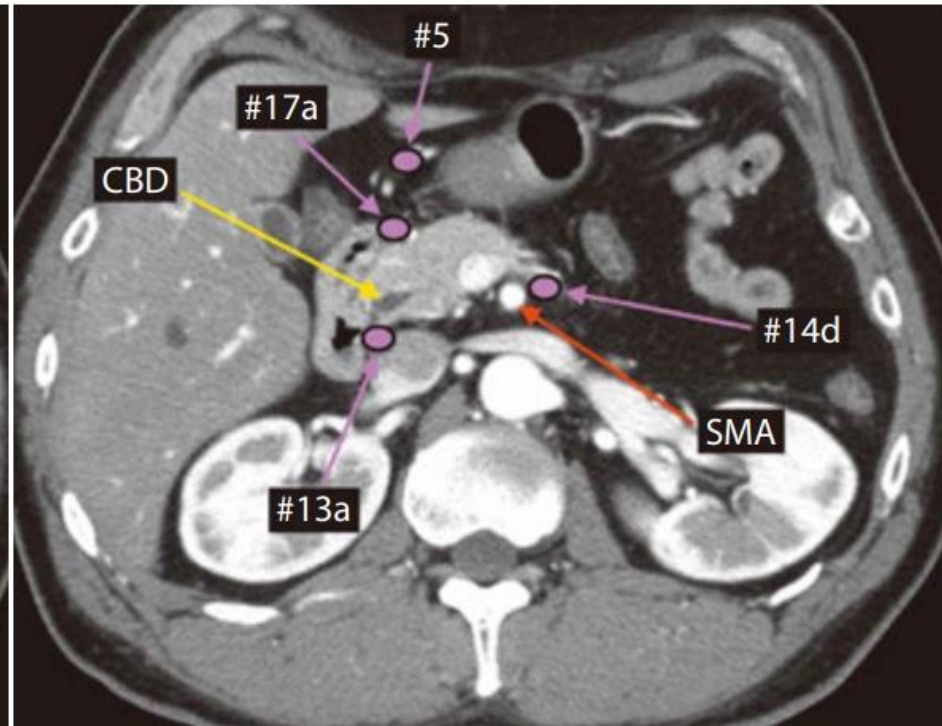
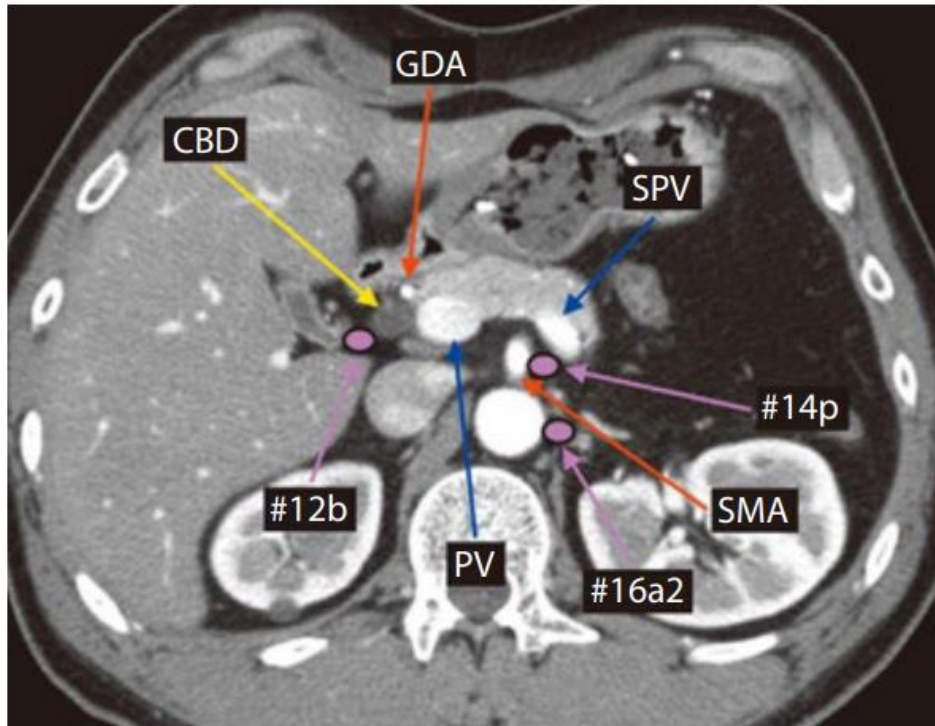


☐ A. mesentérica superior: 14p, 14d

☐ Pancreatoduodenal (anterior e posterior):
13a, 13b, 17a, 17b

Tol JAMG, et al. *Surgery* 2014;156:591-600.
Inoue Y, et al. *J Gastrointest Surg* 2018

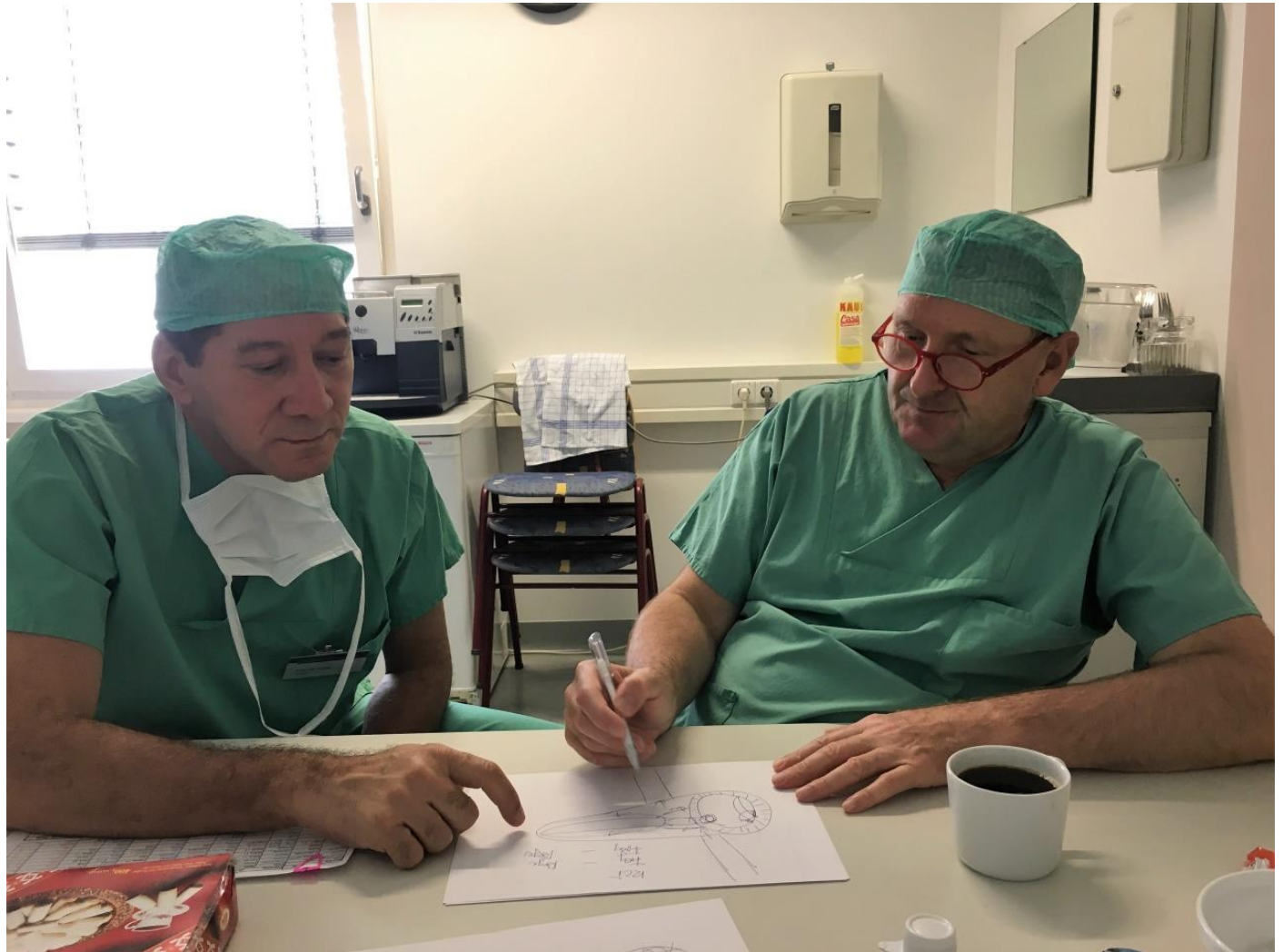LYMPHADENECTOMY



14p, 14d

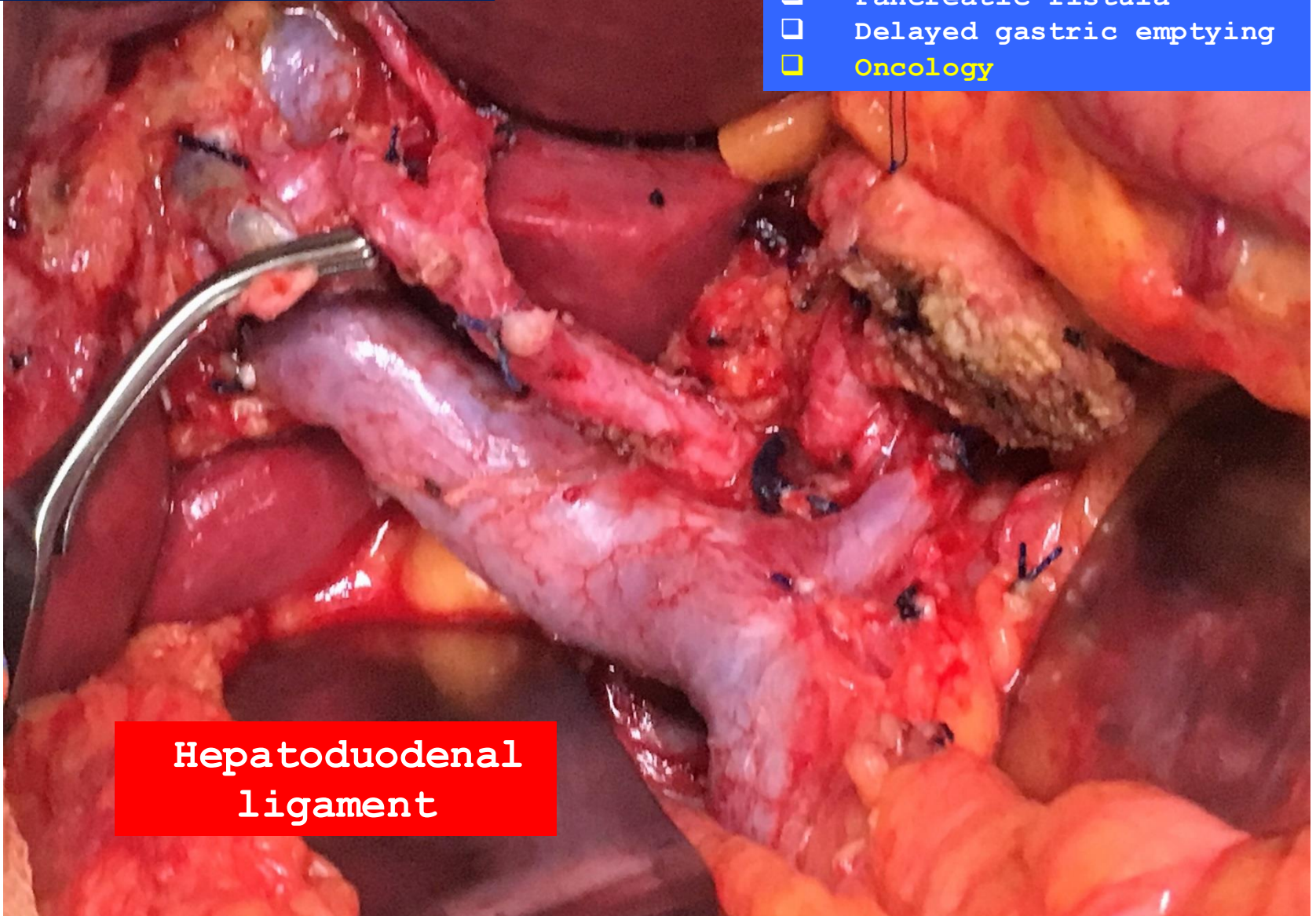
HEIDELBERG

Markus Buchler



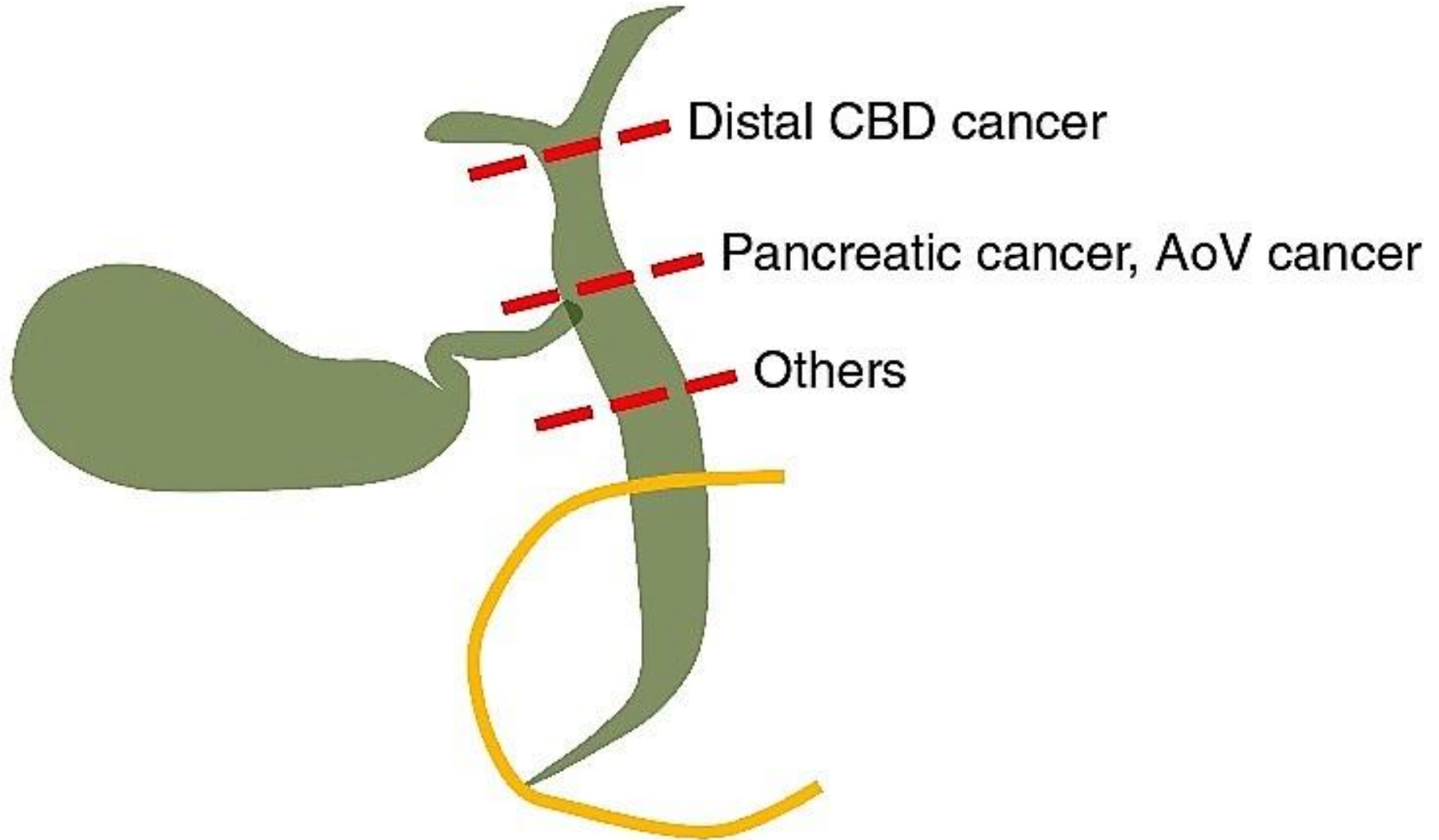
LYMPHADENECTOMY

- Bleeding
- Pancreatic fistula
- Delayed gastric emptying
- Oncology**



Hepatuoduodenal
ligament

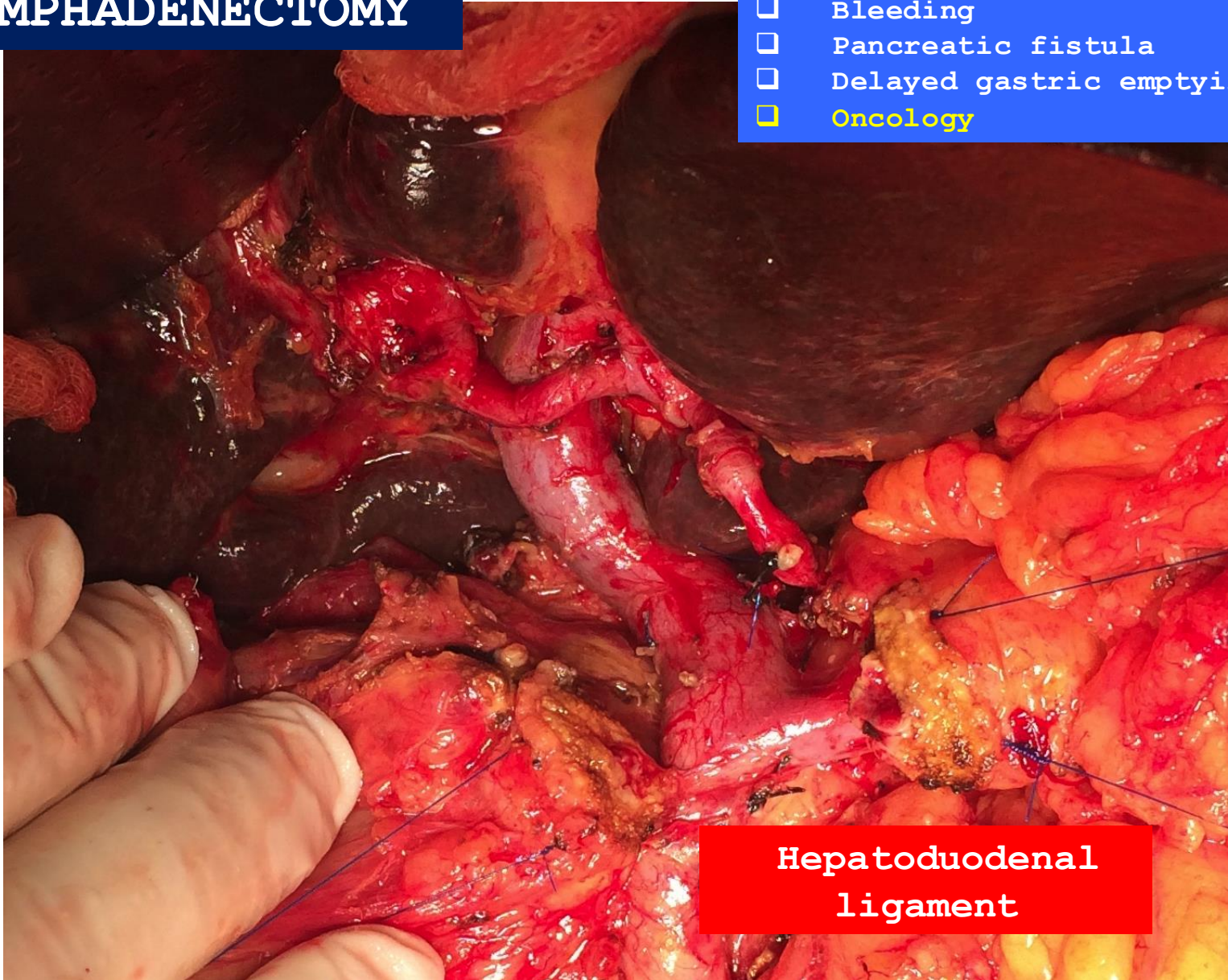
BILE DUCT RESECTION



- Above the cystic duct
- < 2cm of the bifurcation

LYMPHADENECTOMY

- Bleeding
- Pancreatic fistula
- Delayed gastric emptying
- Oncology**



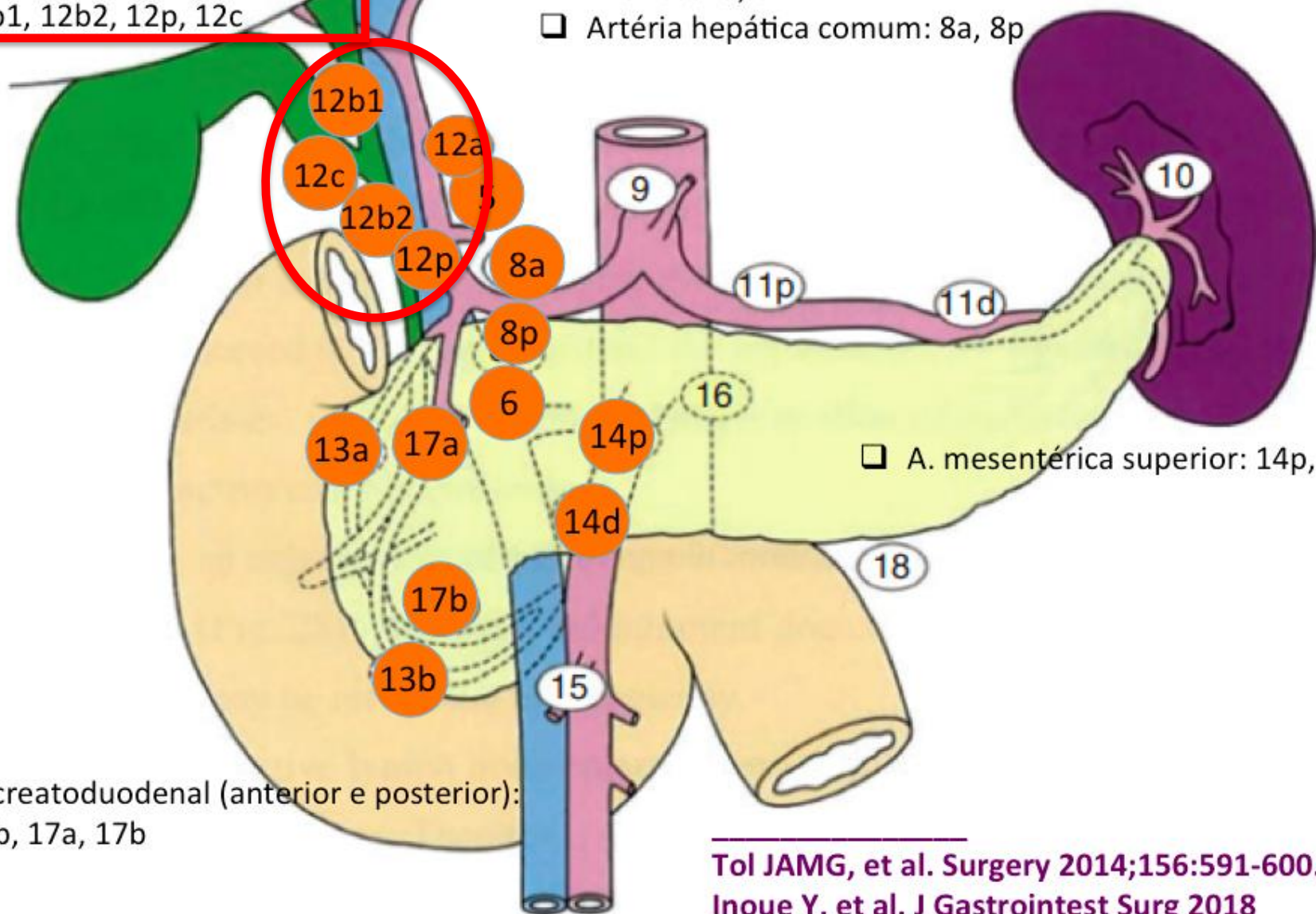
Hepa toduodenal
ligament

Linfadenectomia

Nível 2

☐ Ligamento hepatoduodenal:
12a, 12b1, 12b2, 12p, 12c

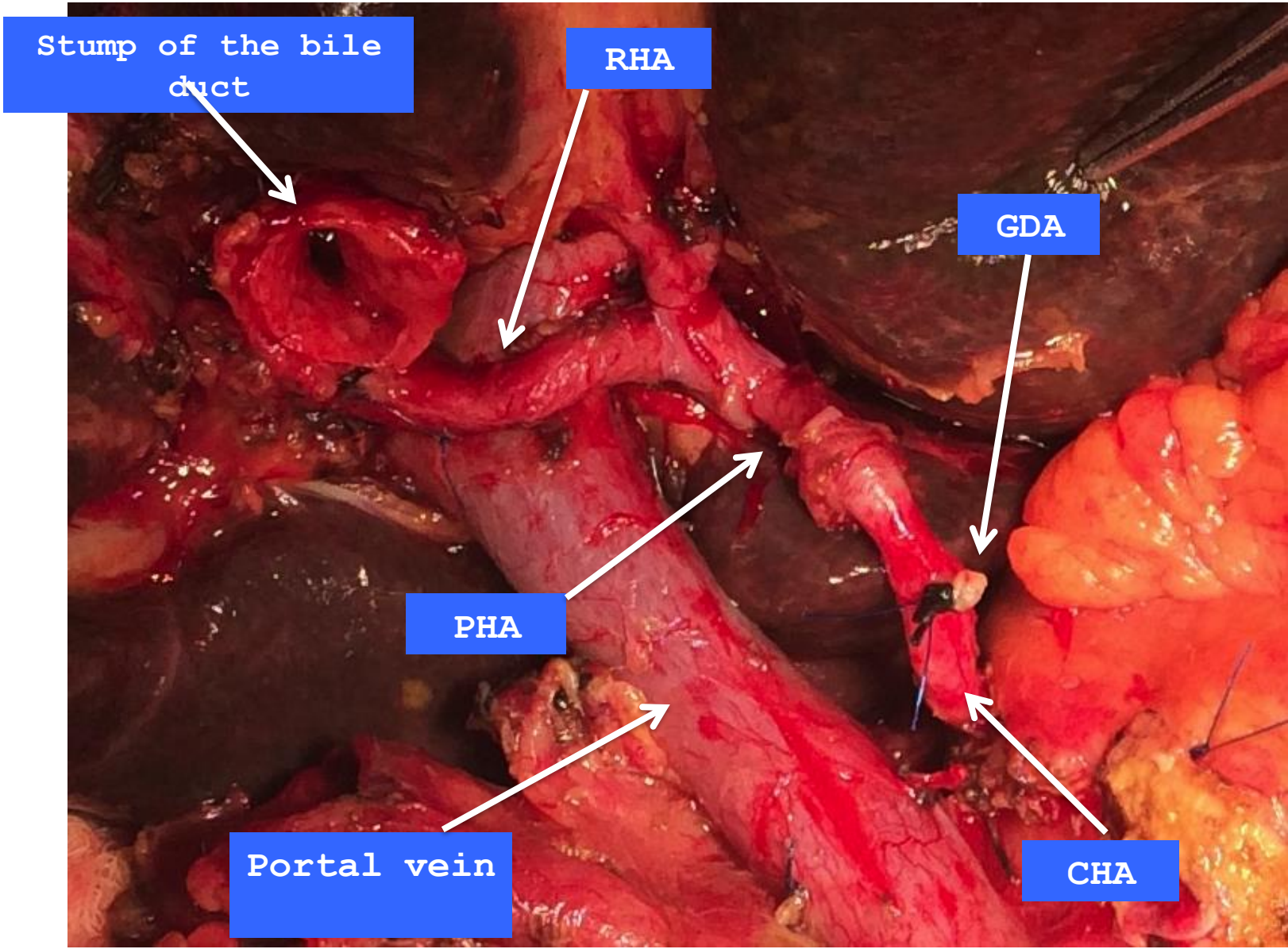
☐ Pilóricos: 5, 6
☐ Artéria hepática comum: 8a, 8p



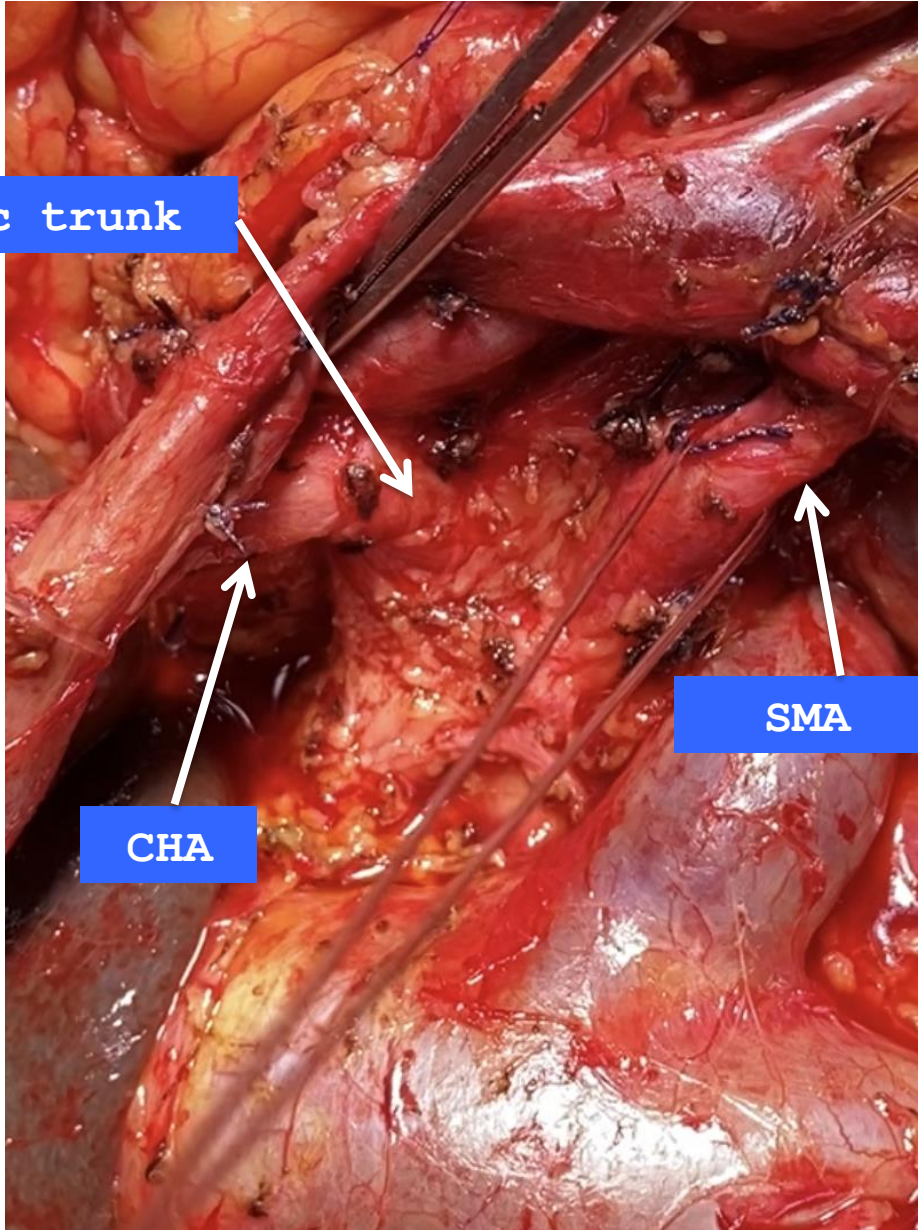
☐ A. mesentérica superior: 14p, 14d

☐ Pancreatoduodenal (anterior e posterior):
13a, 13b, 17a, 17b

Tol JAMG, et al. Surgery 2014;156:591-600.
Inoue Y, et al. J Gastrointest Surg 2018



Celiac trunk



SMA

CHA

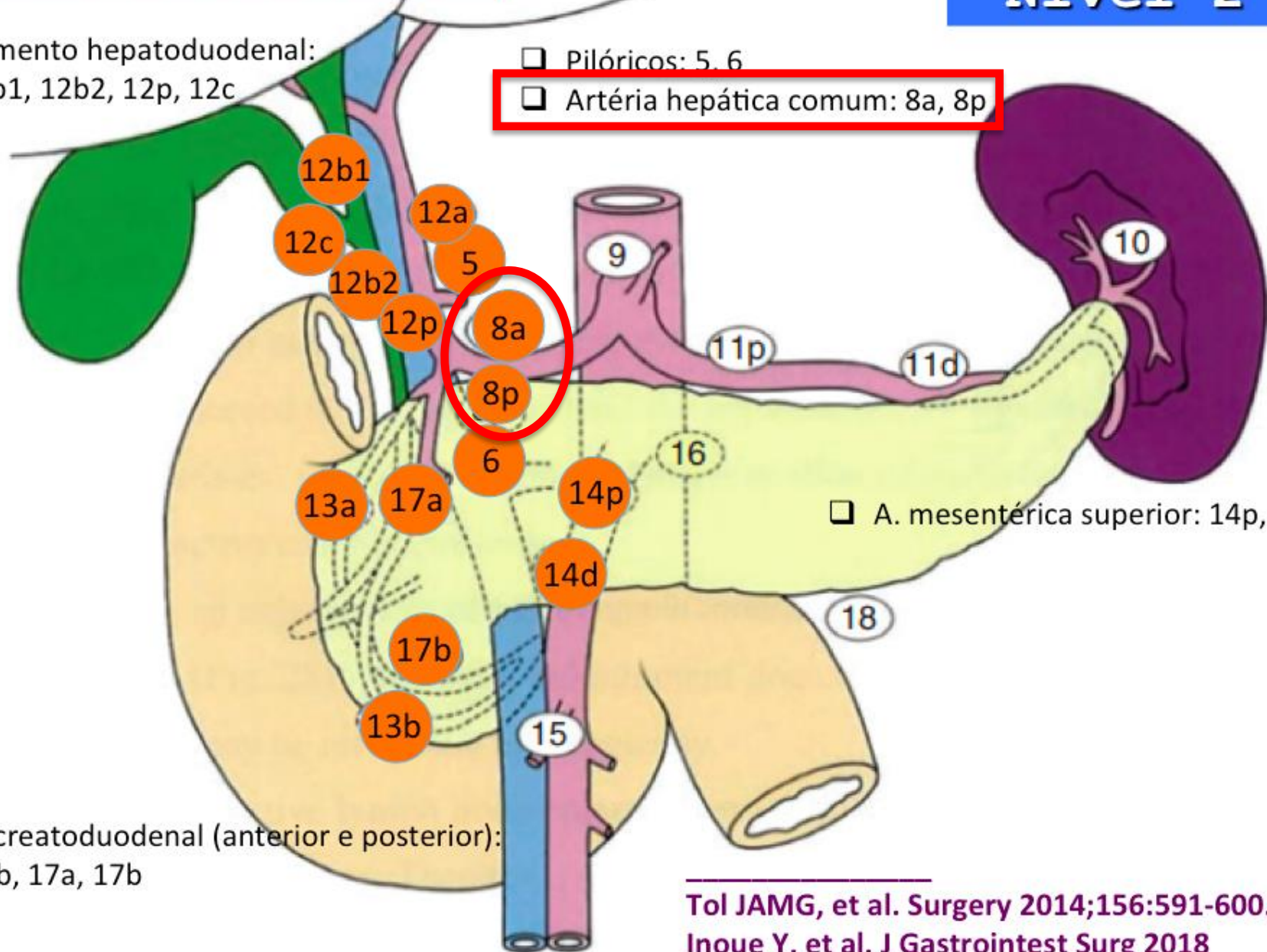
Linfadenectomia

Nível 2

☐ Ligamento hepatoduodenal:
12a, 12b1, 12b2, 12p, 12c

☐ Pilóricos: 5, 6

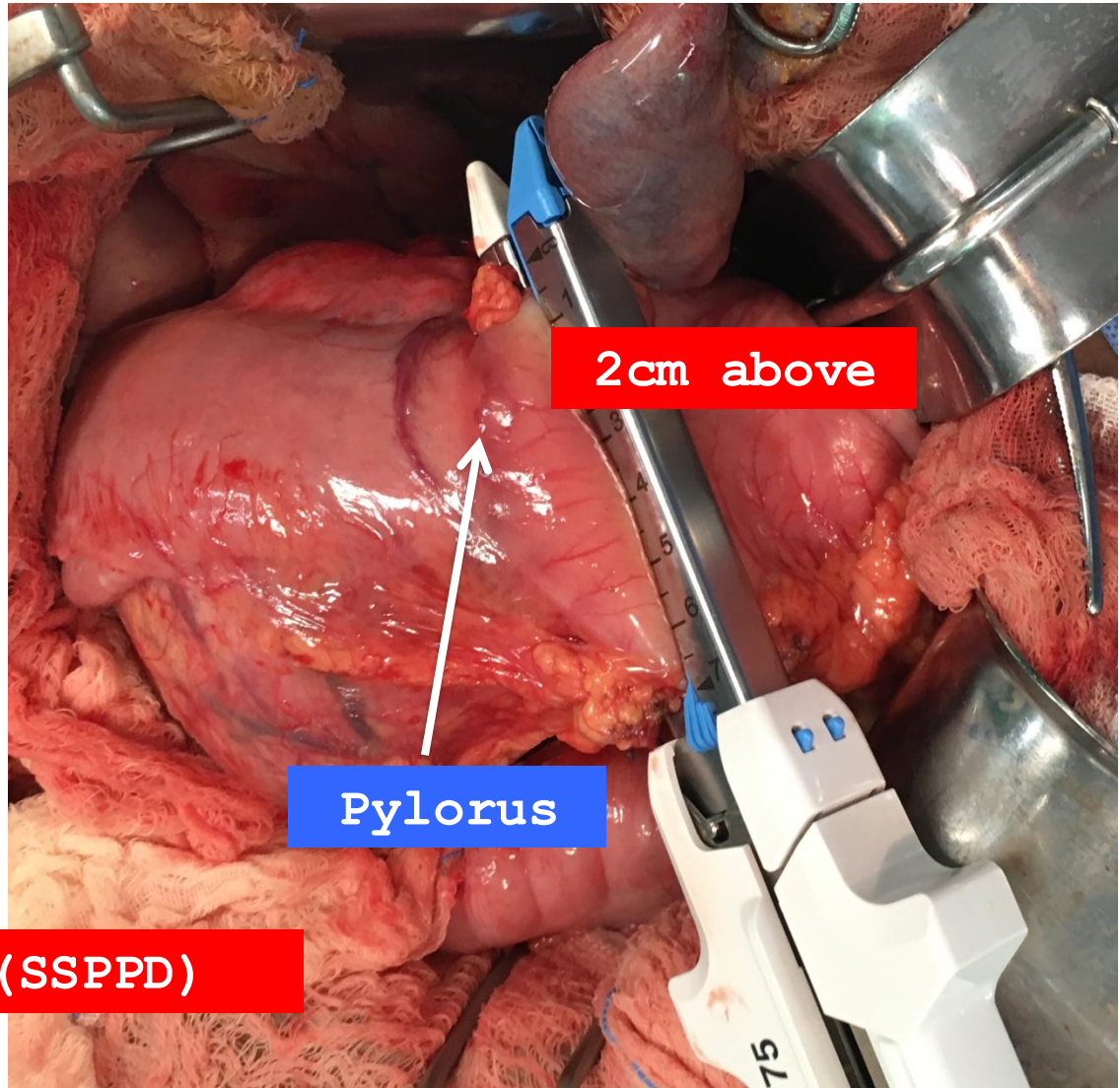
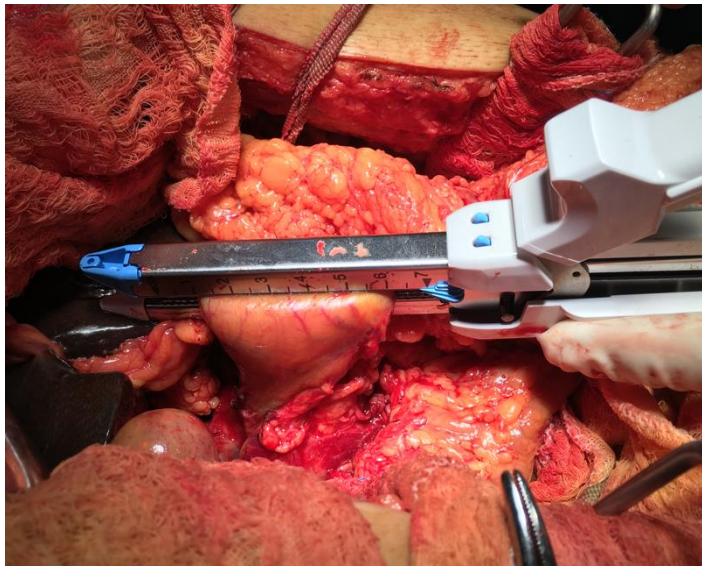☐ Artéria hepática comum: 8a, 8p



☐ A. mesentérica superior: 14p, 14d

☐ Pancreatoduodenal (anterior e posterior):
13a, 13b, 17a, 17b

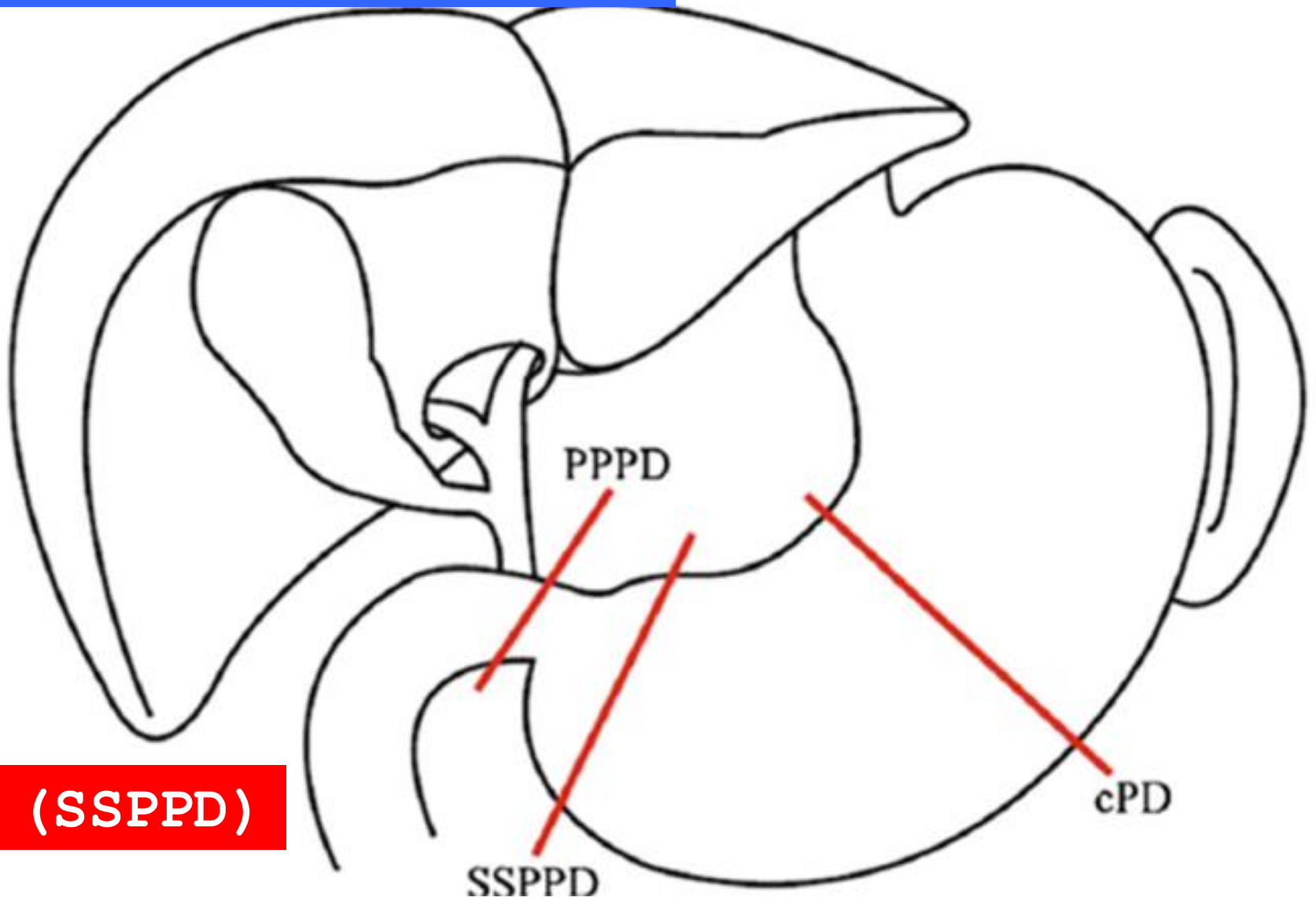
GASTRIC TRANSECTION



- Bleeding
- Pancreatic fistula
- Delayed gastric emptying
- Oncology

Stomach preserving (SSPPD)

Gastric transection



□ (SSPPD)

PANCREATODUODENECTOMY: BRAZILIAN PRACTICE PATTERNS*

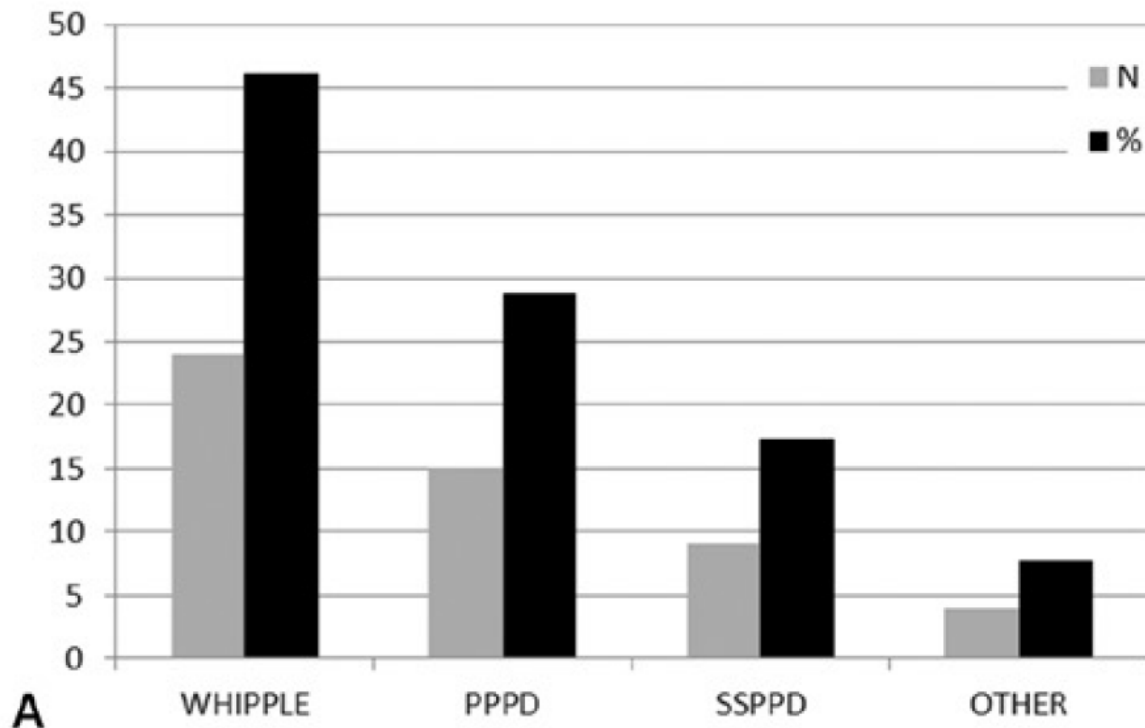
*Duodenopancreatectomia: prática padrão do Brasil**

Orlando Jorge M **TORRES**¹, Eduardo de Souza M **FERNANDES**², Rodrigo Rodrigues **VASQUES**¹, Fabio Luís **WAECHTER**³, Paulo Cezar G. **AMARAL**⁴, Marcelo Bruno de **REZENDE**⁵, Roland Montenegro **COSTA**⁶, André Luís **MONTAGNINI**⁷

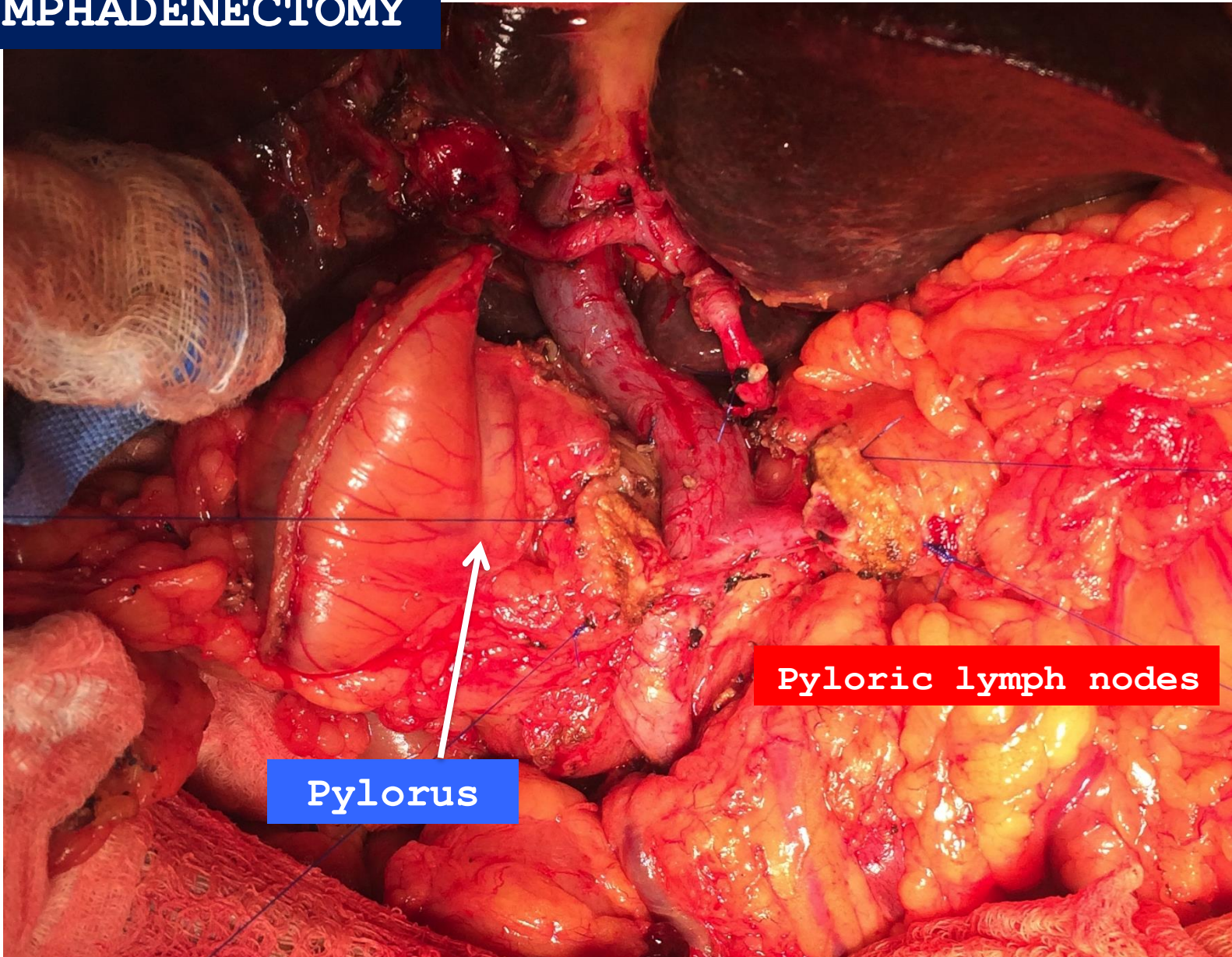
From the ¹Departamento de Cirurgia, Universidade Federal do Maranhão, São Luís, MA; ²Universidade Federal do Rio de Janeiro, Rio de Janeiro, RJ; ³Santa Casa de Misericórdia de Porto Alegre, Porto Alegre, RS; ⁴Hospital São Rafael, Salvador, BA; ⁵Hospital Santa Marcelina, São Paulo, SP; ⁶Hospital Santa Lucia,

ABSTRACT - Background: Pancreatoduodenectomy is a technically challenging surgical procedure with an incidence of postoperative complications ranging from 30% to 61%. The procedure requires a high level of experience, and to minimize surgery-related complications and mortality, a high-quality standard surgery is imperative. **Aim:** To understand the Brazilian practice patterns for pancreatoduodenectomy. **Method:** A questionnaire was designed

RESECTION



LYMPHADENECTOMY



Pylorus

Pyloric lymph nodes

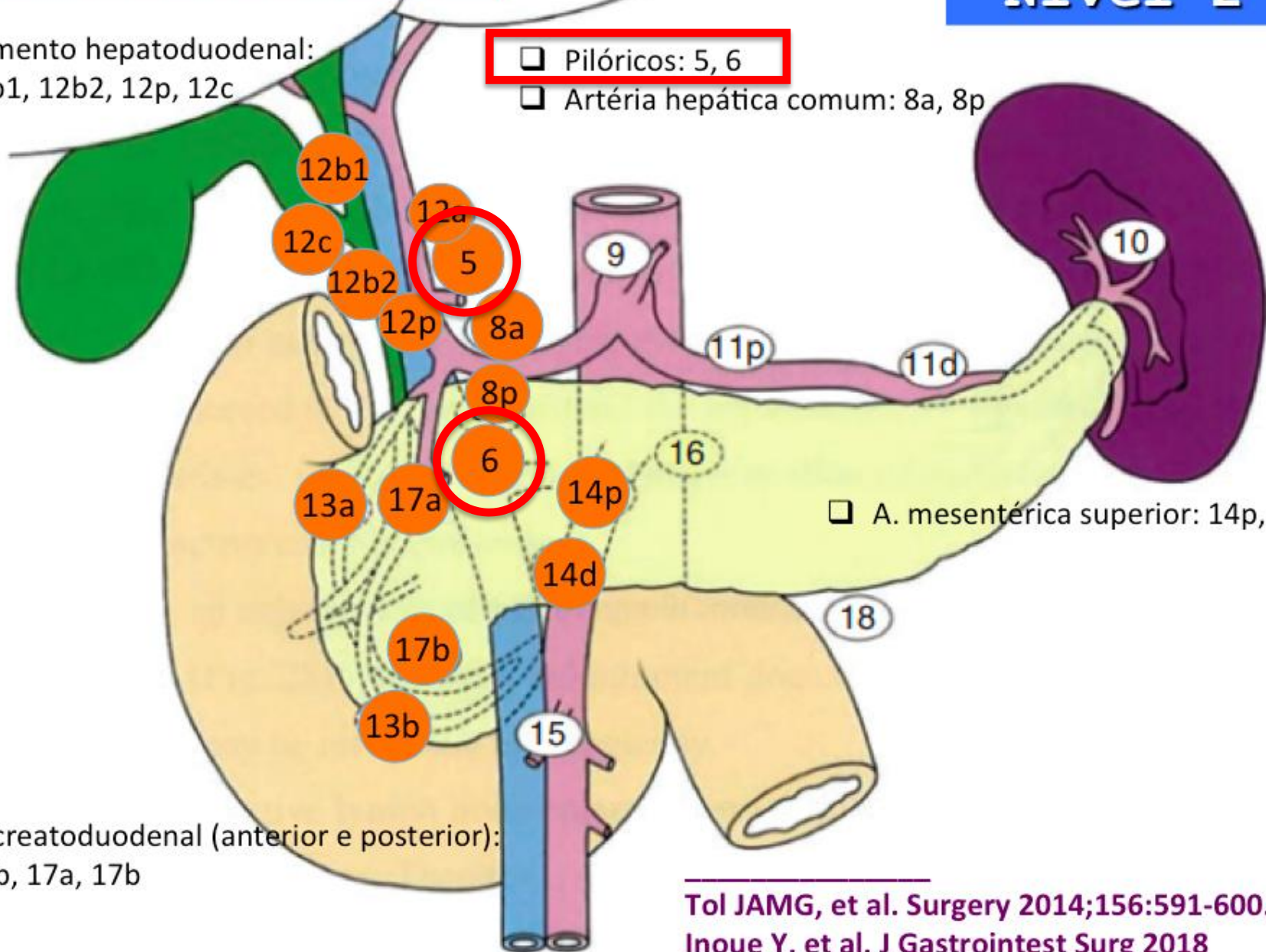
Linfadenectomia

Nível 2

☐ Ligamento hepatoduodenal:
12a, 12b1, 12b2, 12p, 12c

☐ Pilóricos: 5, 6

☐ Artéria hepática comum: 8a, 8p



☐ A. mesentérica superior: 14p, 14d

☐ Pancreatoduodenal (anterior e posterior):
13a, 13b, 17a, 17b

Tol JAMG, et al. Surgery 2014;156:591-600.
Inoue Y, et al. J Gastrointest Surg 2018

THE OBITUARY OF THE PYLORUS-PRESERVING PANCREATODUODENECTOMY

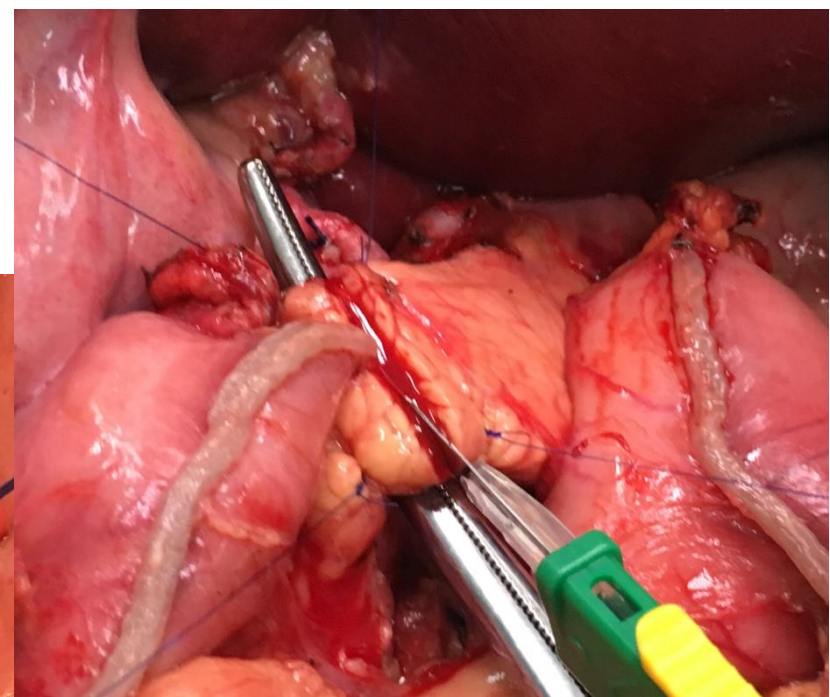
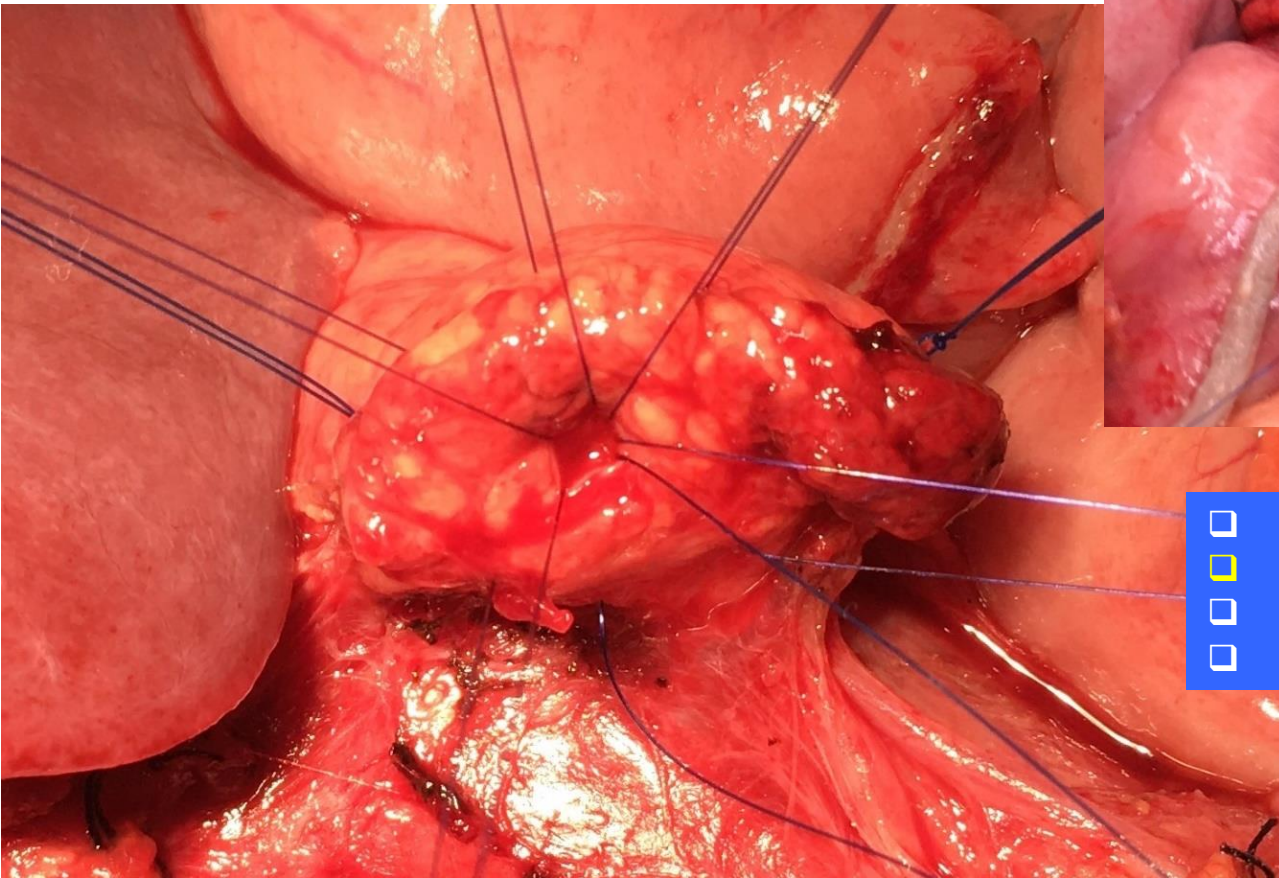
O obituário da duodenopancreatectomia com preservação pilórica

Orlando Jorge Martins TORRES, Rodrigo Rodrigues VASQUES, Camila Cristina S. TORRES
From the Department of Surgery, Federal University of Maranhão, São Luiz, MA, Brazil

Pancreatoduodenectomy is the treatment of choice for patients with benign and malignant disease of pancreatic head. Classic pancreatoduodenectomy was described by Whipple originally and included distal hemigastrectomy. Pylorus-preserving pancreatoduodenectomy (pylorus-preserving) was popularized in the late 1970s for benign disease and it included full preservation of the pylorus. However, delayed gastric emptying after pylorus-preserving is a frustrating complication. Its incidence varying from 19% to 61% in previous series and it results in discomfort, prolonged length of stay and increases the risk of respiratory complications. Delayed gastric emptying contributes to increased hospital costs and decreased quality of life. There has been no evidence from prospective studies and meta-analyses to indicate the superiority of pylorus preserving in terms of quality of life or delayed gastric emptying^{2,4,5,7}.

More recently, and mostly in Japan since the late 1990s, subtotal stomach-preserving pancreatoduodenectomy (stomach-

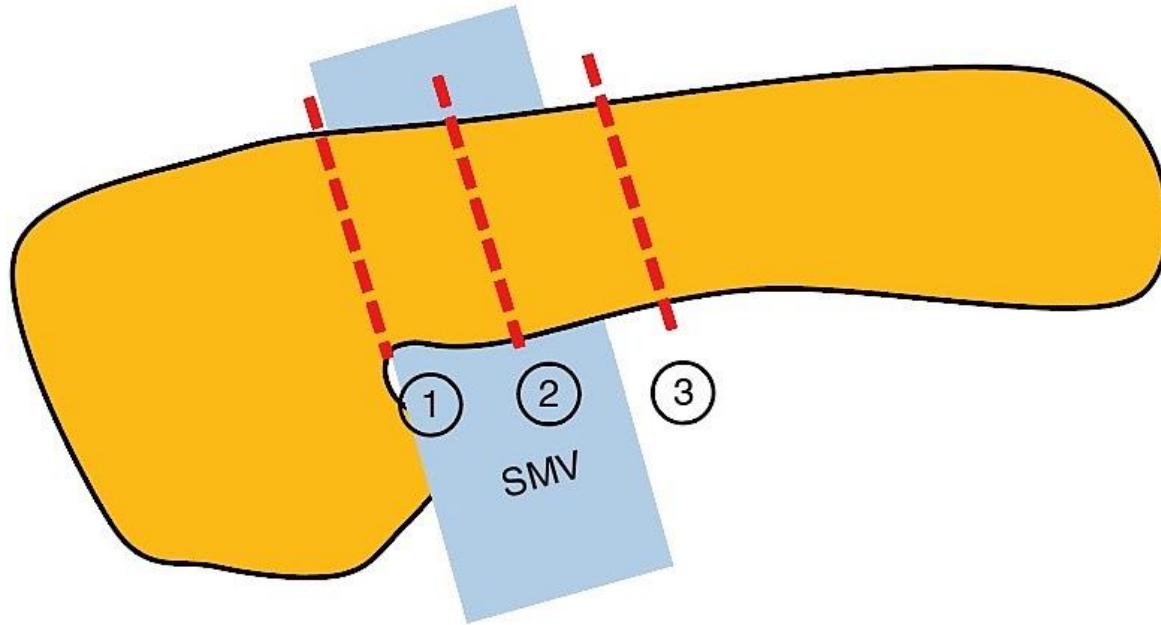
PANCREAS TRANSECTION



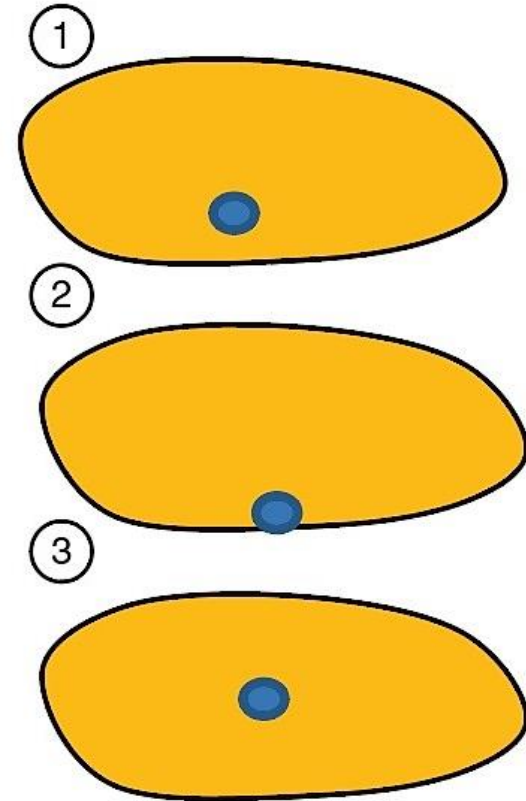
- Bleeding
- Pancreatic fistula**
- Delayed gastric emptying
- Oncology

PANCREAS TRANSECTION

- Bleeding
- Pancreatic fistula
- Delayed gastric emptying
- Oncology

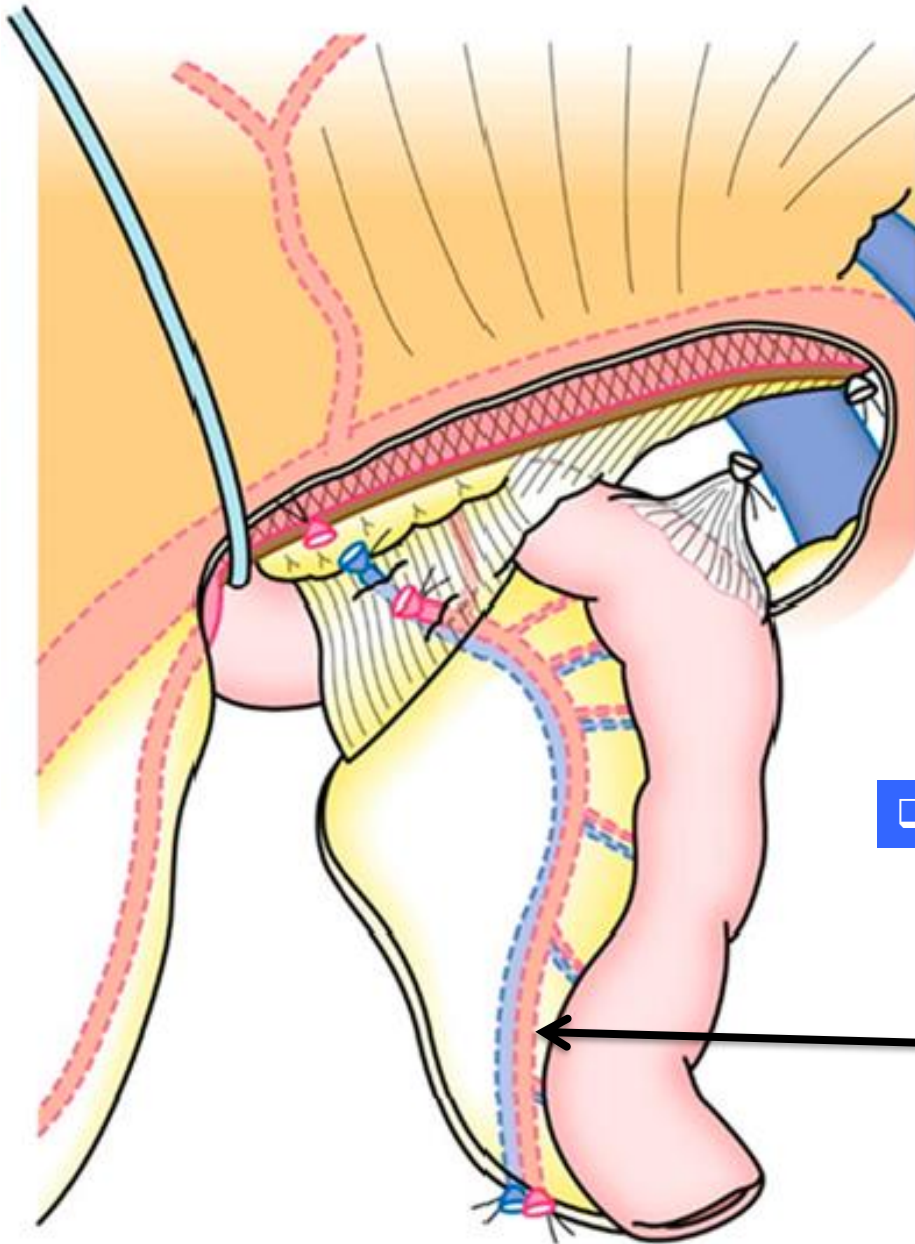


c



- Left side of the portal vein

TREITZ LIGAMENT

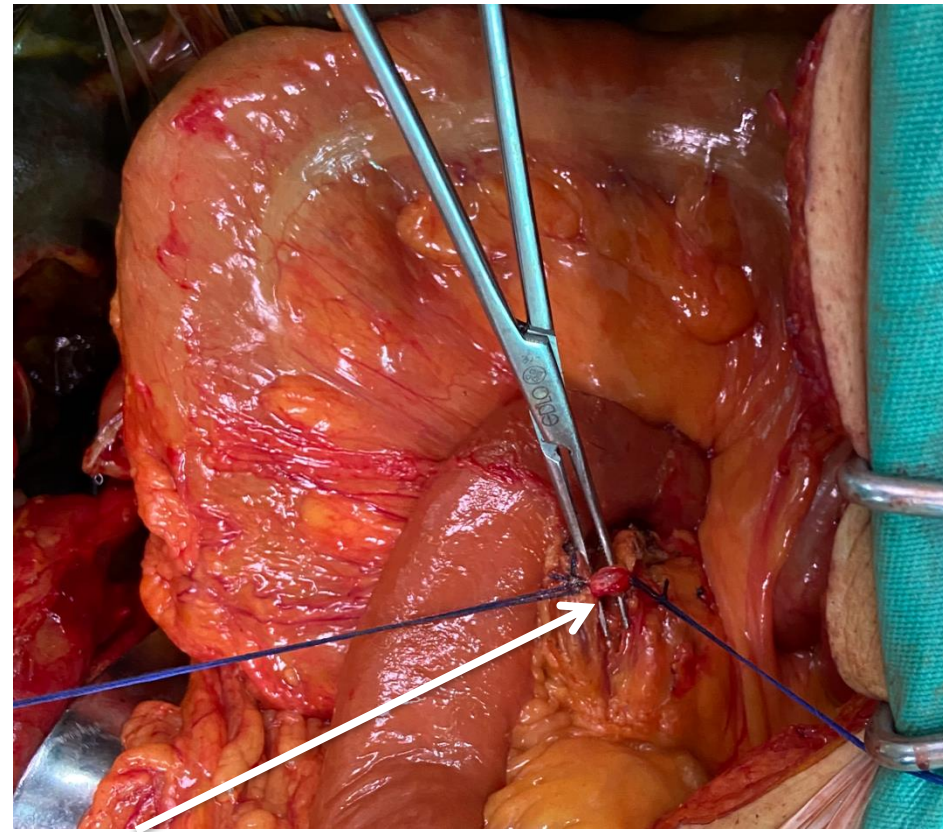
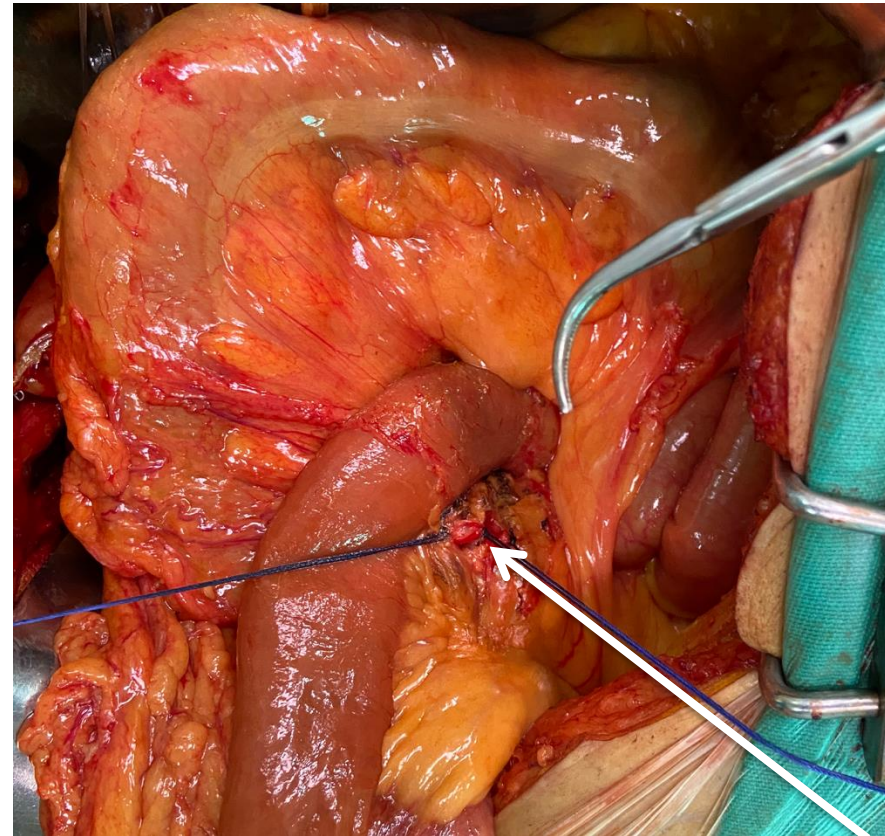


□ 15-25 cm from the Treitz ligament

J1A

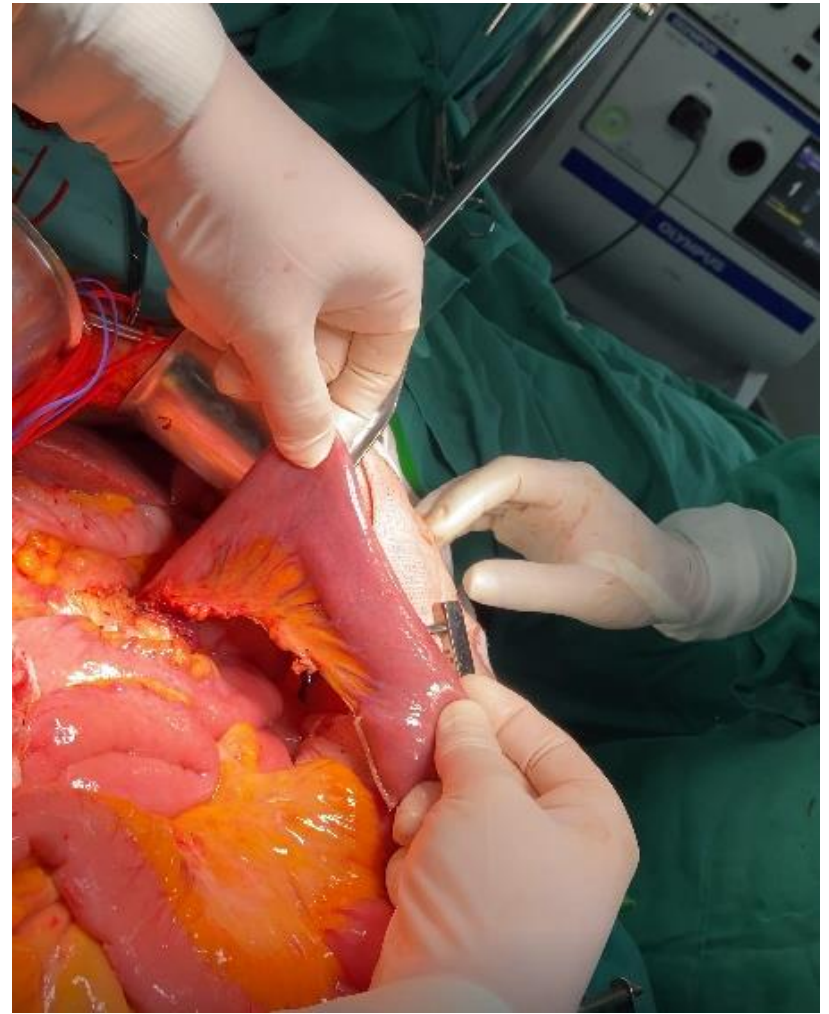
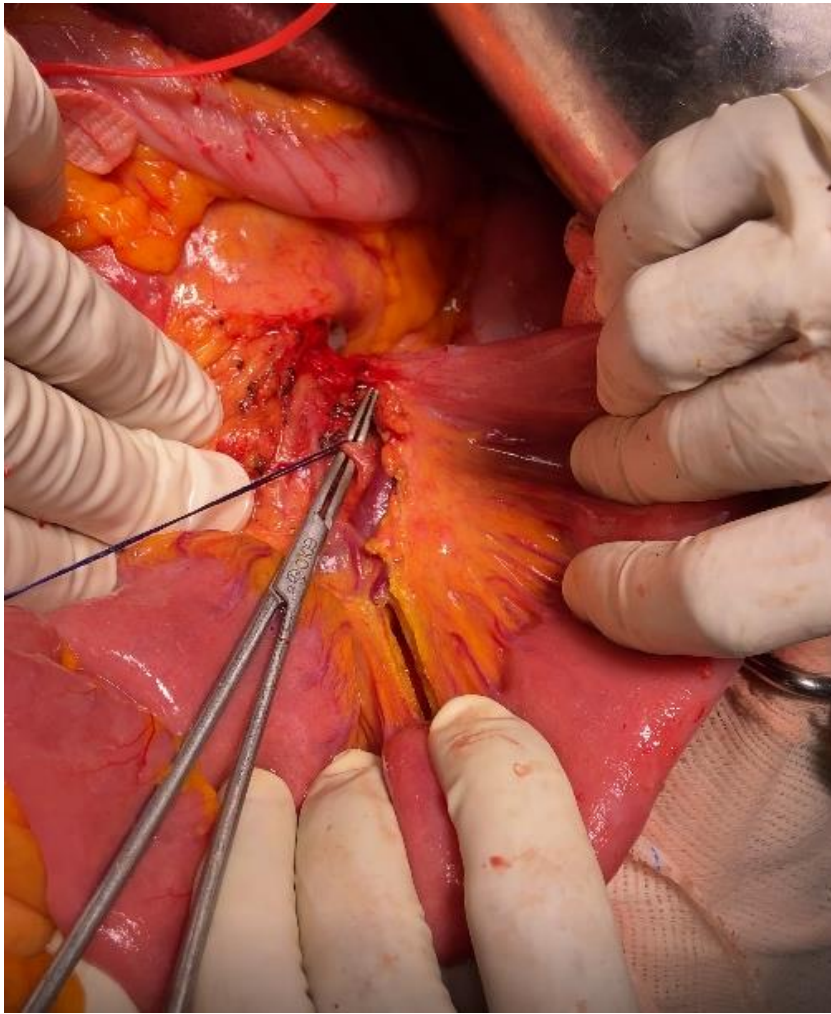
TREITZ LIGAMENT

- Bleeding
- Pancreatic fistula
- Delayed gastric emptying
- Oncology**

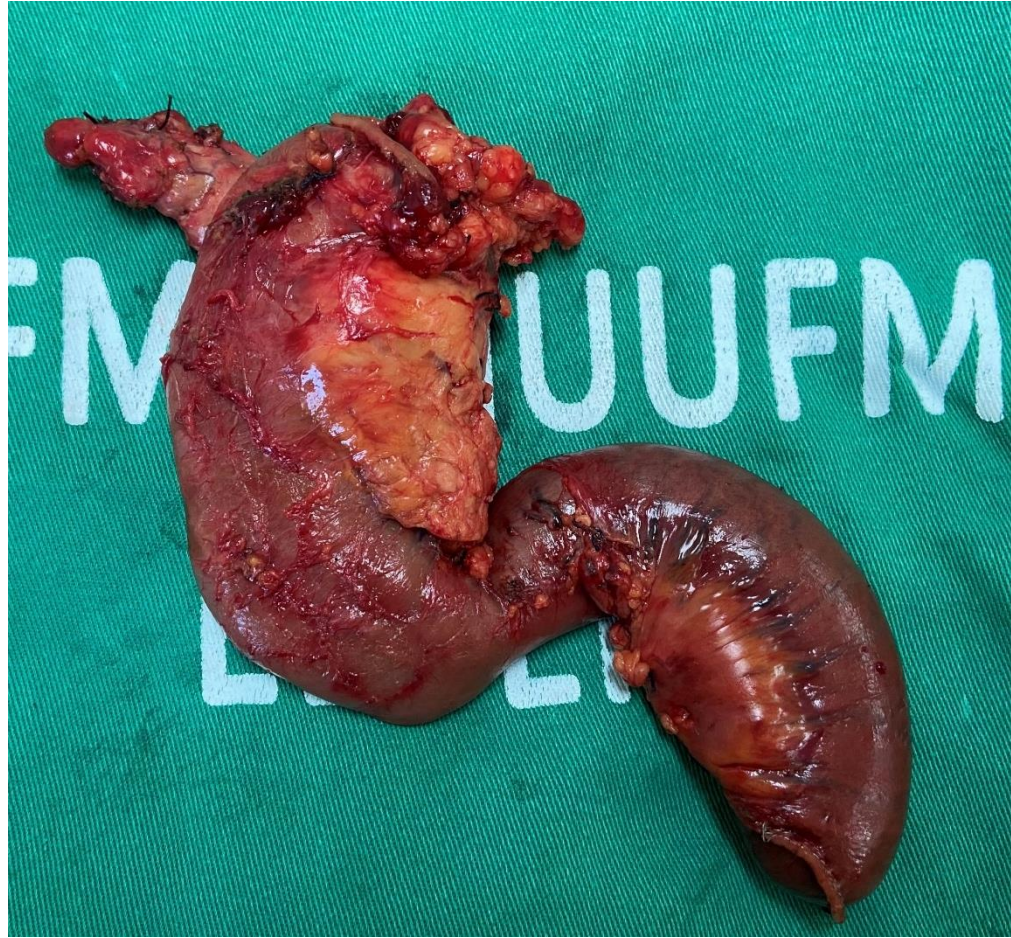
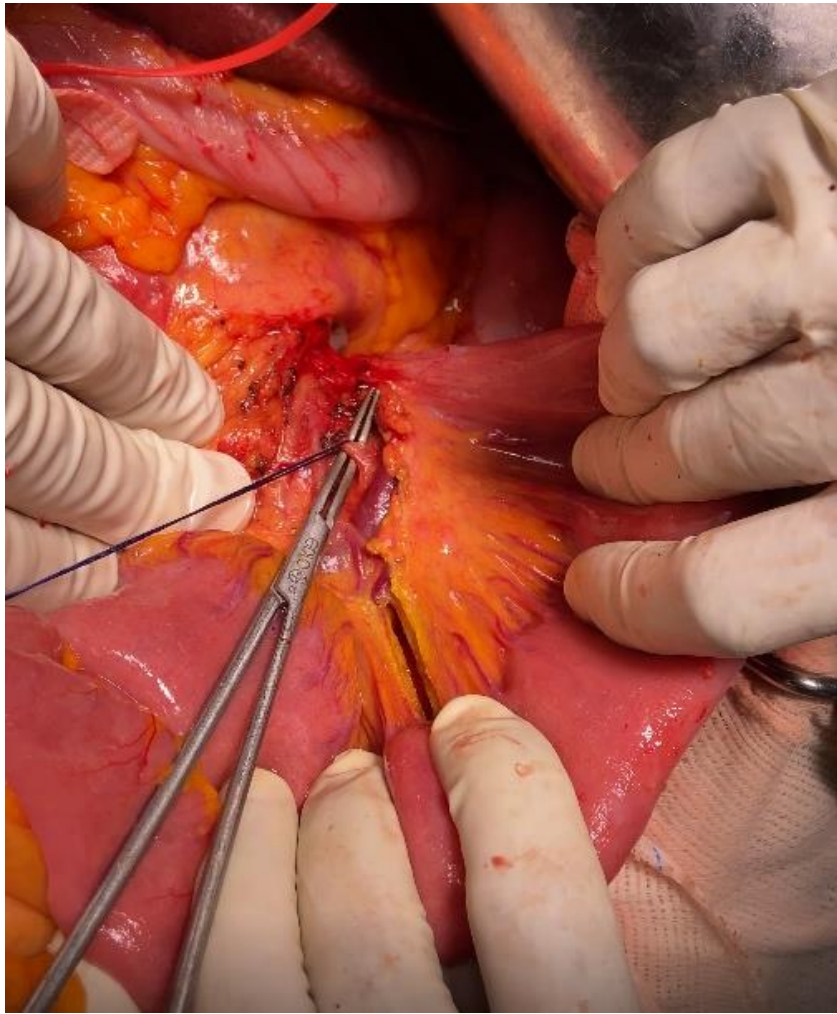


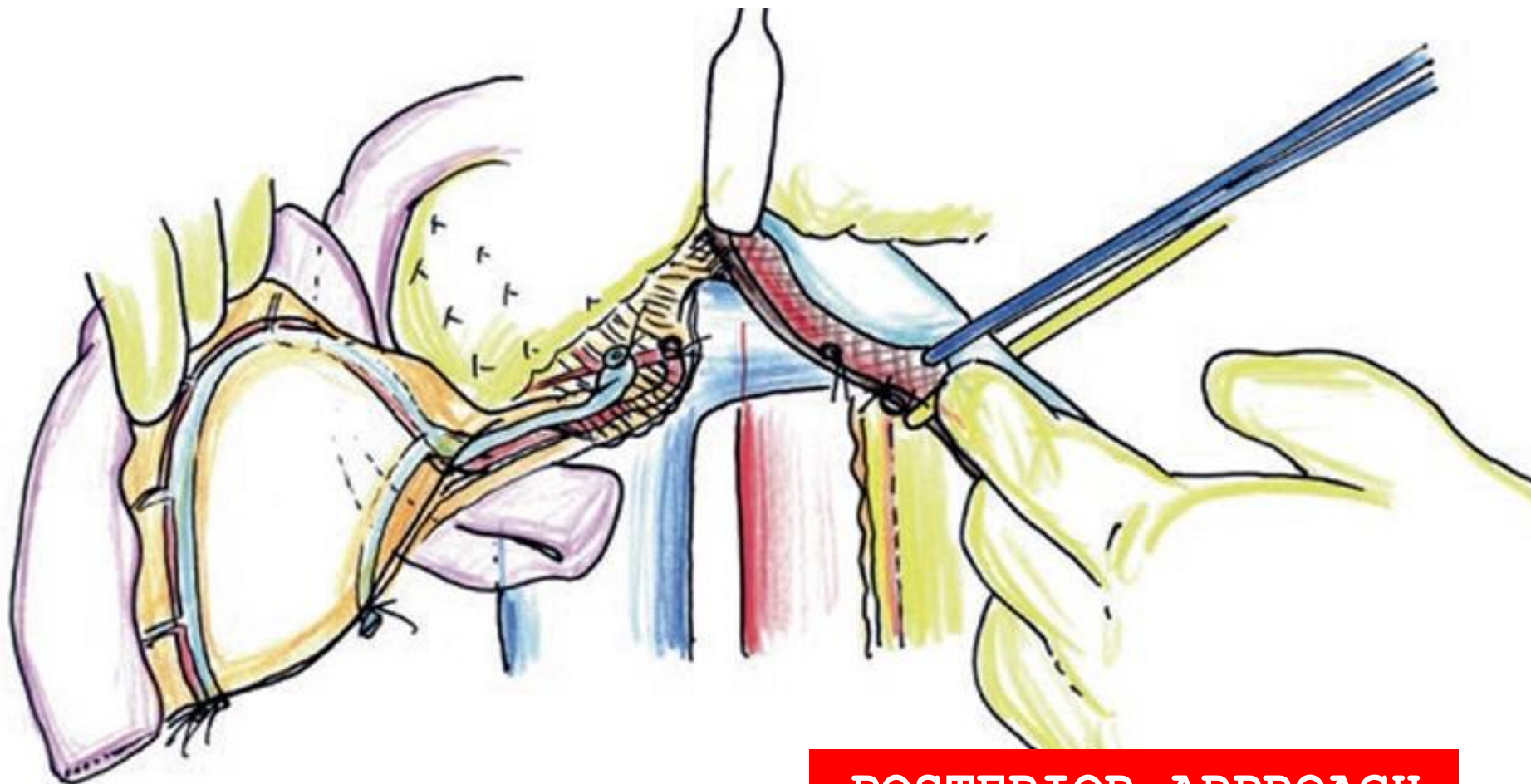
J1A

Level 2



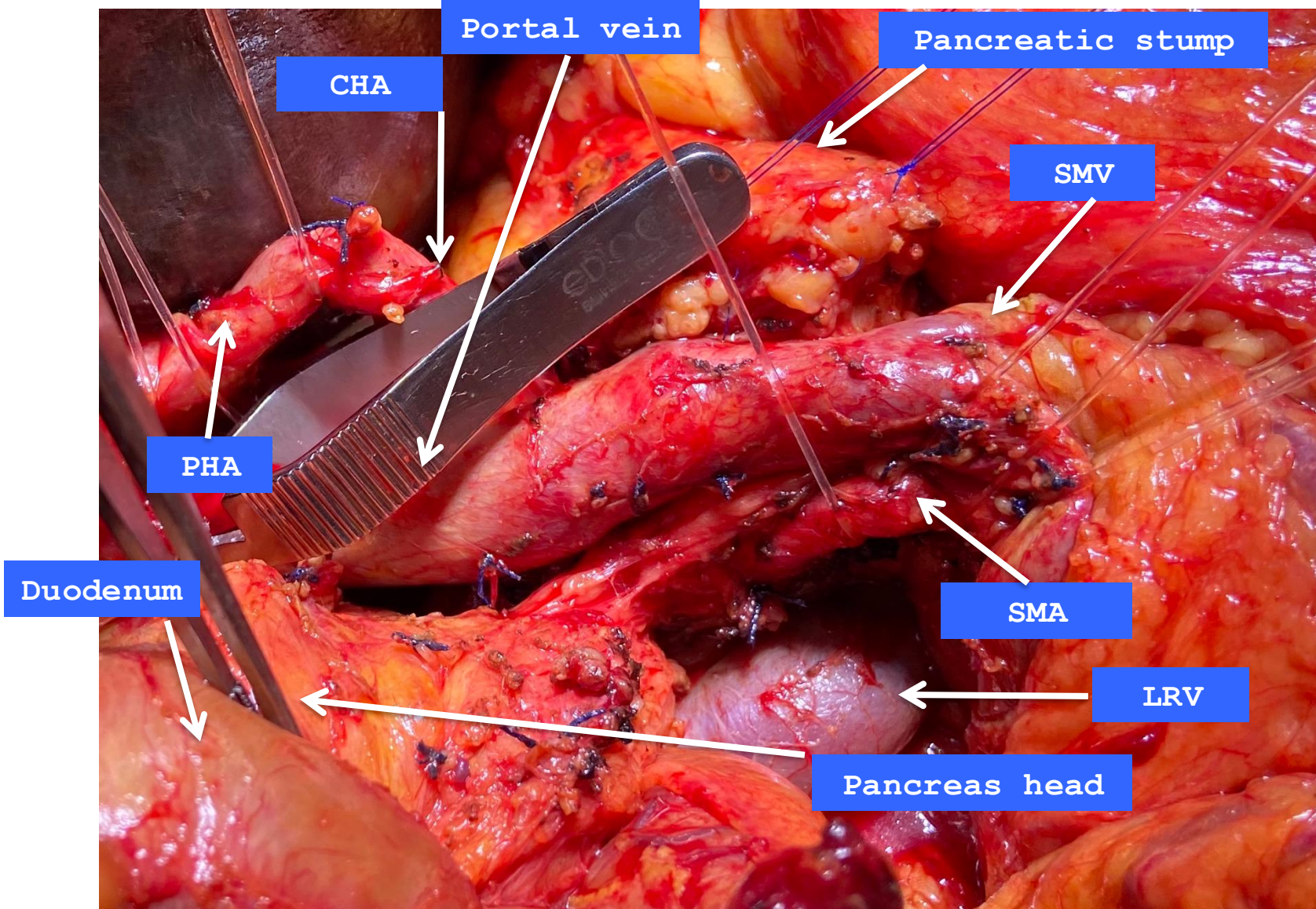
Level 2





POSTERIOR APPROACH

RESECTION

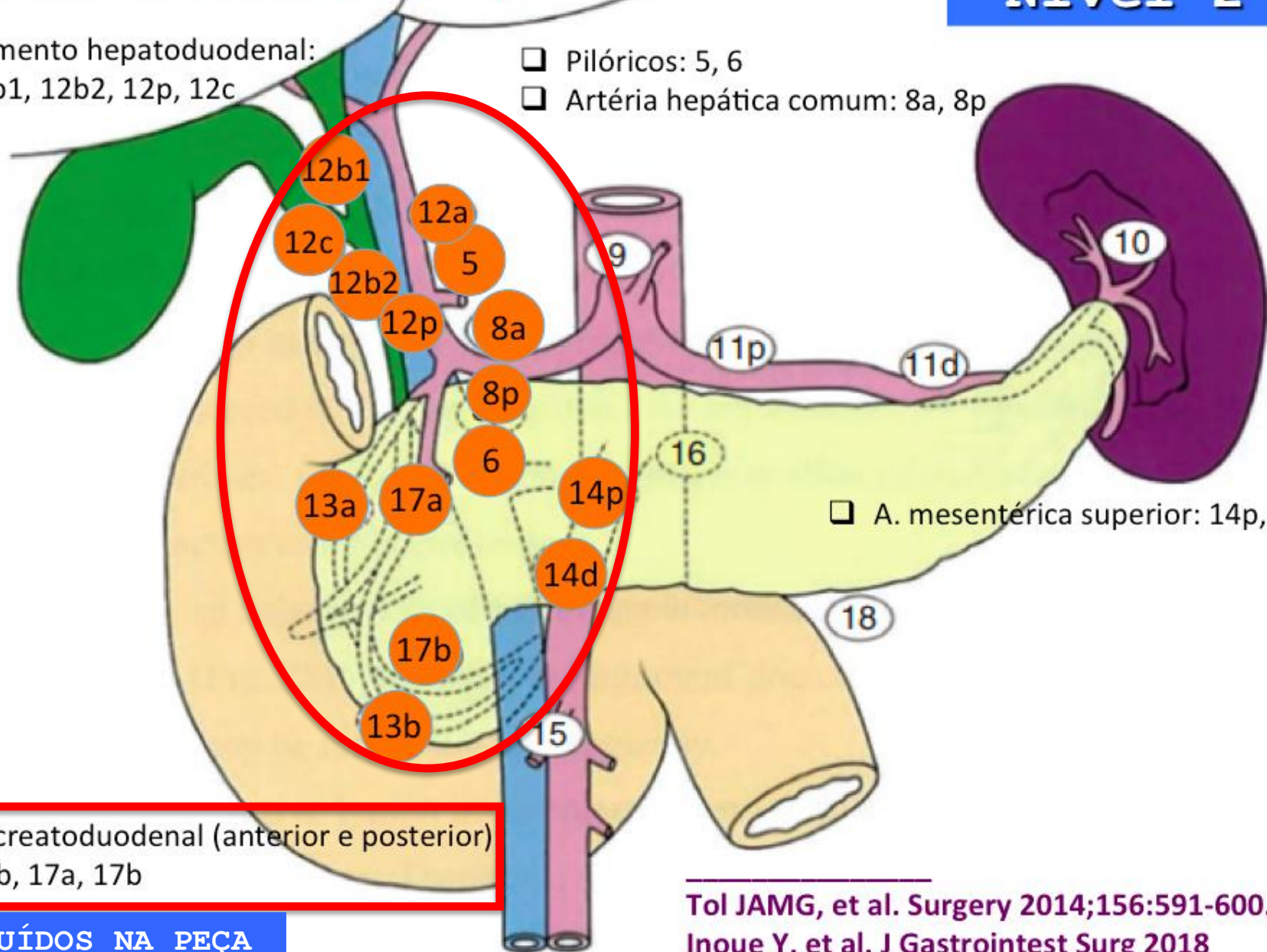


Linfadenectomia

Nível 2

☐ Ligamento hepatoduodenal:
12a, 12b1, 12b2, 12p, 12c

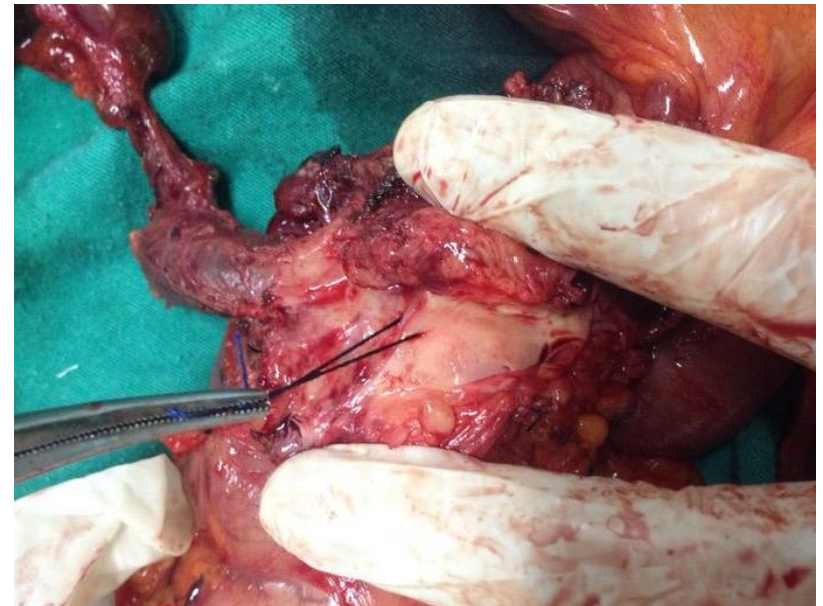
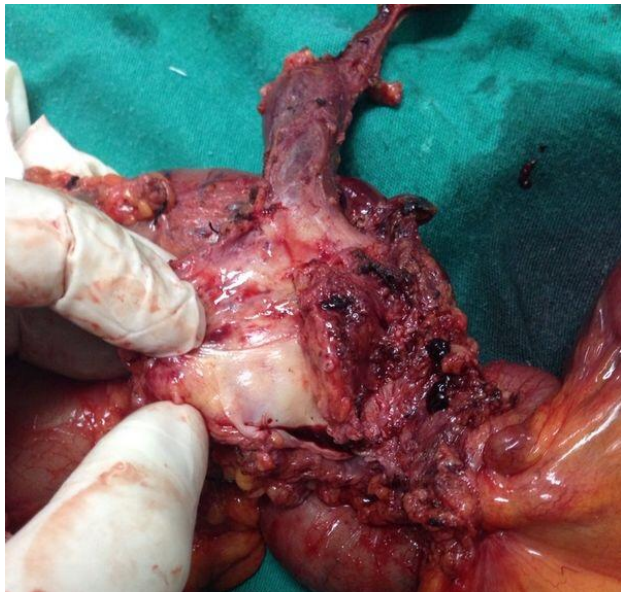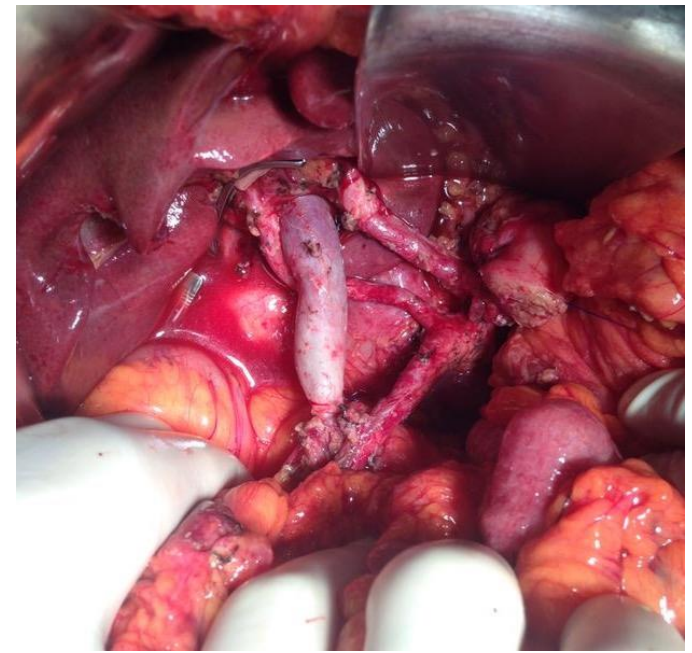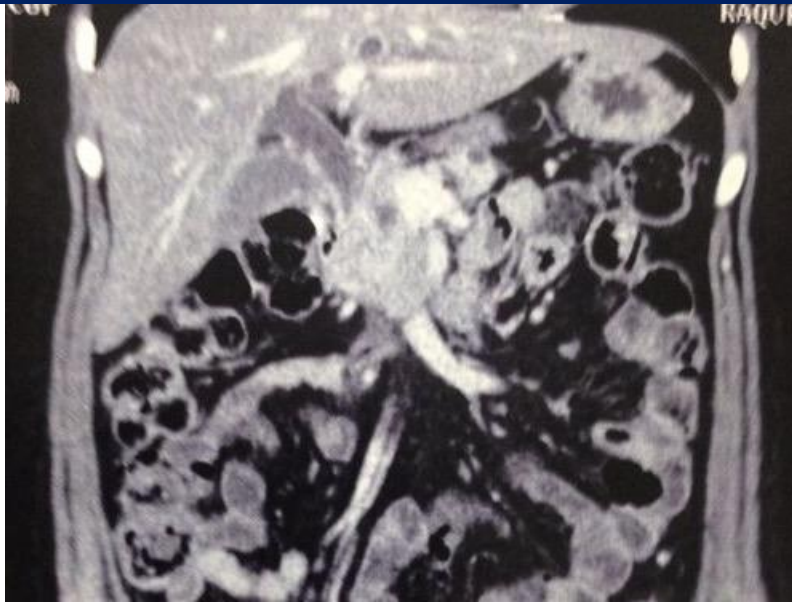
☐ Pilóricos: 5, 6
☐ Artéria hepática comum: 8a, 8p



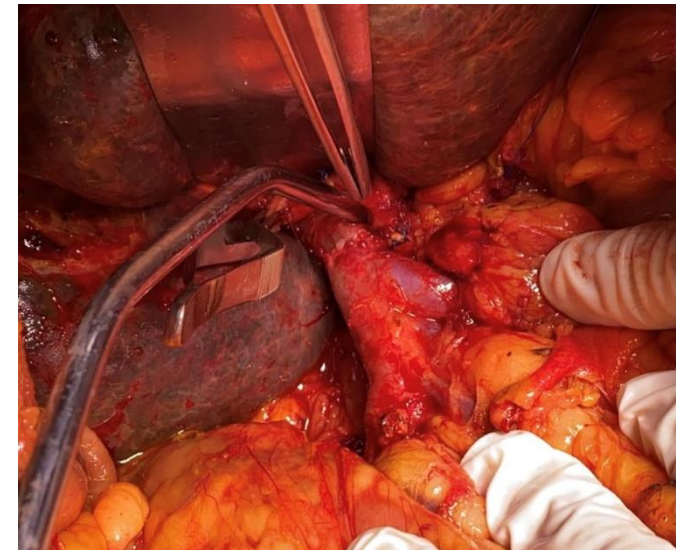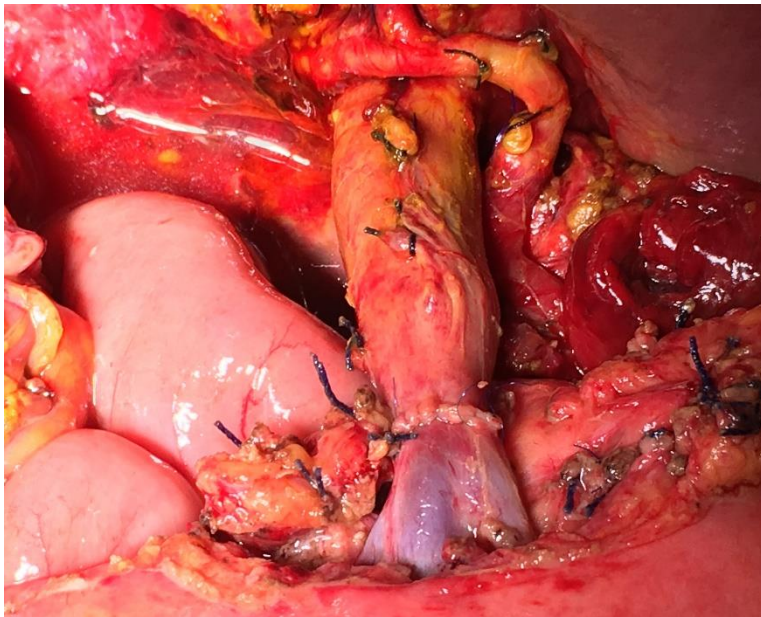
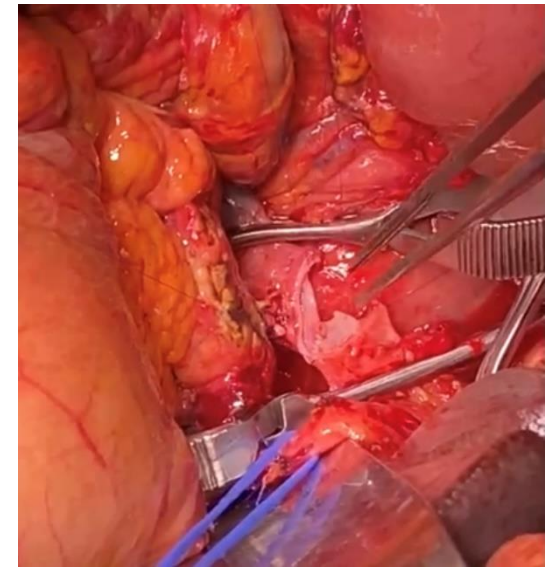
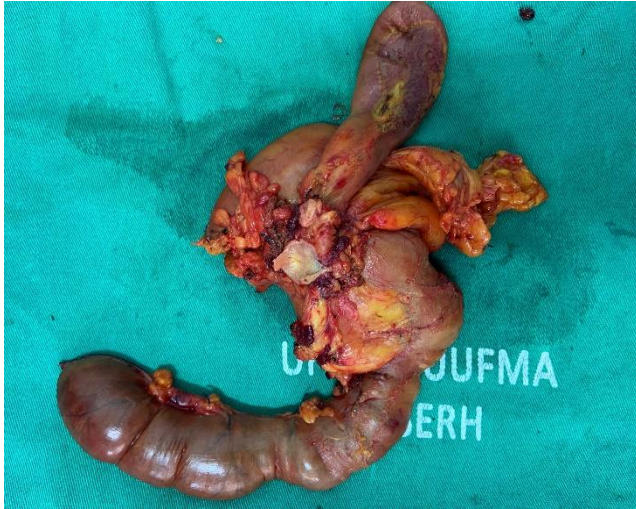INCLUÍDOS NA PEÇA

Tol JAMG, et al. Surgery 2014;156:591-600.
Inoue Y, et al. J Gastrointest Surg 2018

VASCULAR RESECTION



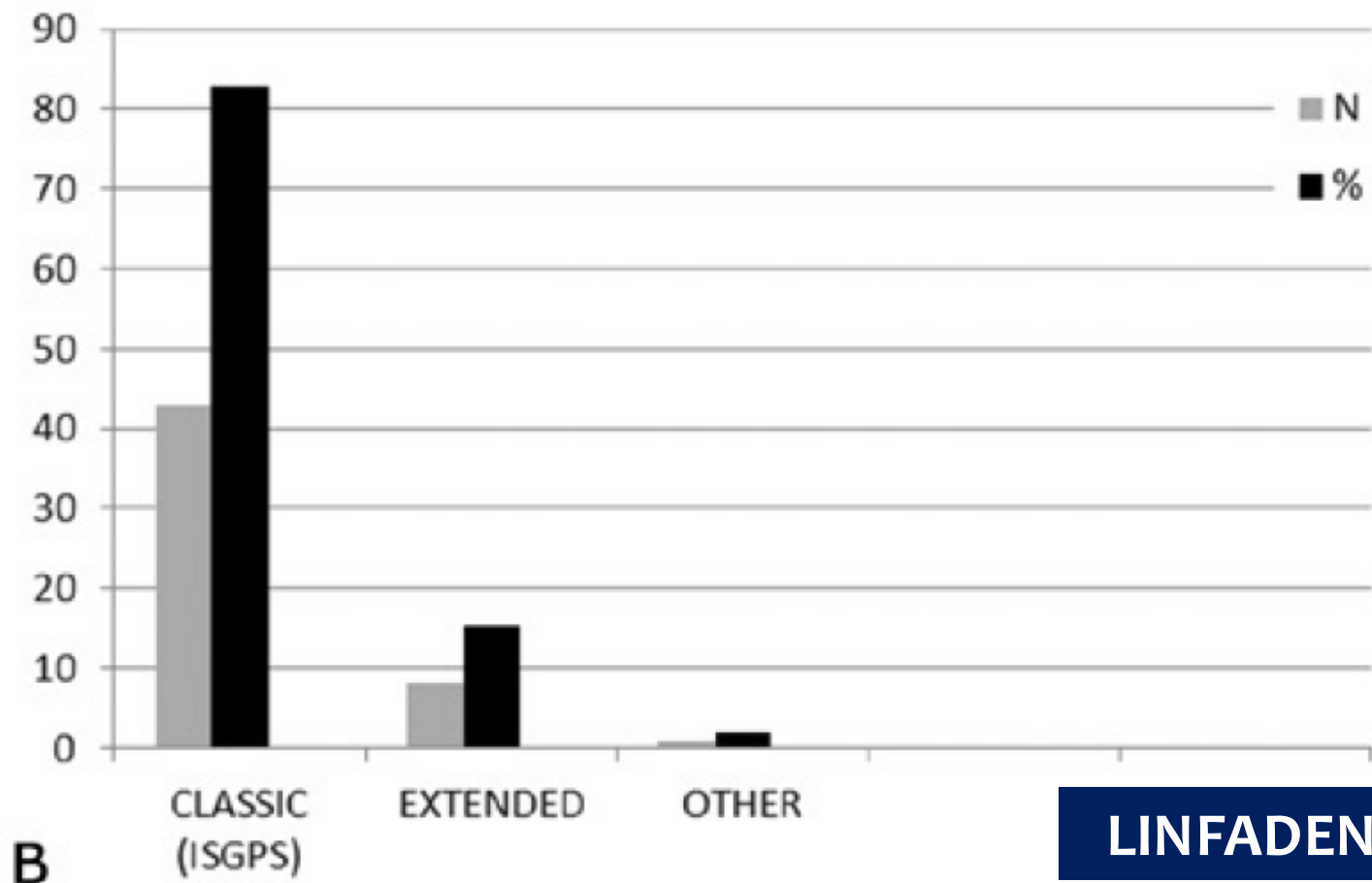
VASCULAR RESECTION



PANCREATODUODENECTOMY: BRAZILIAN PRACTICE PATTERNS*

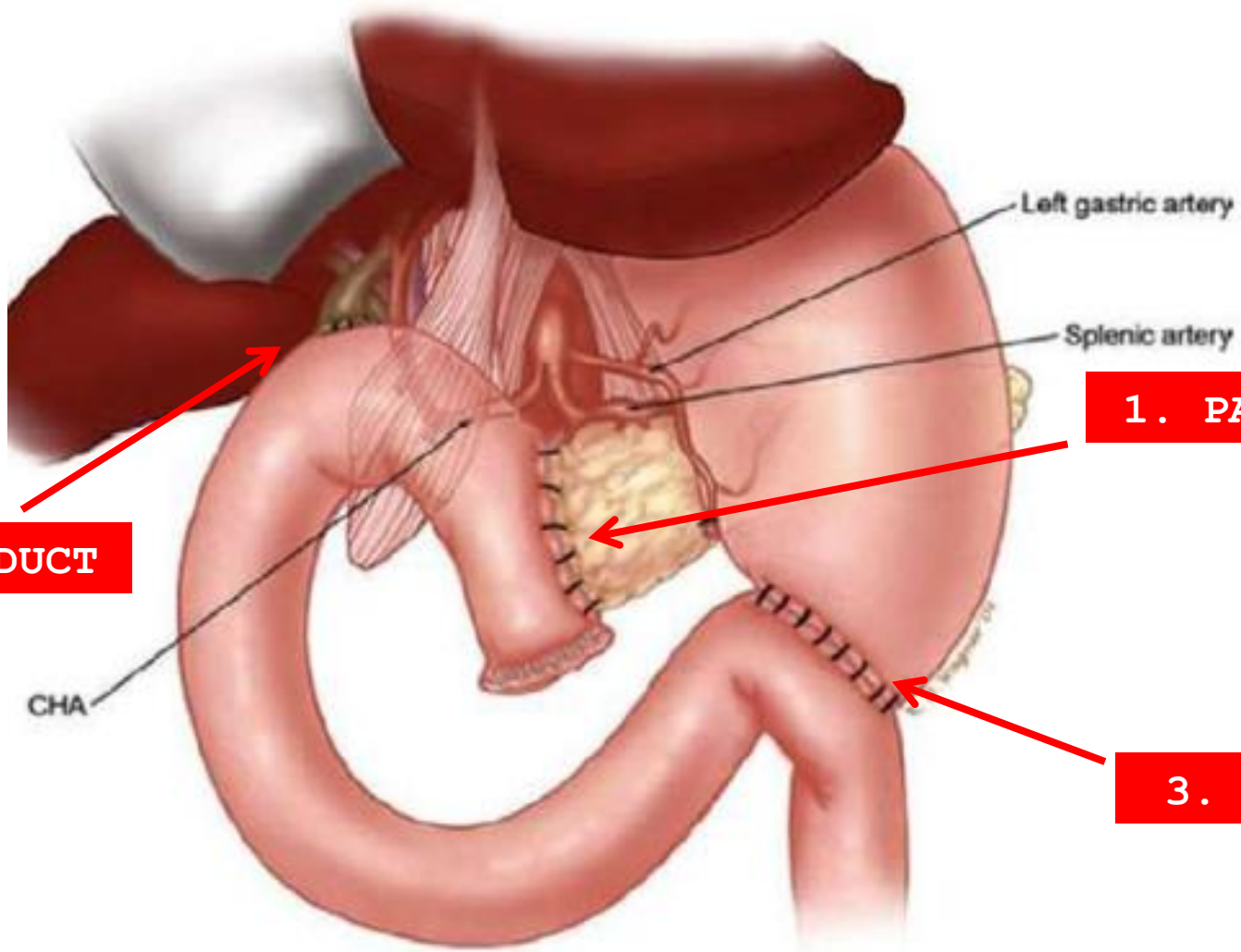
*Duodenopancreatectomia: prática padrão do Brasil**

Orlando Jorge M **TORRES**¹, Eduardo de Souza M **FERNANDES**², Rodrigo Rodrigues **VASQUES**¹, Fabio Luís **WAECHTER**³, Paulo Cezar G. **AMARAL**⁴, Marcelo Bruno de **REZENDE**⁵, Roland Montenegro **COSTA**⁶, André Luís **MONTAGNINI**⁷



RECONSTRUCTION

☐ Single limb



2. BILE DUCT

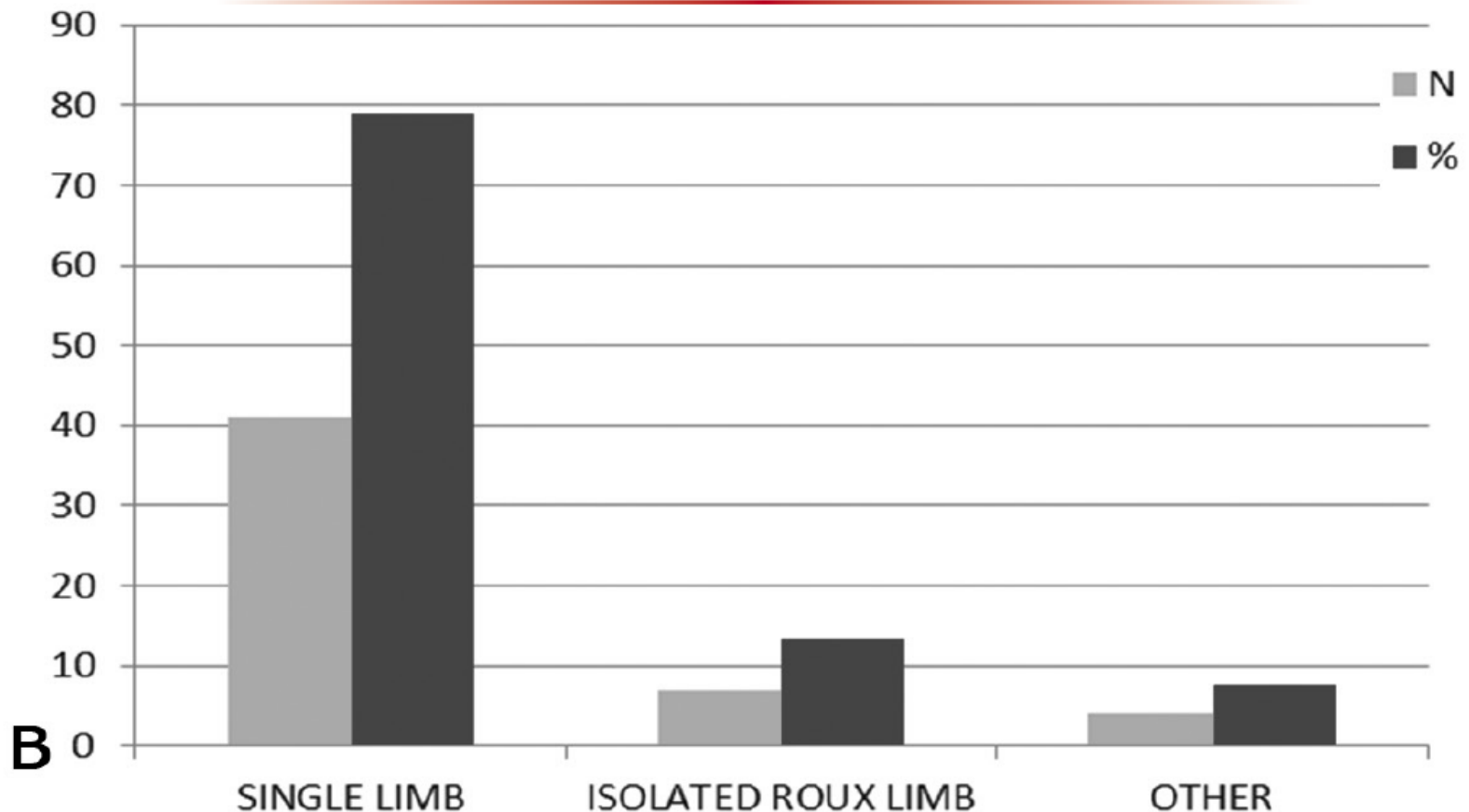
1. PANCREAS

3. STOMACH

PANCREATODUODENECTOMY: BRAZILIAN PRACTICE PATTERNS*

*Duodenopancreatectomia: prática padrão do Brasil**

Orlando Jorge M **TORRES**¹, Eduardo de Souza M **FERNANDES**², Rodrigo Rodrigues **VASQUES**¹, Fabio Luís **WAECHTER**³,
Paulo Cezar G. **AMARAL**⁴, Marcelo Bruno de **REZENDE**⁵, Roland Montenegro **COSTA**⁶, André Luís **MONTAGNINI**⁷



PANCREATIC

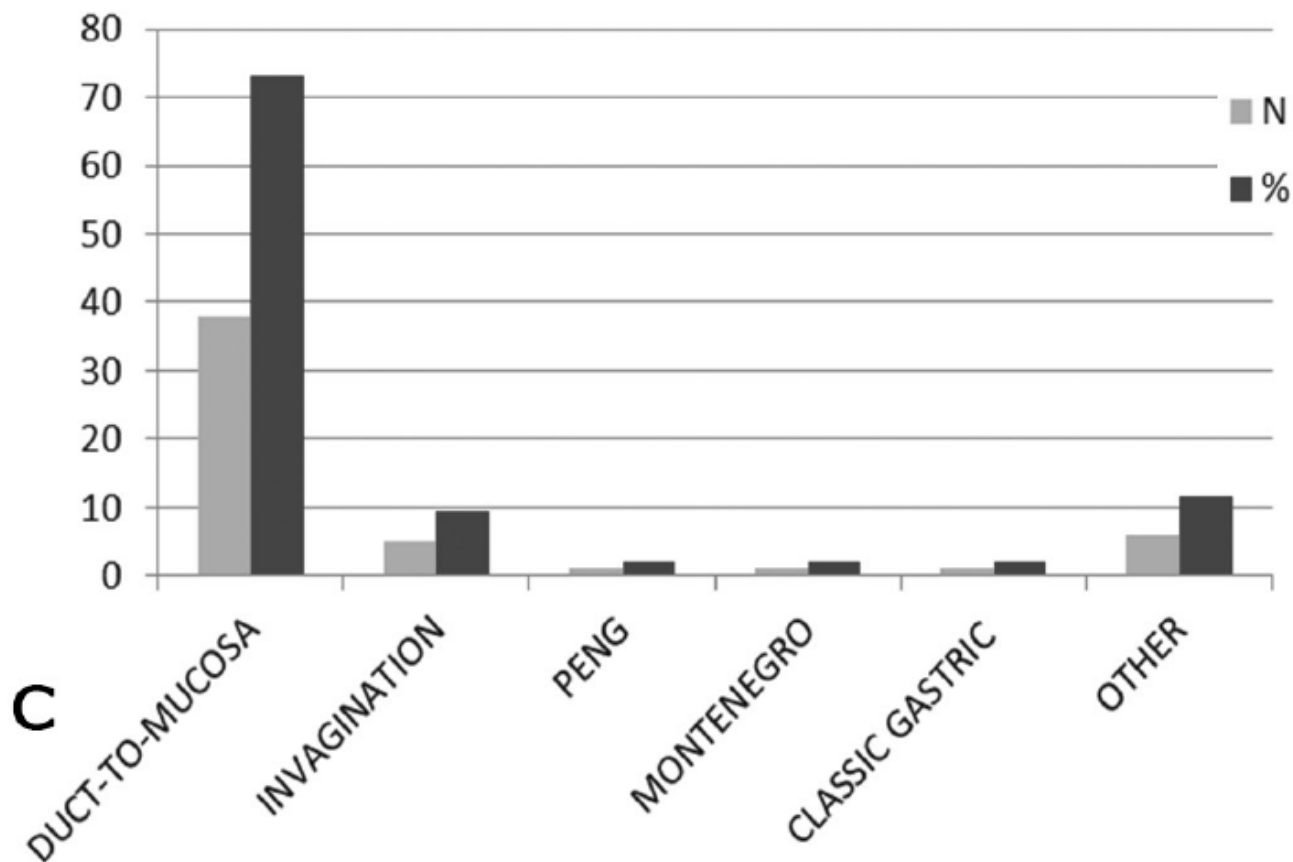
- Invagination (Hunt) (1995–1999)
- Duct-to-mucosa (2000–2016)
- Peng (2013)
- Modified Heidelberg (2016)



PANCREATODUODENECTOMY: BRAZILIAN PRACTICE PATTERNS*

*Duodenopancreatectomia: prática padrão do Brasil**

Orlando Jorge M **TORRES**¹, Eduardo de Souza M **FERNANDES**², Rodrigo Rodrigues **VASQUES**¹, Fabio Luís **WAECHTER**³, Paulo Cezar G. **AMARAL**⁴, Marcelo Bruno de **REZENDE**⁵, Roland Montenegro **COSTA**⁶, André Luís **MONTAGNINI**⁷



Hangzhou, China - 2017

Pancreatoduodenectomy, Brazilian practice patterns

Orlando Jorge Martins Torres

Universidade Federal do Maranhão, Centro de Ciências da Saúde, Departamento de Medicina II
São Luís, Maranhão, Brazil



Torres教授来自巴西的马拉尼昂州联邦大学医学院，担任消化道手术部中心主任，致力于消化道肿瘤外科以及肝胆胰外科。

曾在多个国际医学中心进修和培训，如Shouldice疝研究所（加拿大，1999年）、斯隆凯特林癌症中心（纽约，2000年）、匹兹堡大学医学中心（美国，2005年）、MD安德森癌症中心（休斯敦，2010）、伦敦帝国学院（伦敦，2012年）、挪威奥斯陆大学医院（2015年）、孟买的塔塔纪念医院（2016年，印度）等。

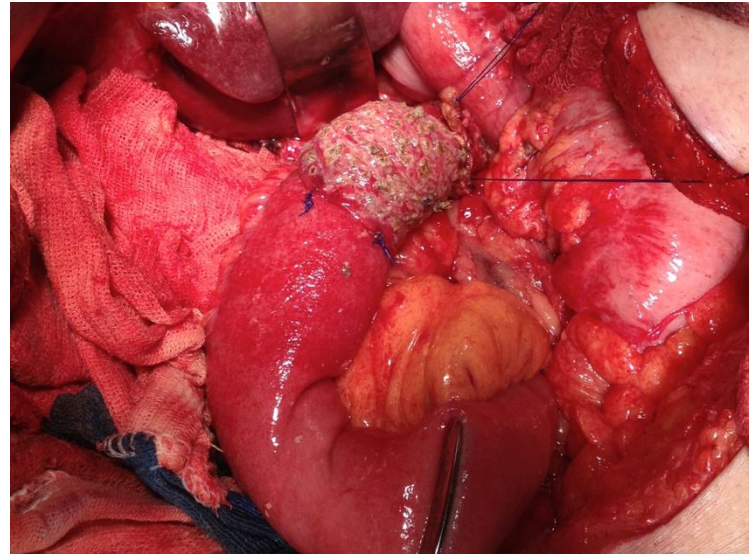
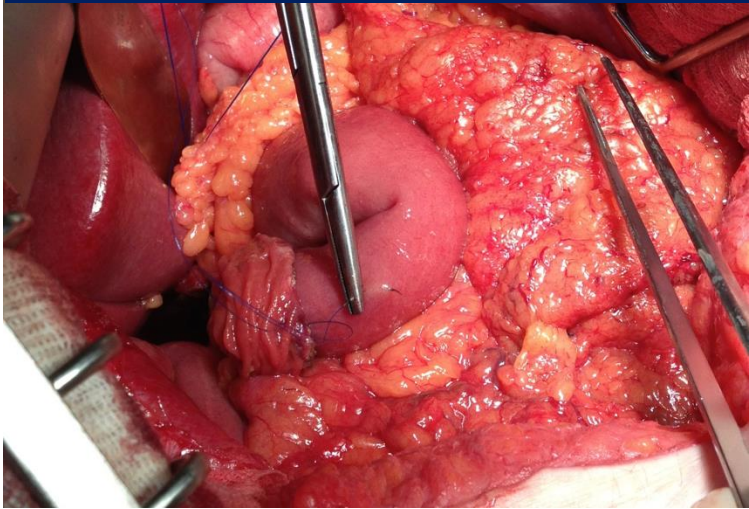
讲座时间：2017-5-31 上午 7点30分

地点：浙二医院滨江院区中心楼20楼西示教室（视屏会议转播）

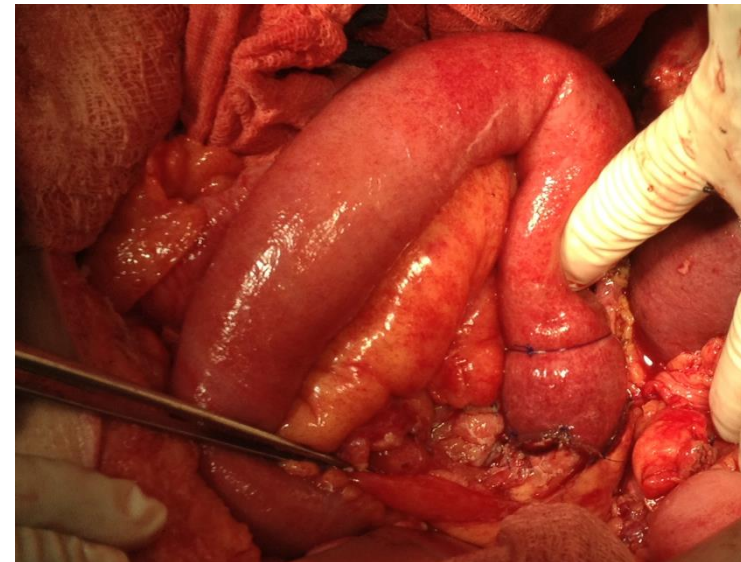
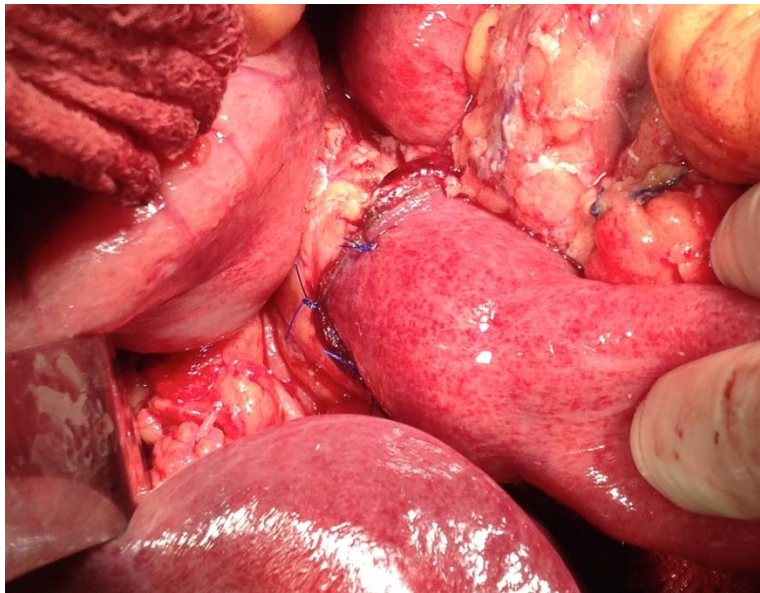Shu-You Peng



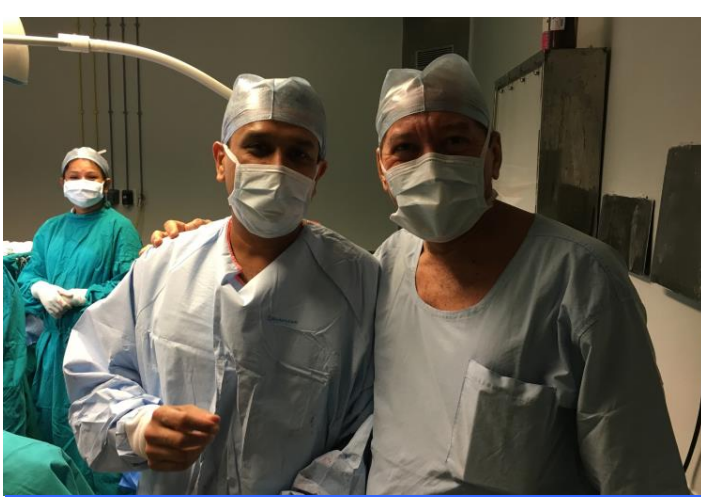PENG'S TECHNIQUE



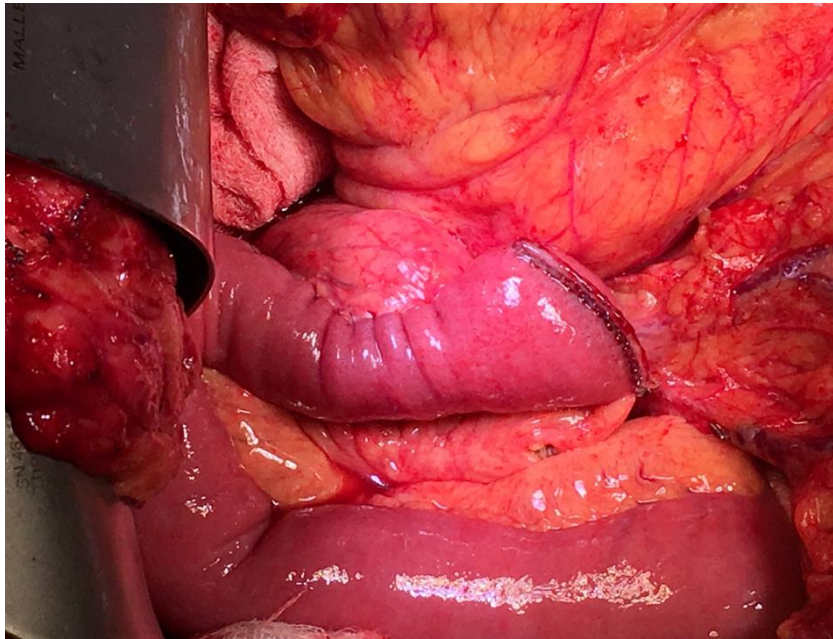
2013



Mumbai 2016



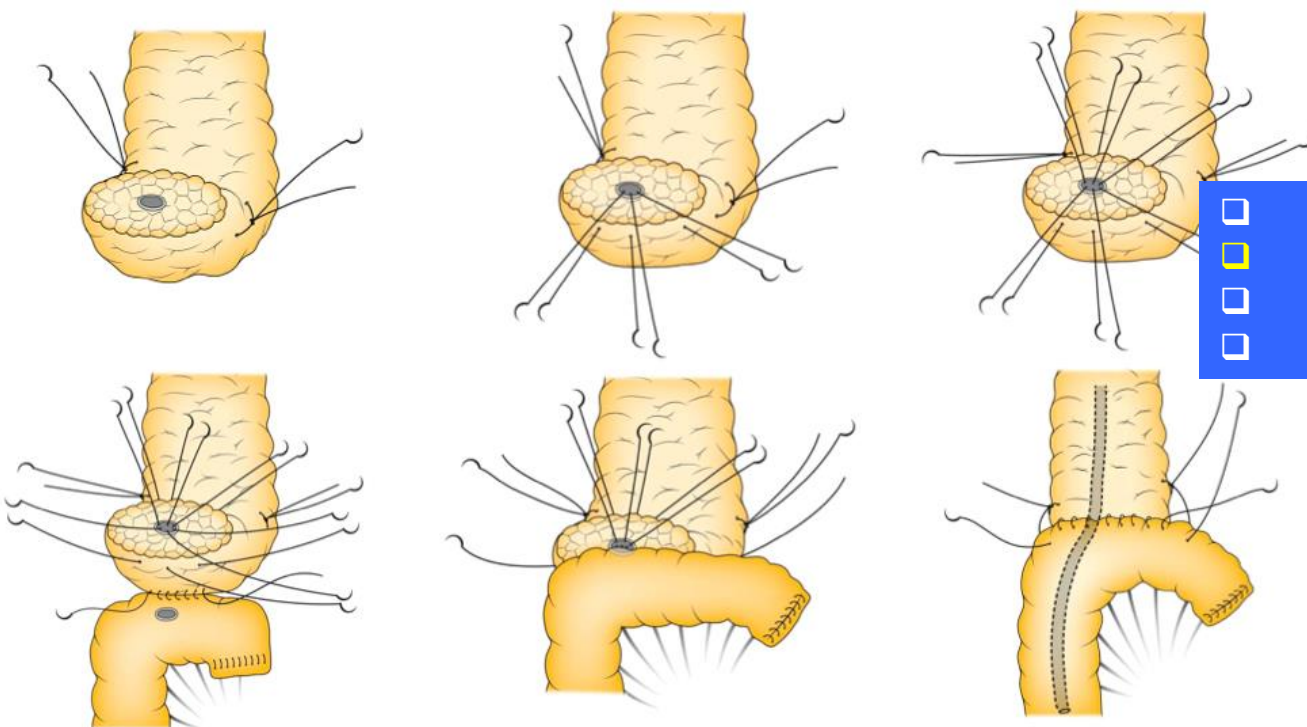
Shailesh Shrikhande



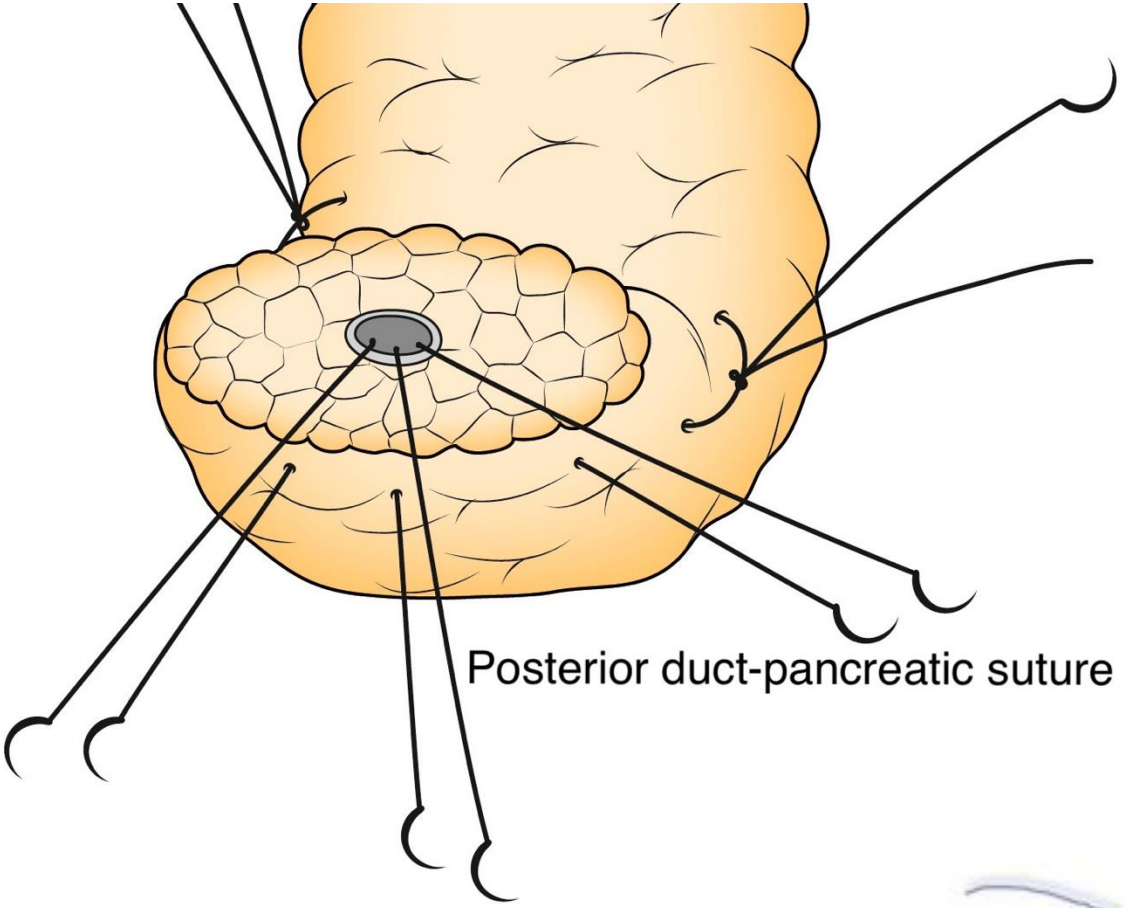
MODIFIED HEIDELBERG TECHNIQUE FOR PANCREATIC ANASTOMOSIS

Anastomose pancreática pela técnica de Heidelberg modificada

Orlando Jorge M TORRES¹, Roberto C N da Cunha **COSTA¹**, Felipe F Macatrão **COSTA¹**, Romerito Fonseca **NEIVA¹**,
Iarik Soares **SULEIMAN¹**, Yglésio L Moyses S **SOUZA¹**, Shailesh V SHRIKHANDE²

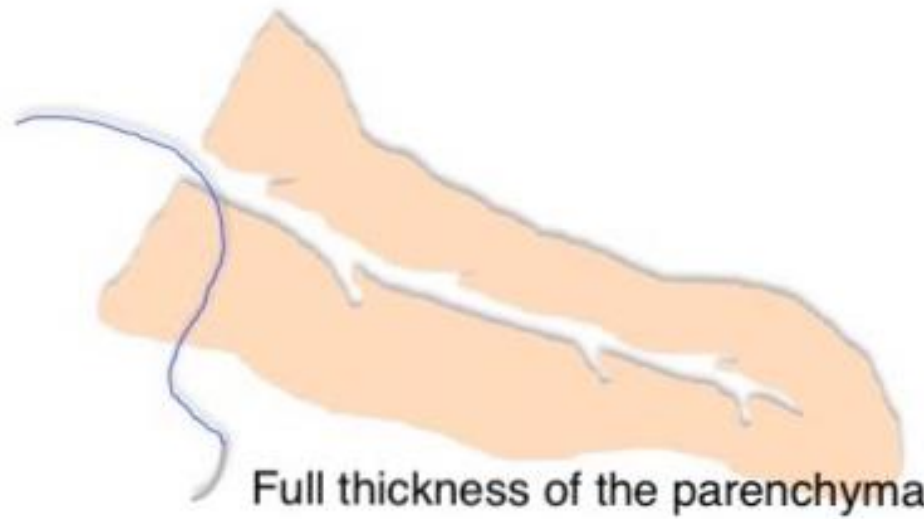
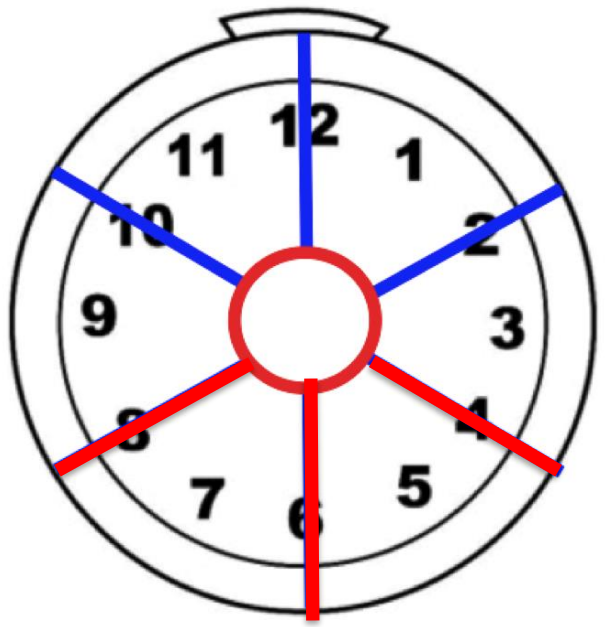


- Bleeding
- Pancreatic fistula
- Delayed gastric emptying
- Oncology



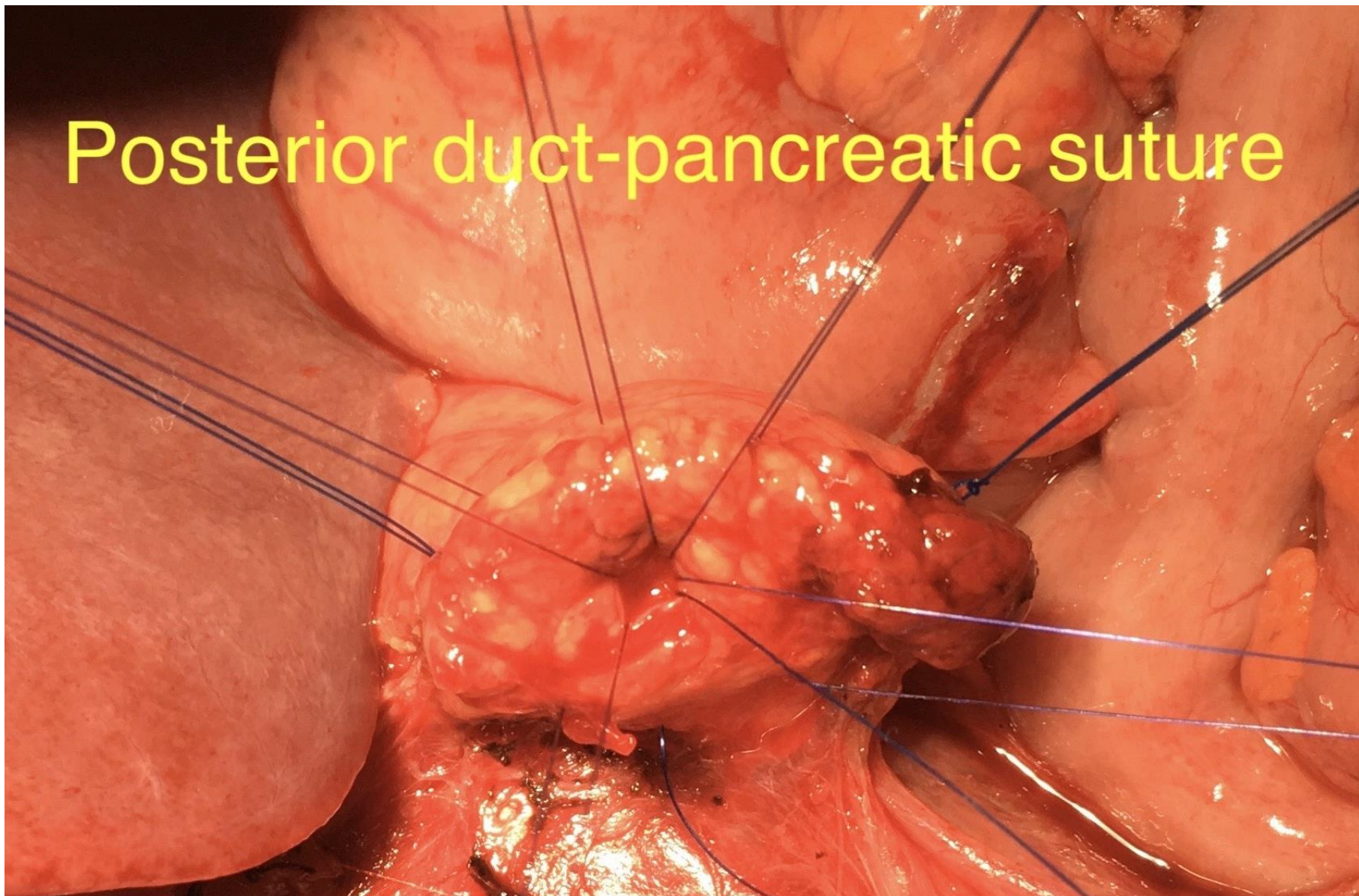
Posterior duct-pancreatic suture

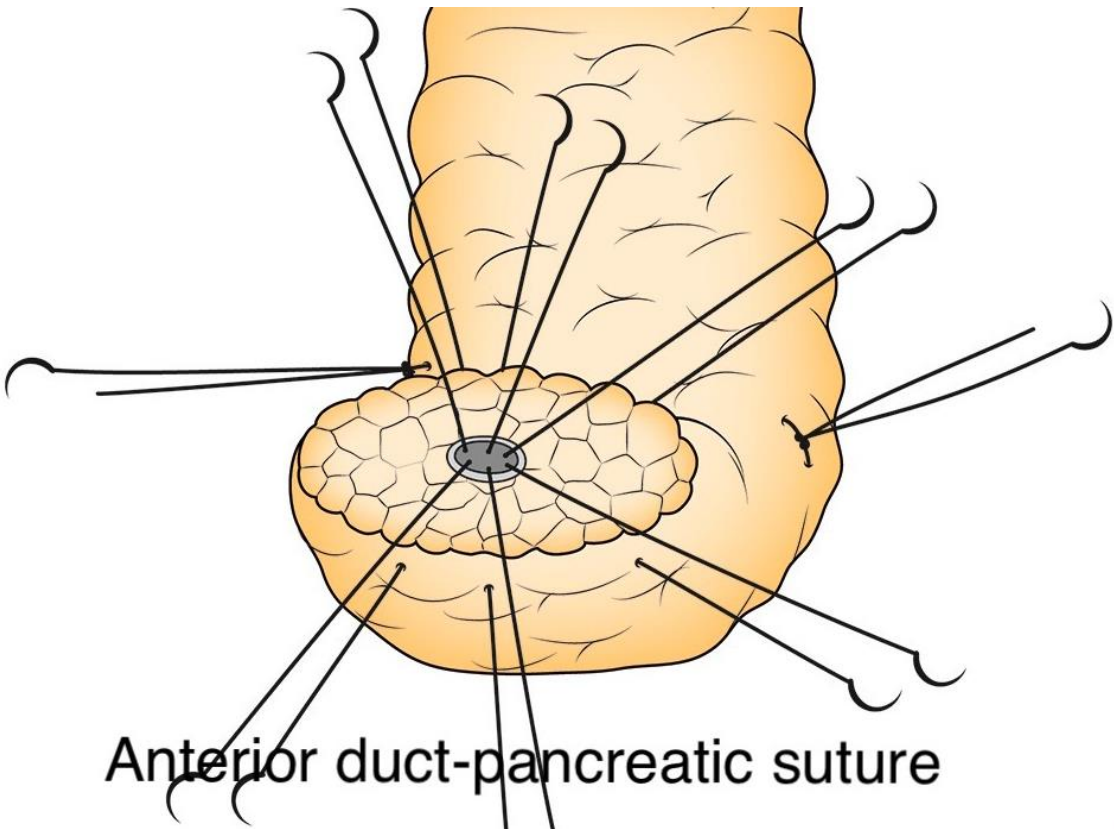
Technique



Full thickness of the parenchyma

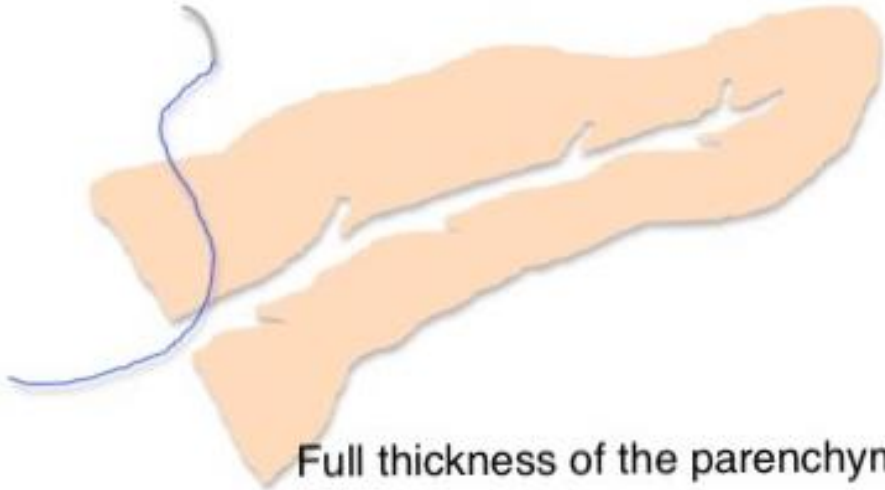
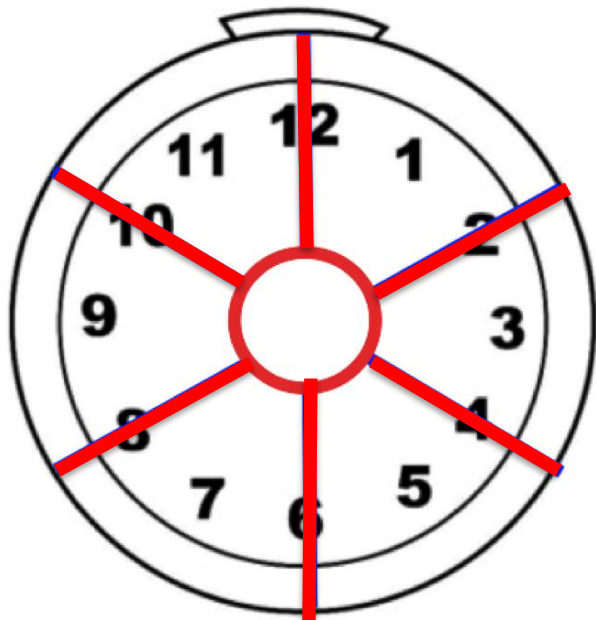
Posterior duct-pancreatic suture





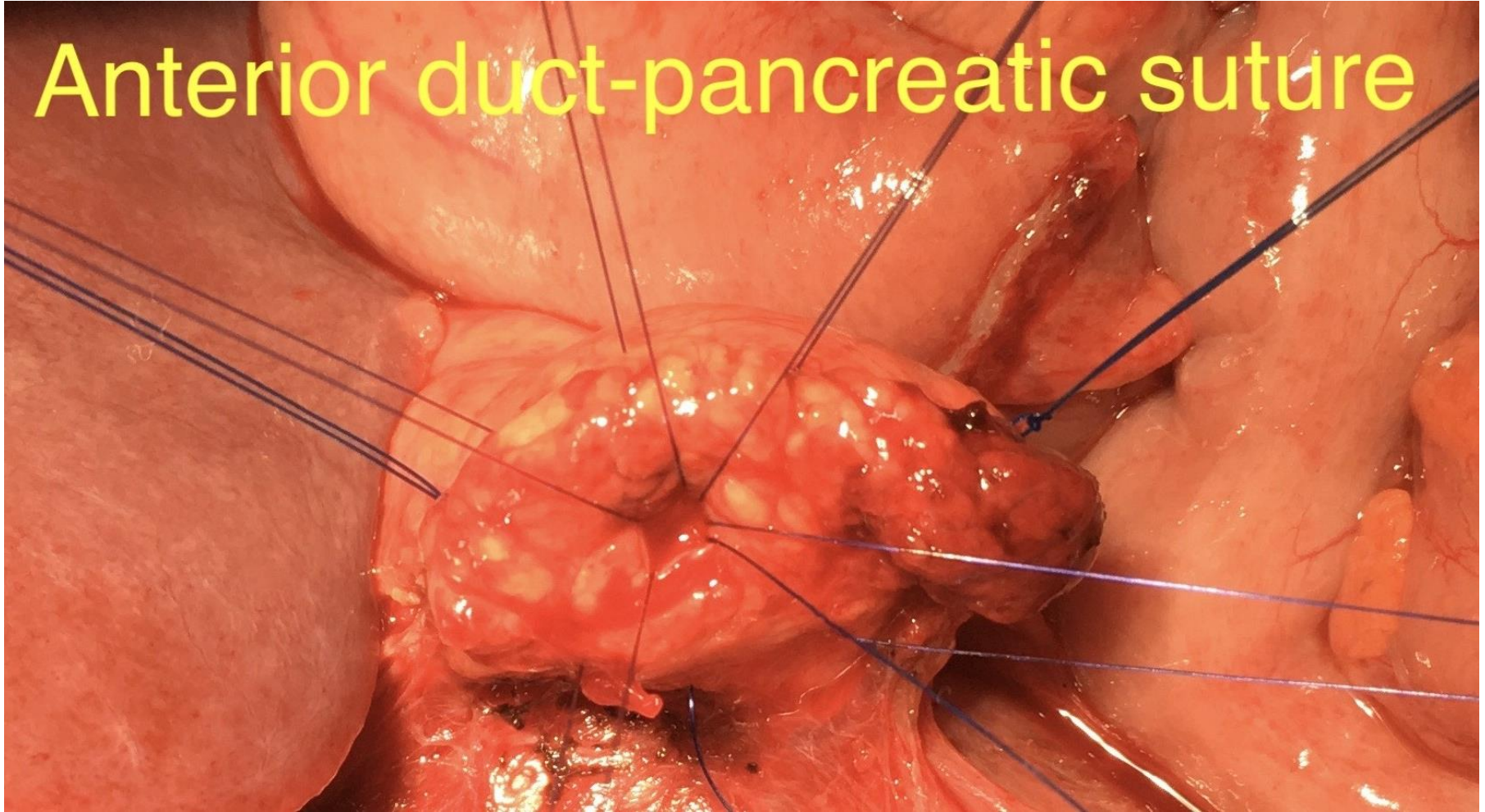
Anterior duct-pancreatic suture

Technique



Full thickness of the parenchyma

Anterior duct-pancreatic suture



Stay suture

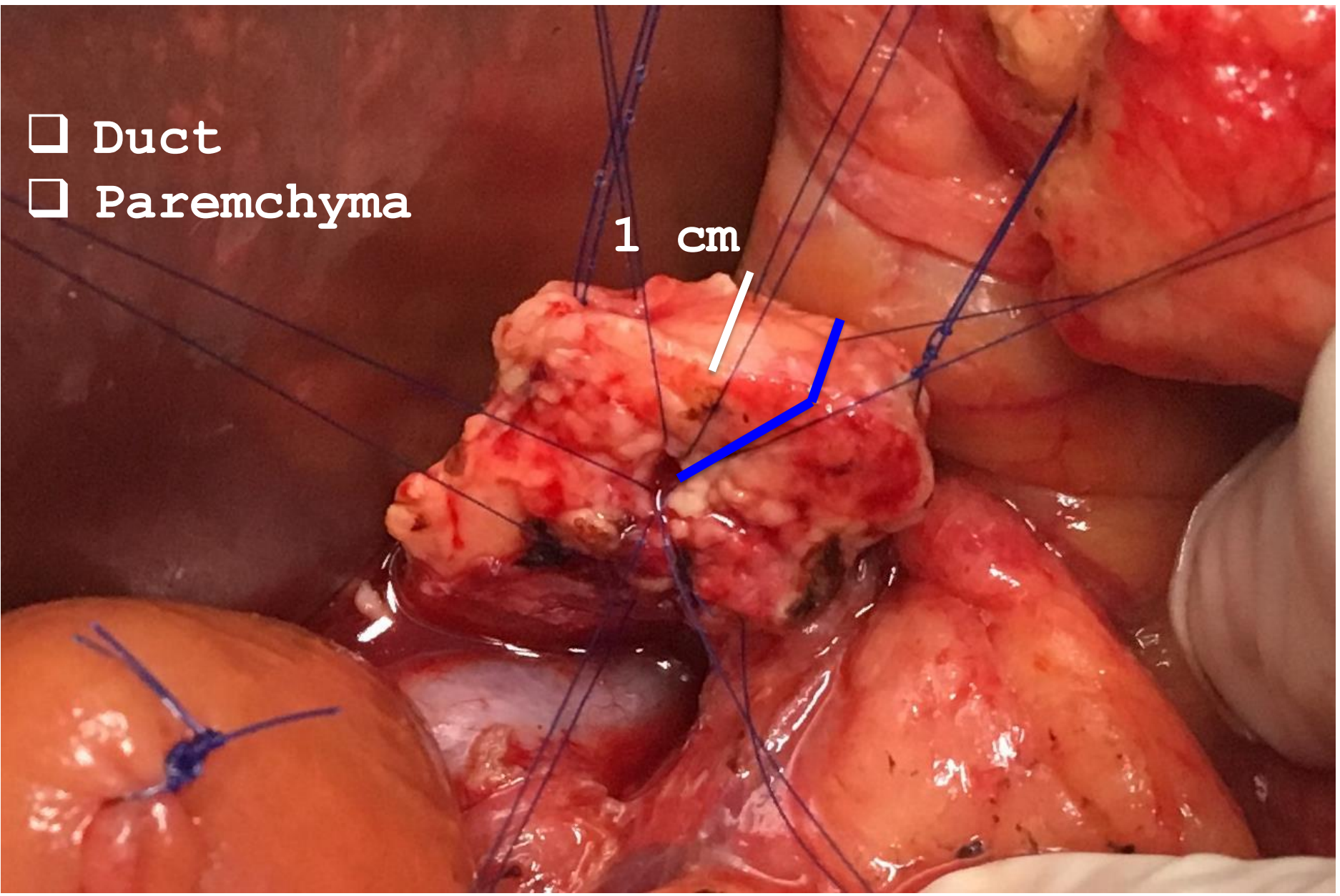
Stump

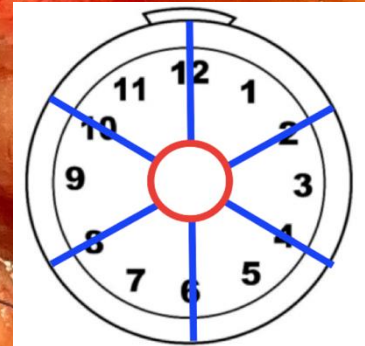
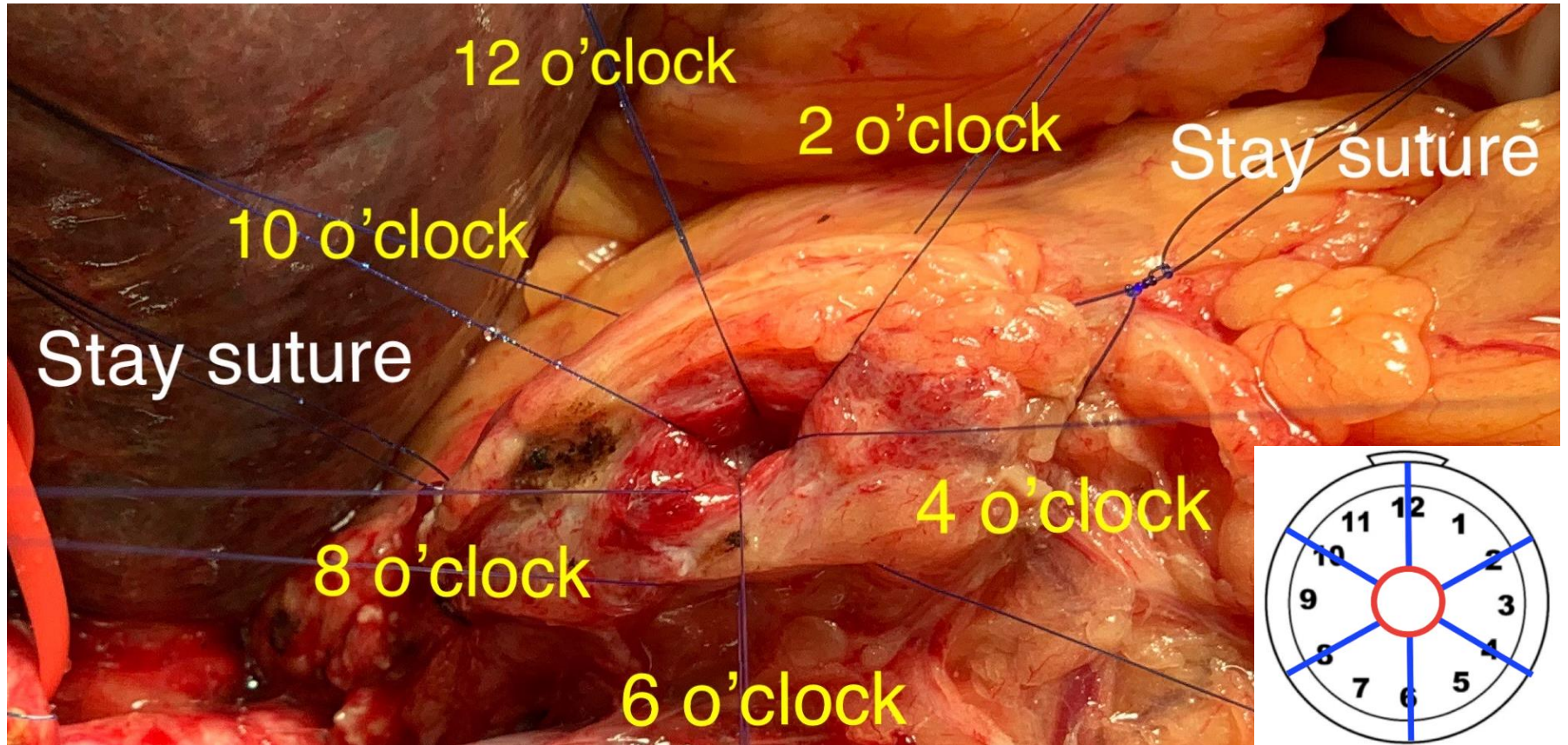


Duct

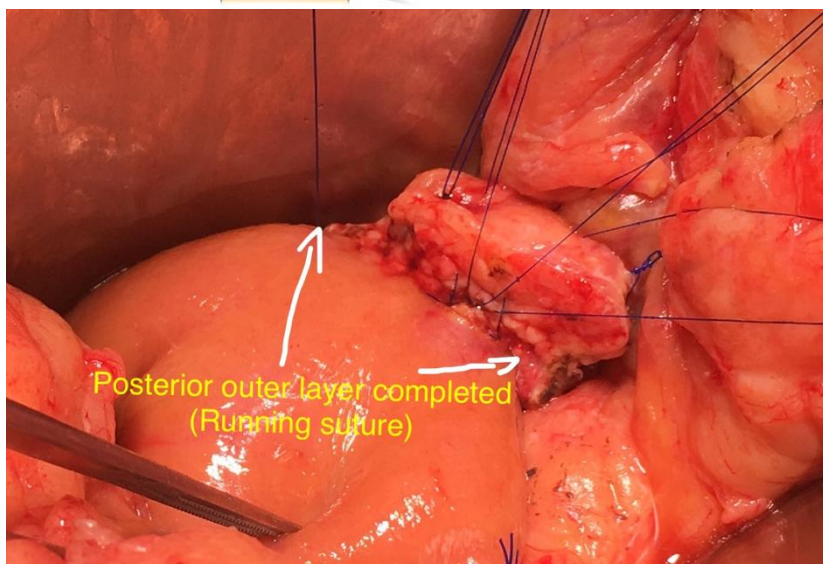
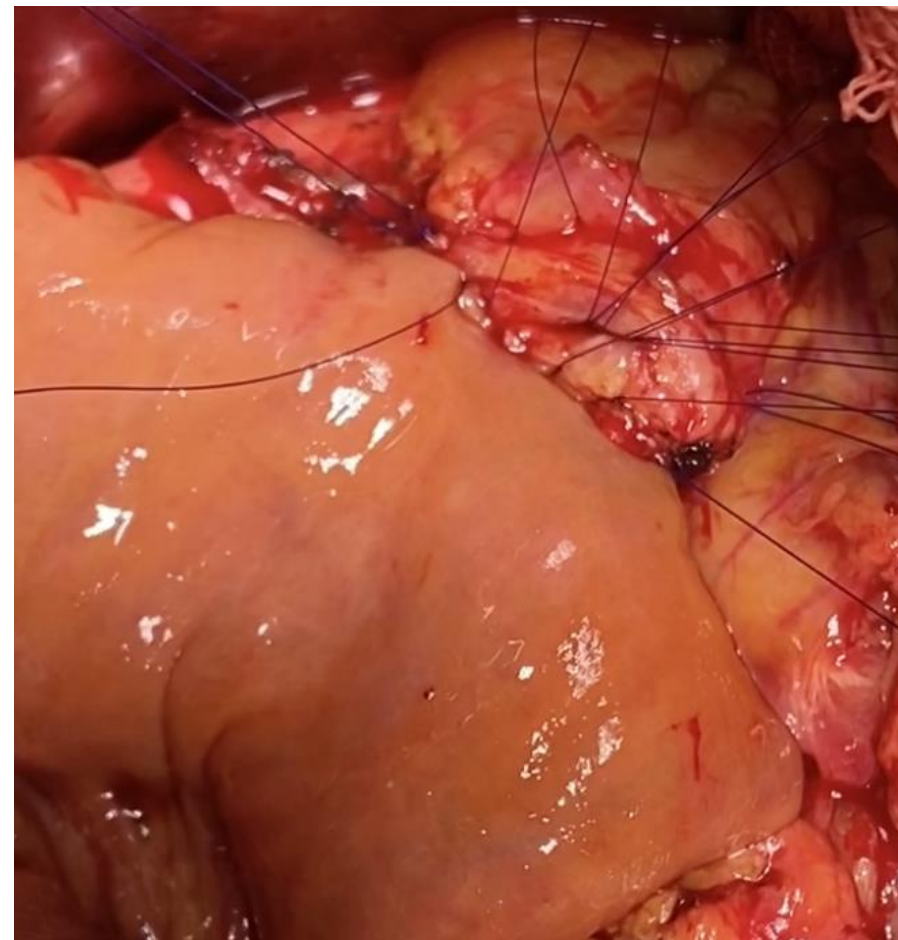
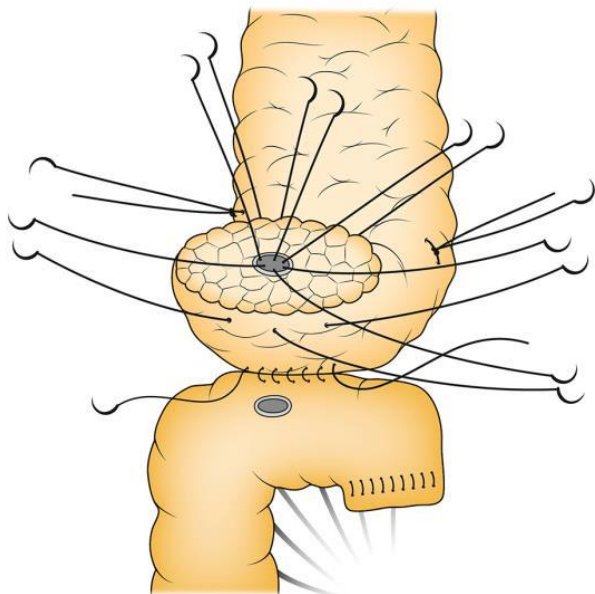
Paremchyma

1 cm

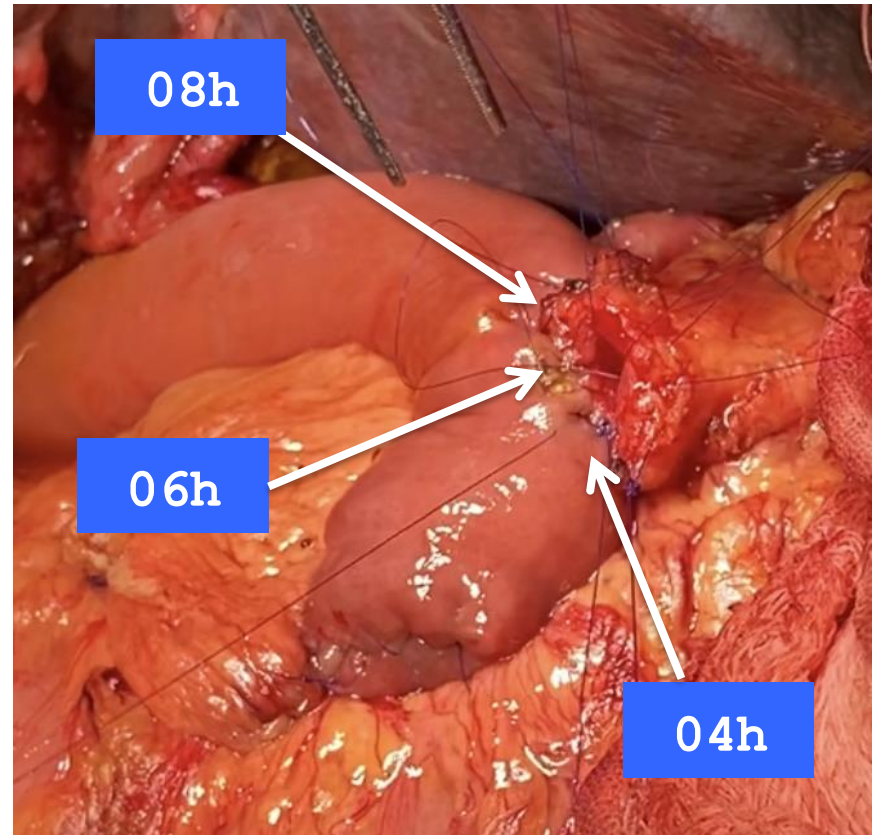
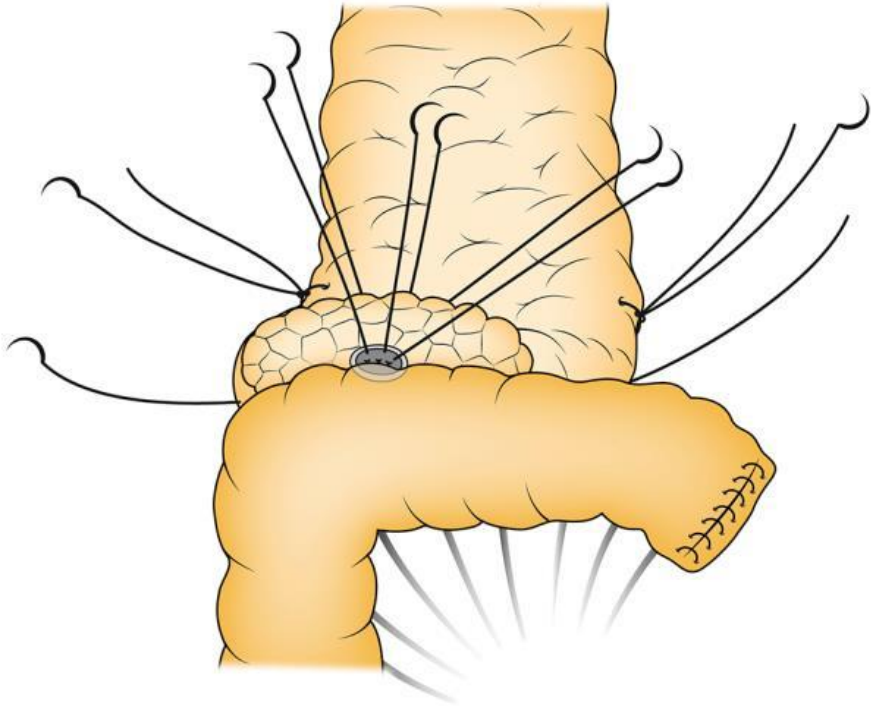




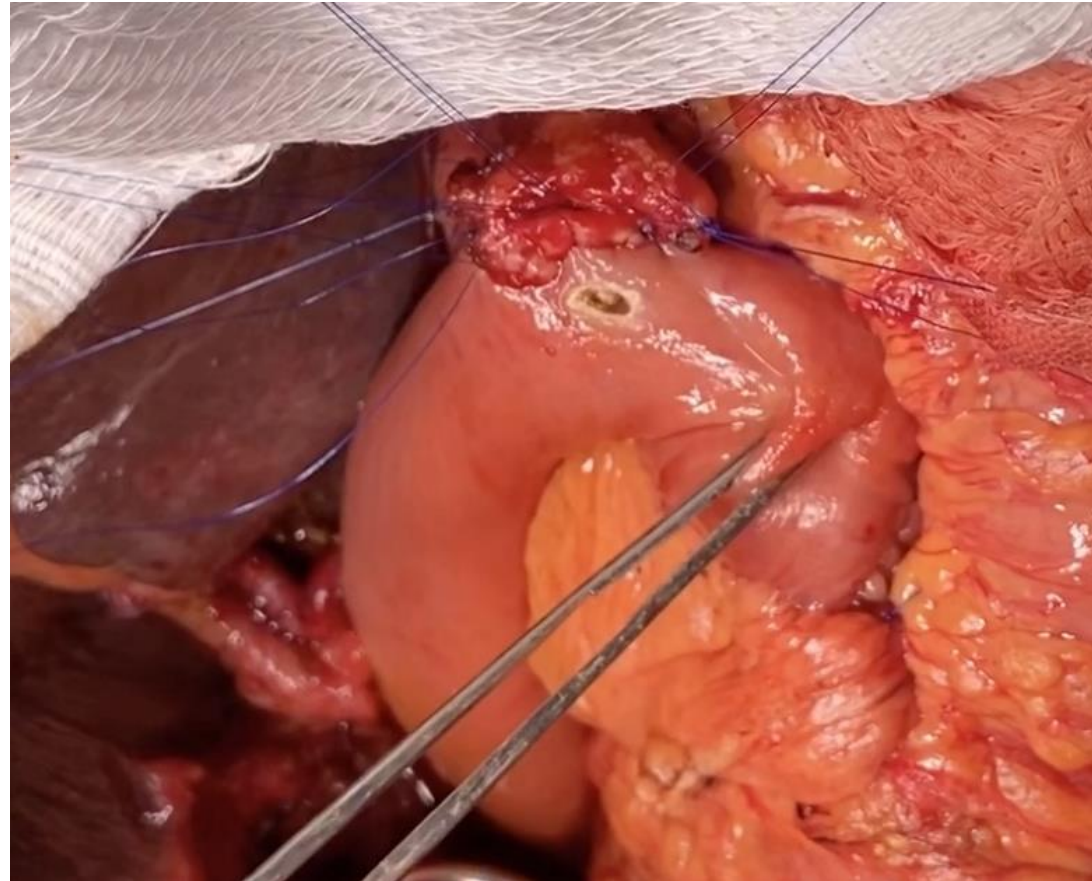
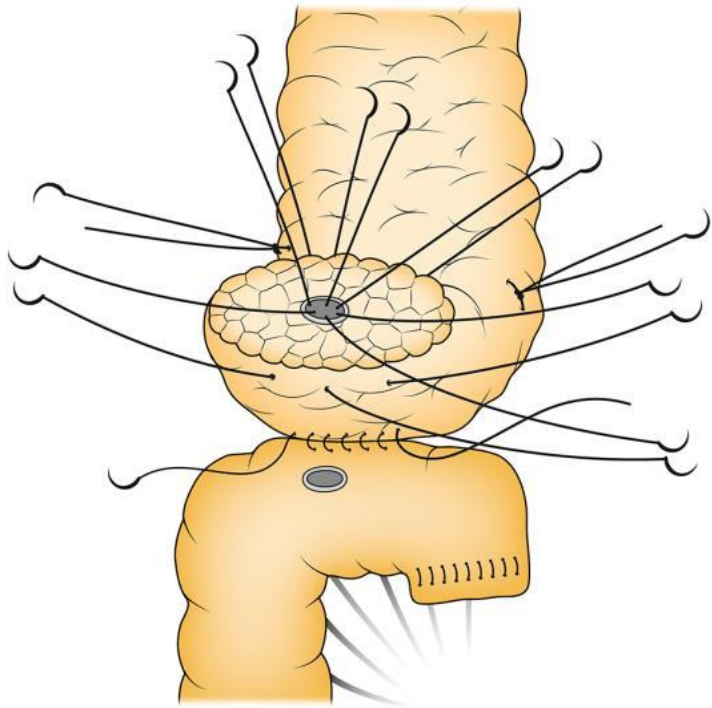
1. Running suture (posterior outer)



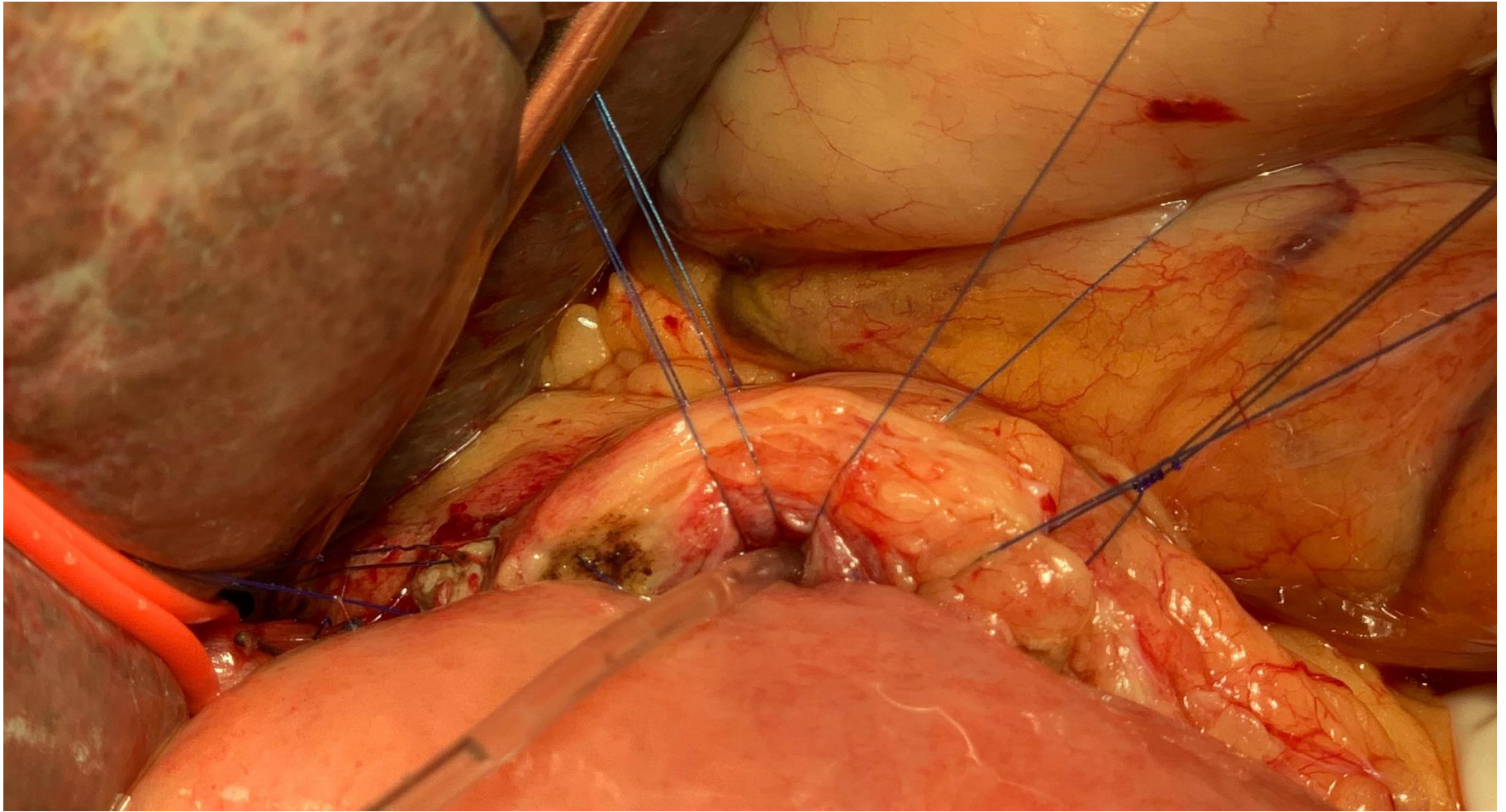
2. POSTERIOR INNER



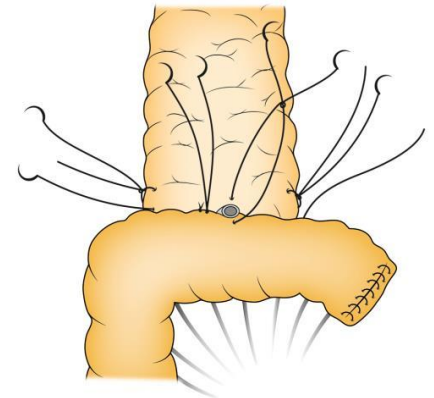
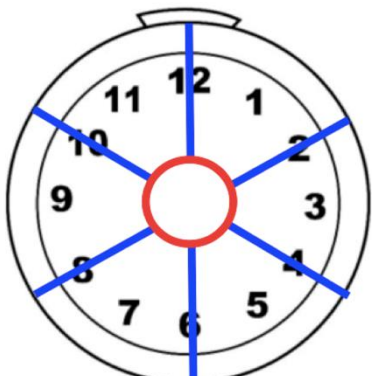
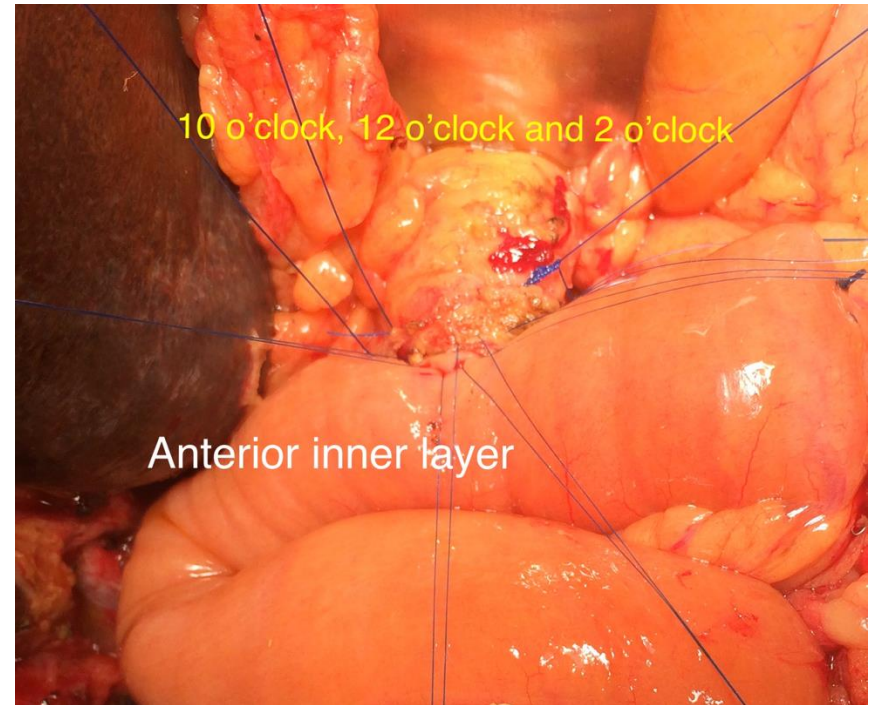
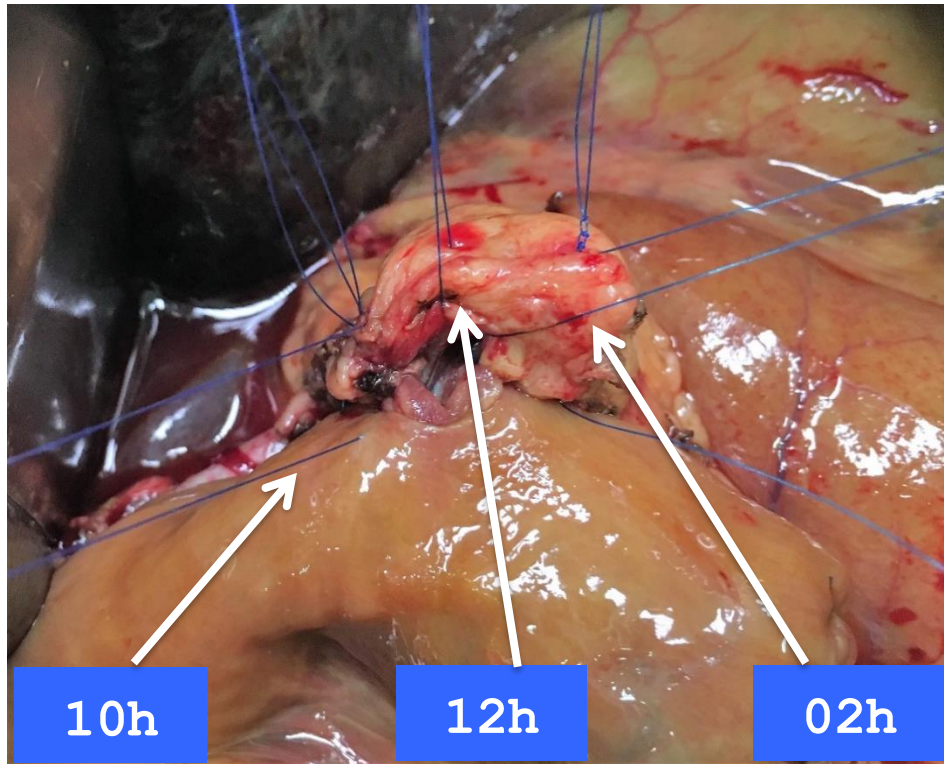
Small bowel is opened



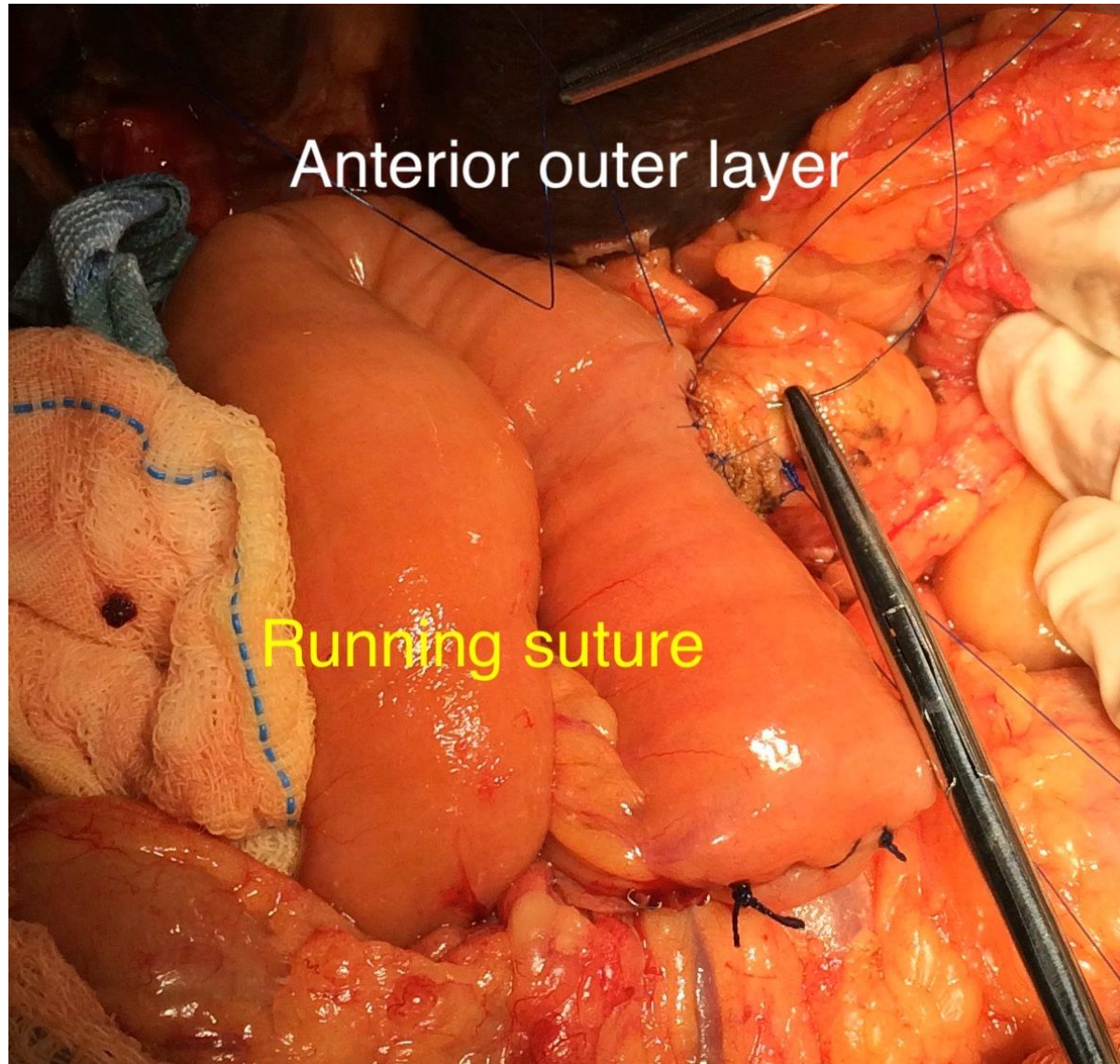
STENT INTO THE PANCREATIC DUCT



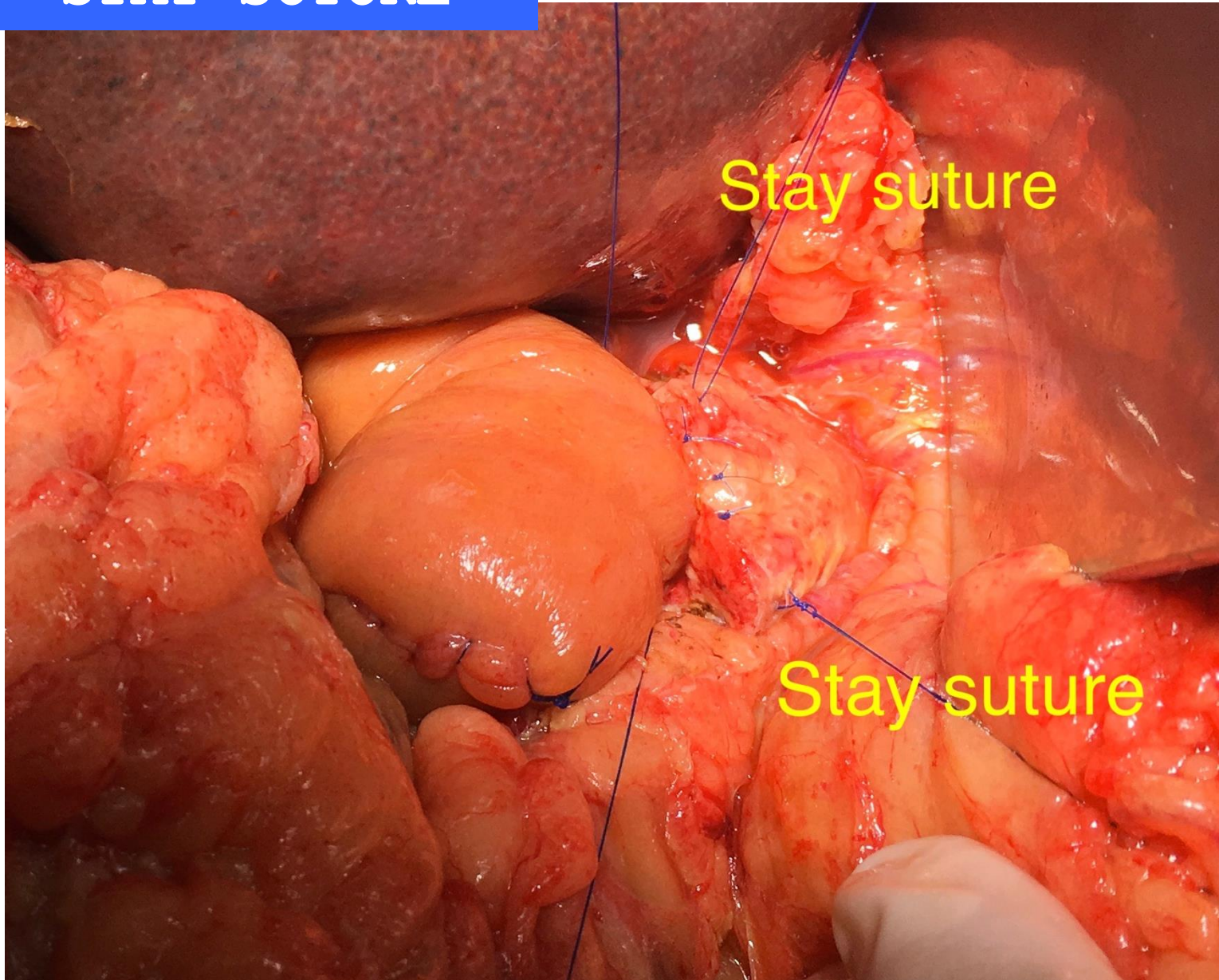
3. ANTERIOR INNER



4. ANTERIOR OUTER

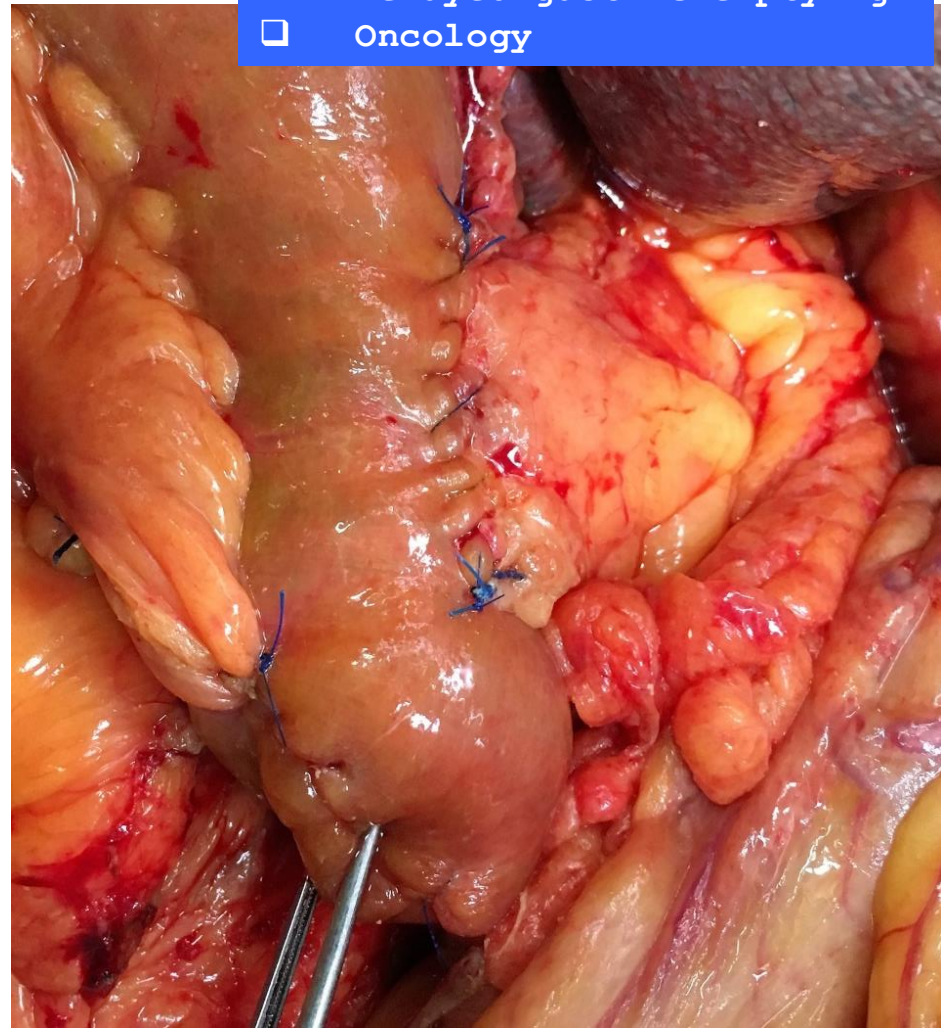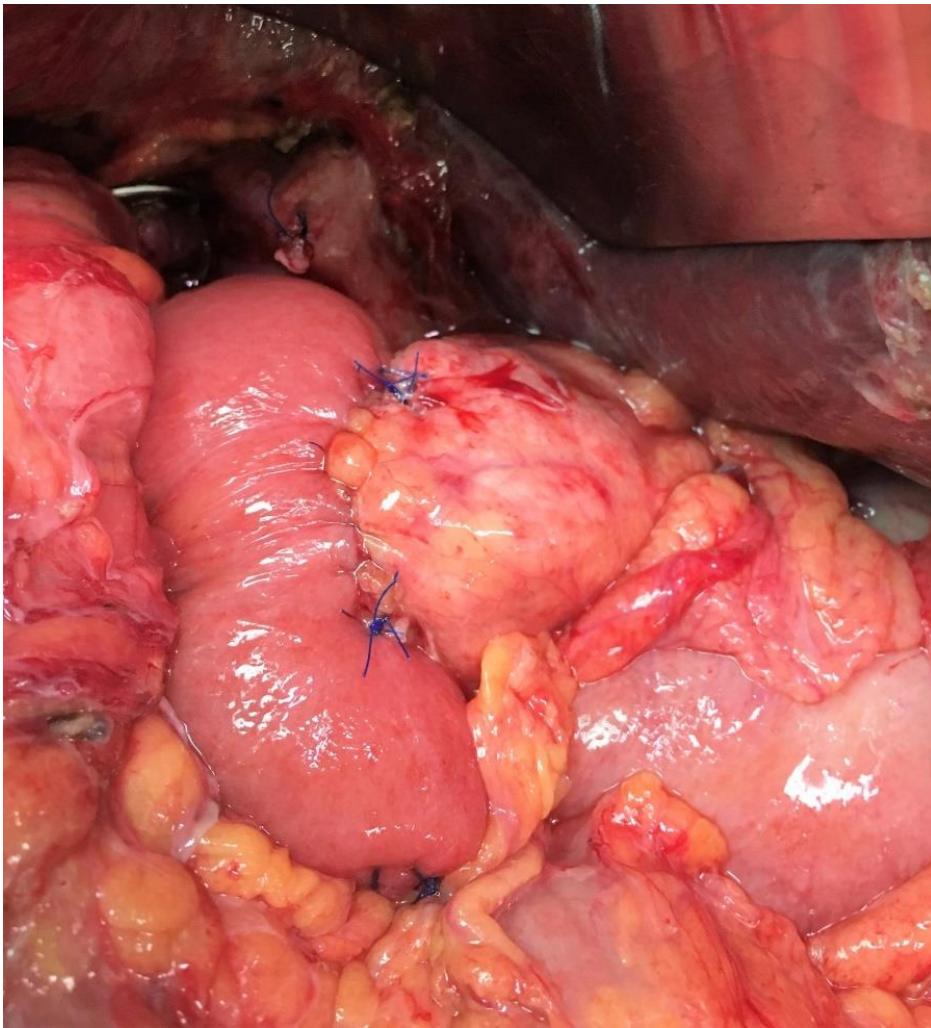


STAY SUTURE

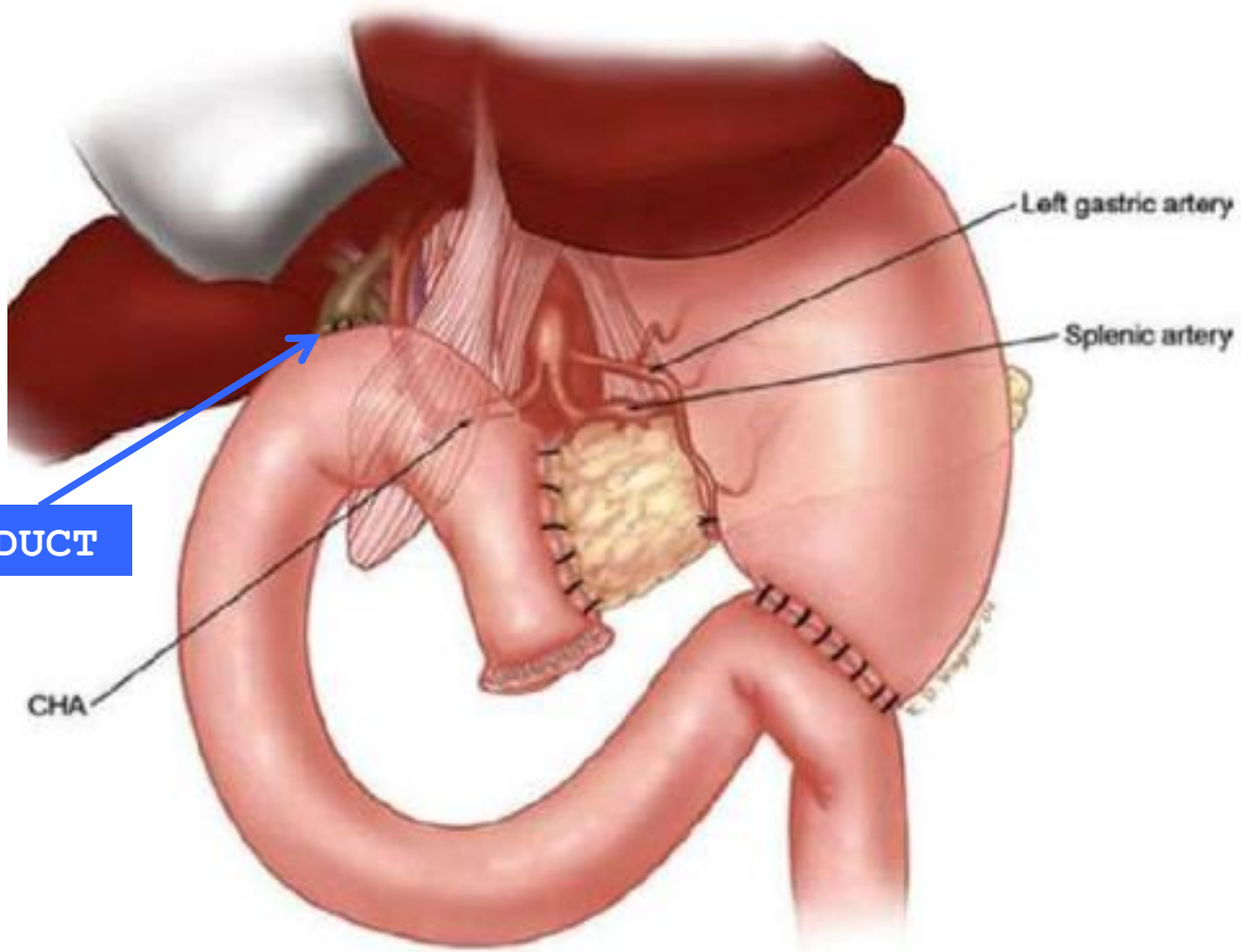


FINAL ASPECT

- Bleeding
- Pancreatic fistula
- Delayed gastric emptying
- Oncology

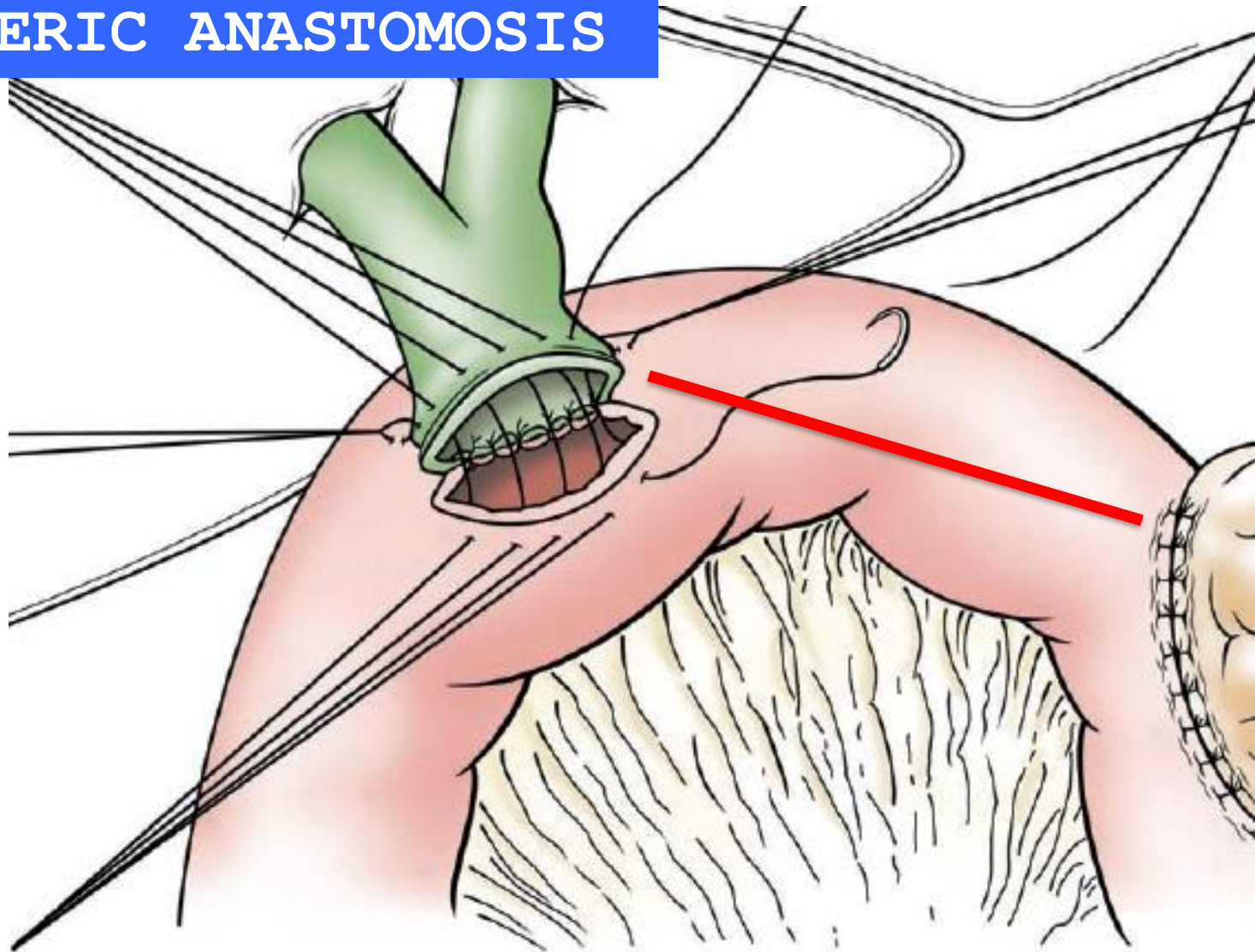


BILE ENTERIC ANASTOMOSIS

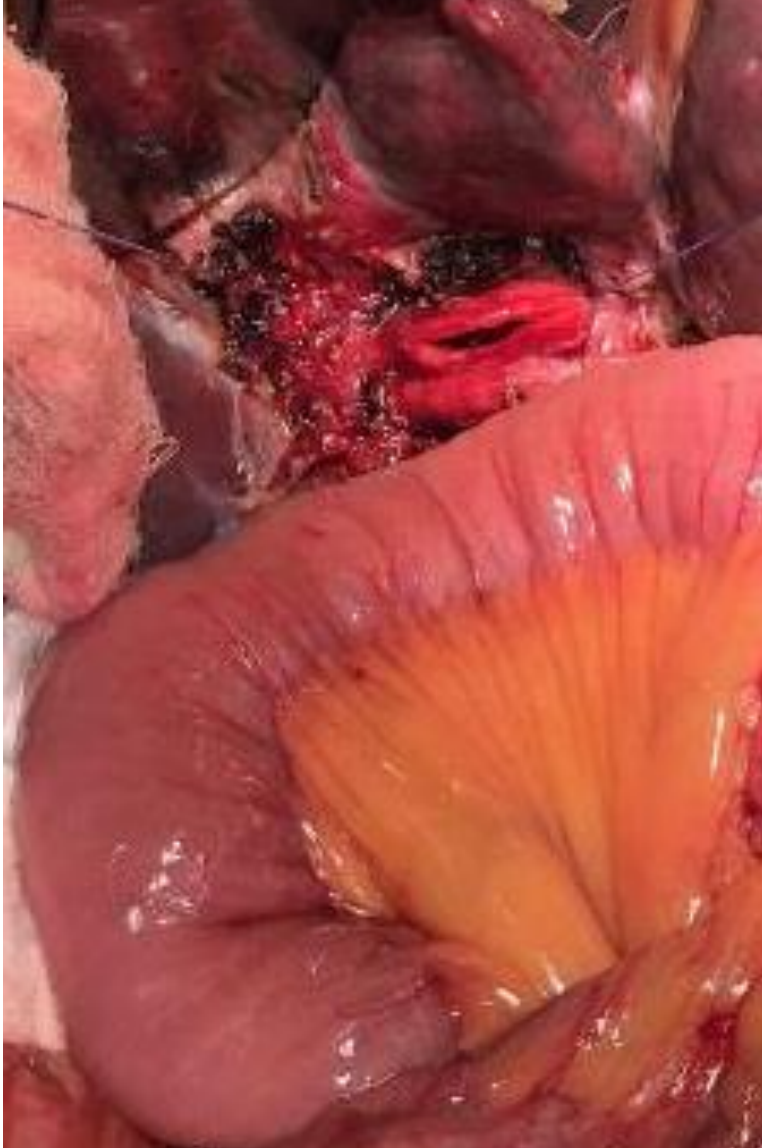

2. BILE DUCT

BILE ENTERIC ANASTOMOSIS

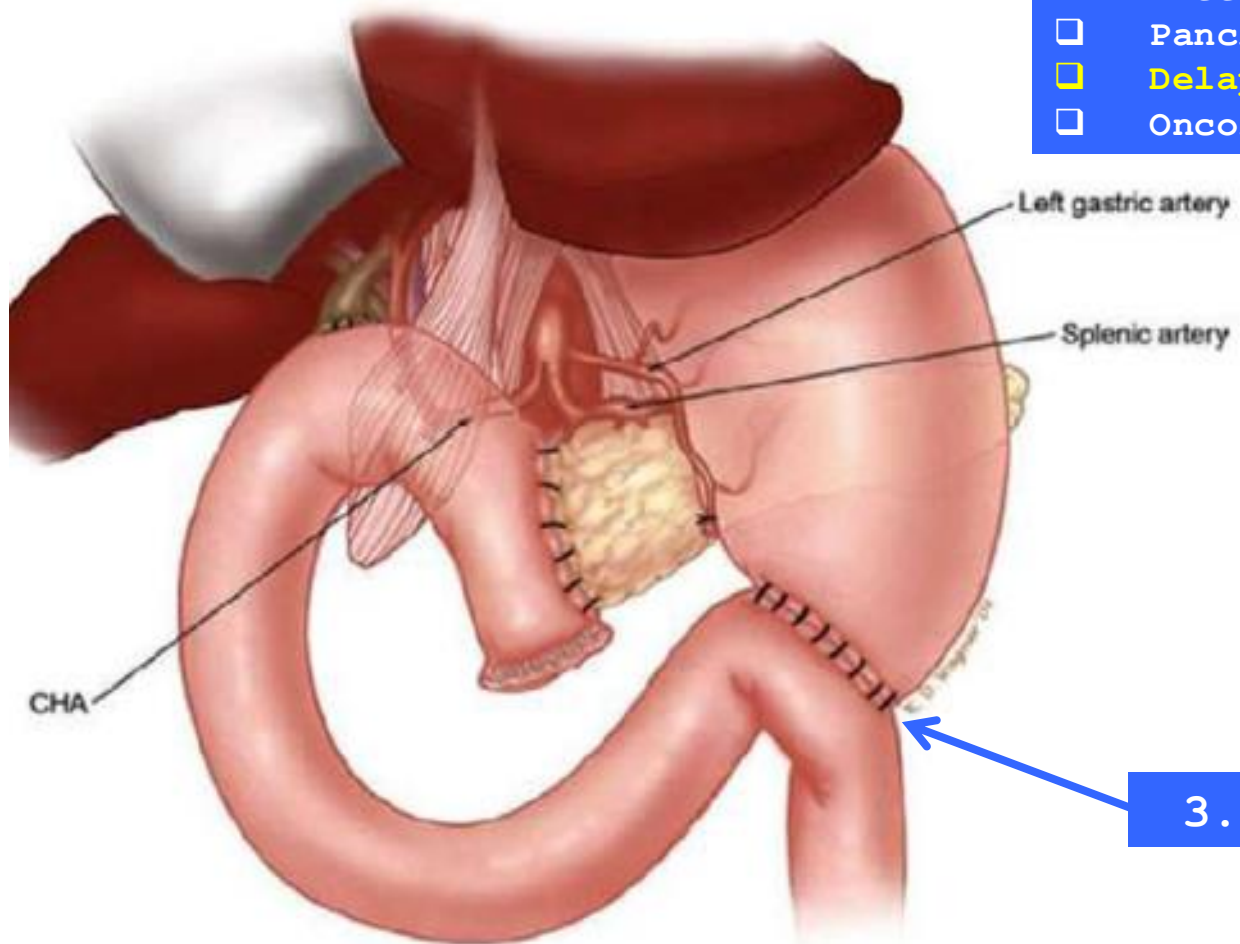


BILE ENTERIC ANASTOMOSIS



GASTRIC ANASTOMOSIS

- Bleeding
- Pancreatic fistula
- Delayed gastric emptying
- Oncology



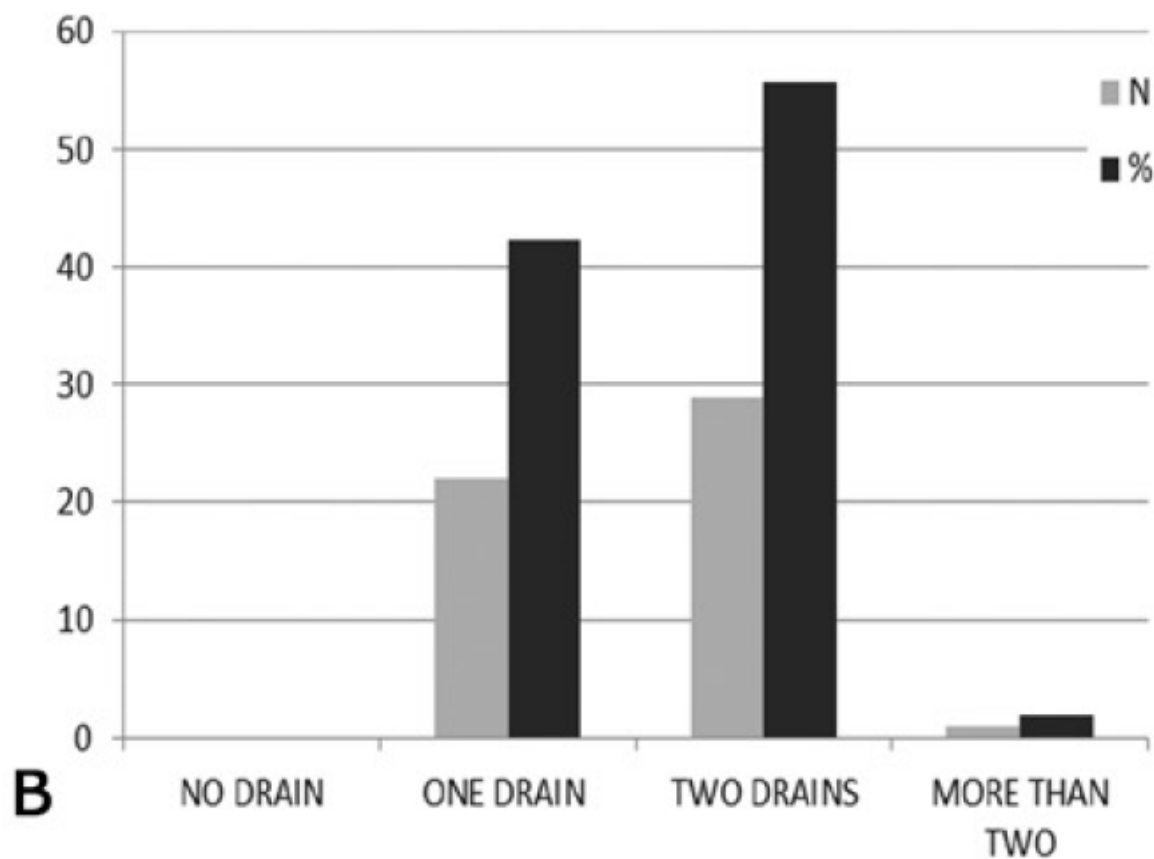
3. STOMACH

- Antecolic position

PANCREATODUODENECTOMY: BRAZILIAN PRACTICE PATTERNS*

*Duodenopancreatectomia: prática padrão do Brasil**

Orlando Jorge M TORRES¹, Eduardo de Souza M FERNANDES², Rodrigo Rodrigues VASQUES¹, Fabio Luís WAECHTER³, Paulo Cezar G. AMARAL⁴, Marcelo Bruno de REZENDE⁵, Roland Montenegro COSTA⁶, André Luís MONTAGNINI⁷



Thanks!



www.drortorres.com.br