

# Lymphadenectomy and mesopancreas resection for pancreatic ductal adenocarcinoma

Orlando Jorge M Torres  
Serviço de Cirurgia do Aparelho Digestivo  
Unidade Hepatopancreatobiliar - UFMA

# LYMPHATICS

## Lymph node stations pancreatic cancer

□ Hepatoduodenal ligament  
12a, 12b1, 12b2, 12p, 12c

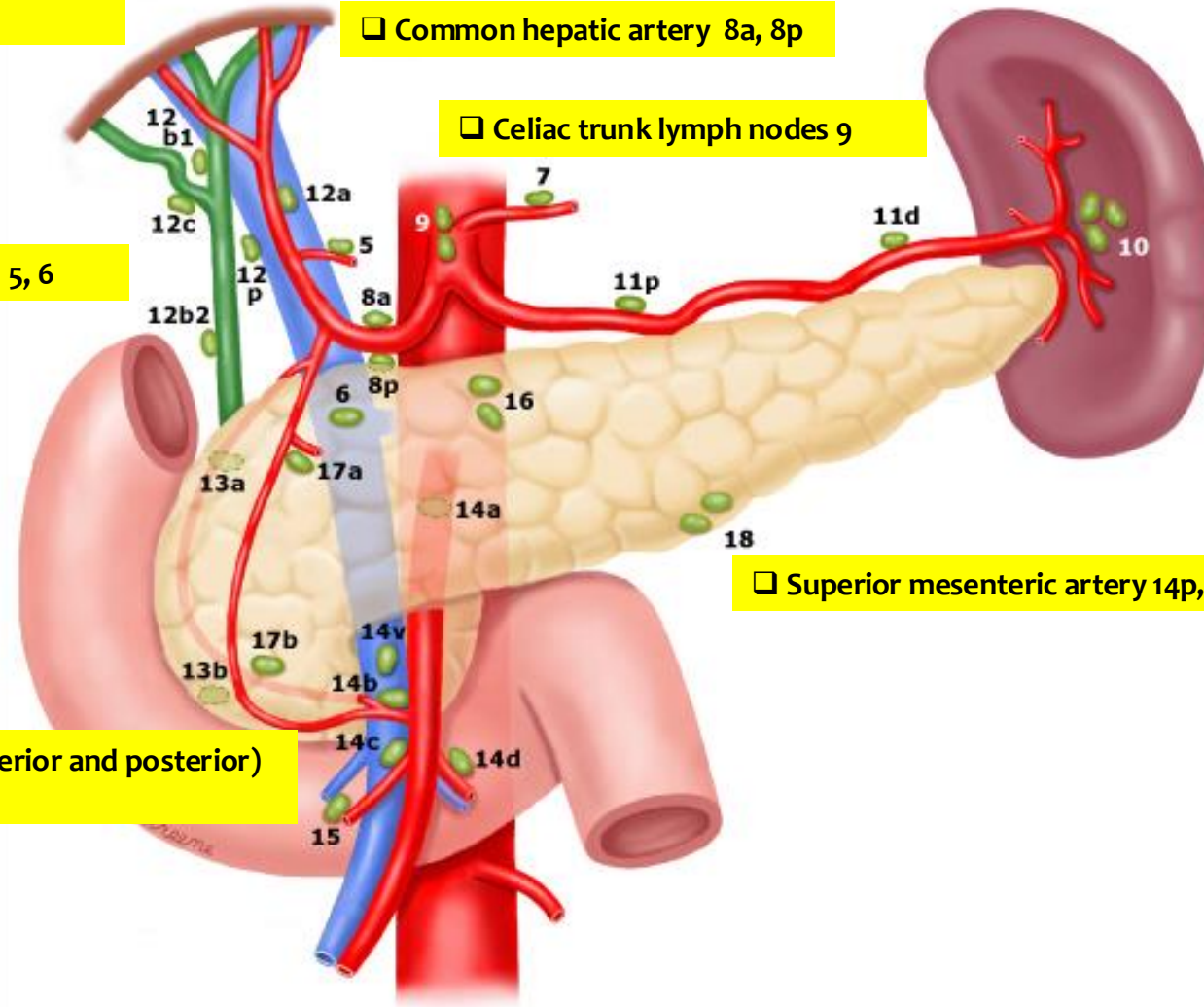
□ Common hepatic artery 8a, 8p

□ Celiac trunk lymph nodes 9

□ Pyloric 5, 6

□ Superior mesenteric artery 14p, 14d

□ Pancreatoduodenal (anterior and posterior)  
13a, 13b, 17a, 17b



# LYMPHATICS

□ Hepatoduodenal ligament  
12a, 12b1, 12b2, 12p, 12c

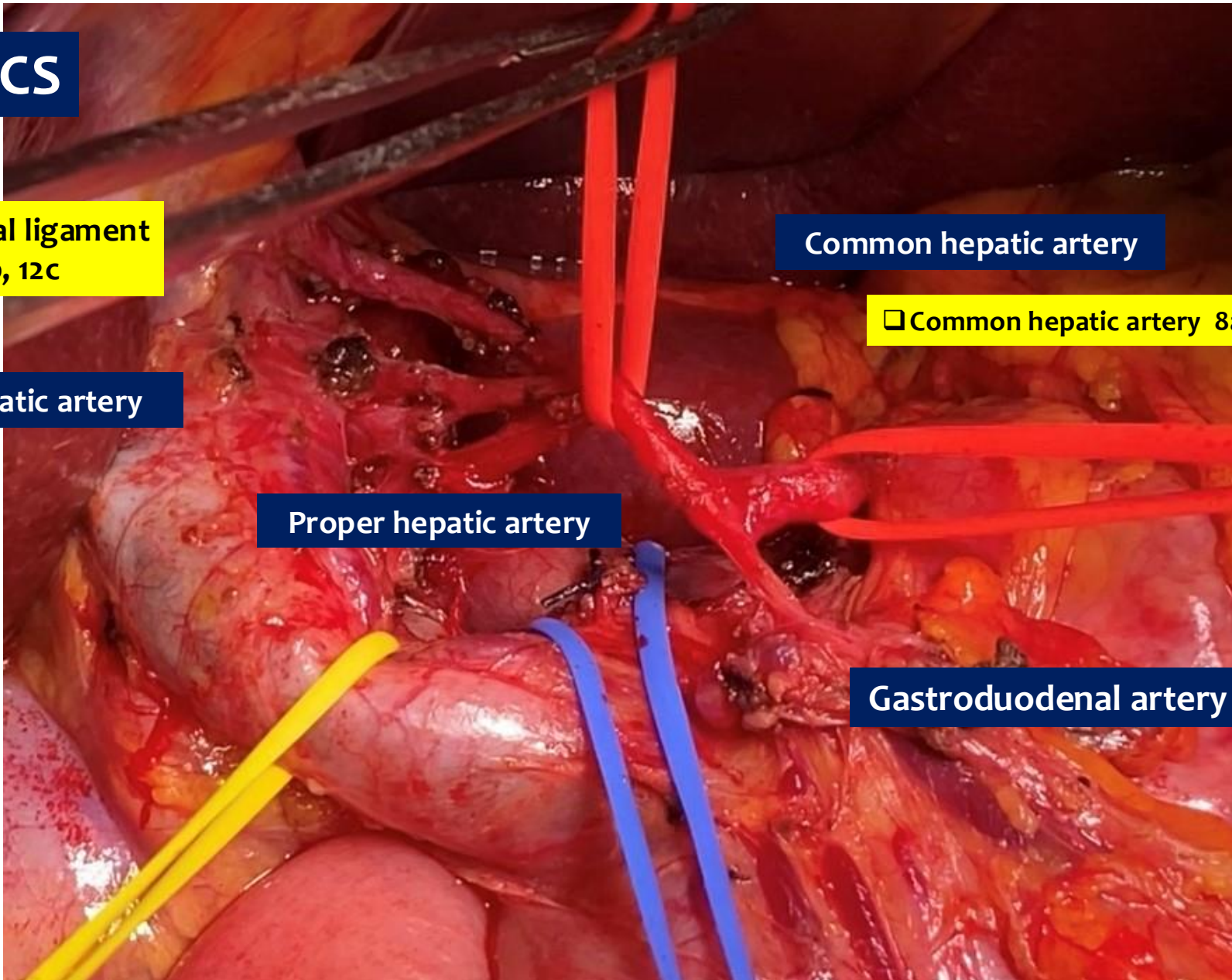
Right hepatic artery

Proper hepatic artery

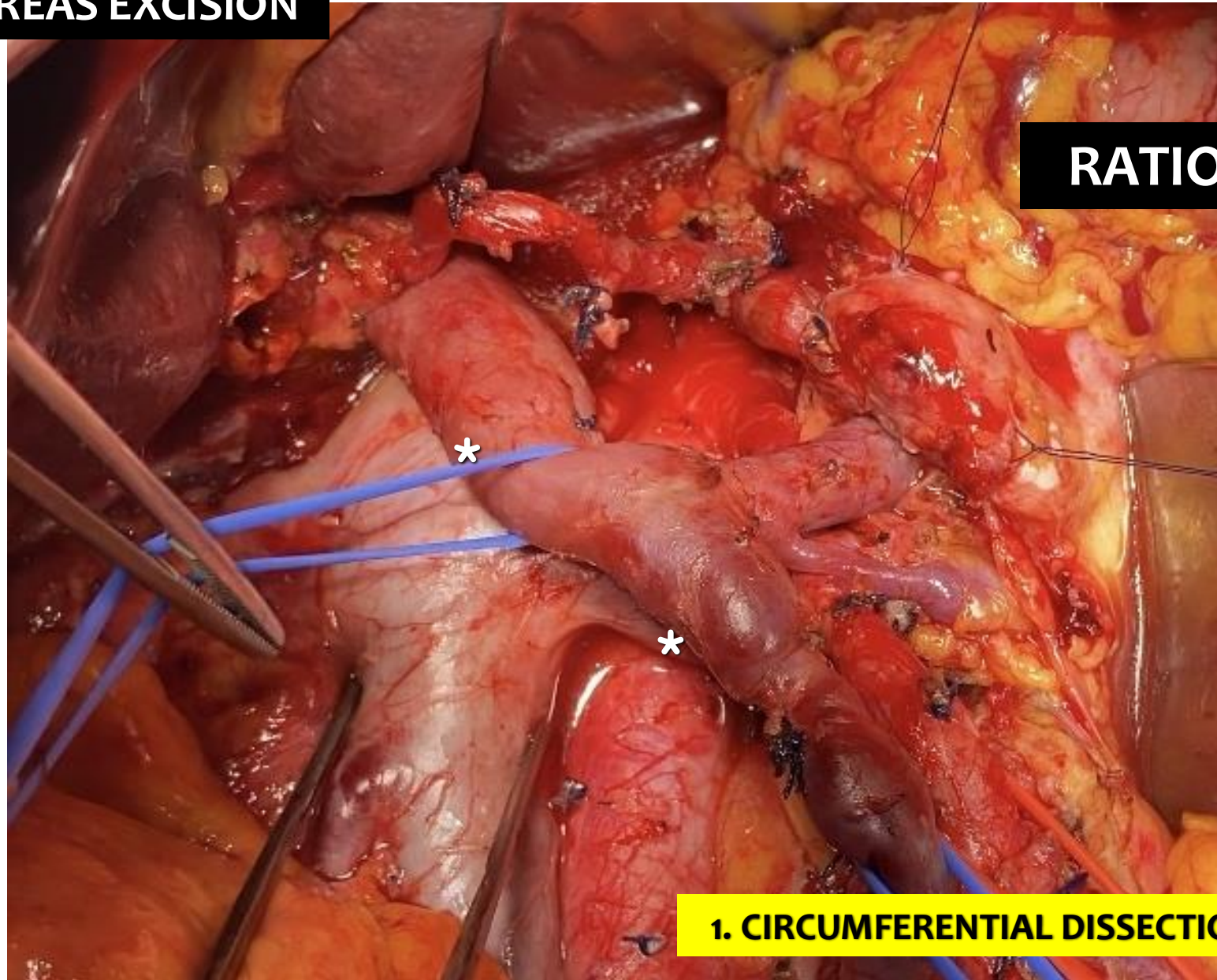
Common hepatic artery

□ Common hepatic artery 8a, 8p

Gastroduodenal artery (GDA)



# TOTAL MESOPANCREAS EXCISION

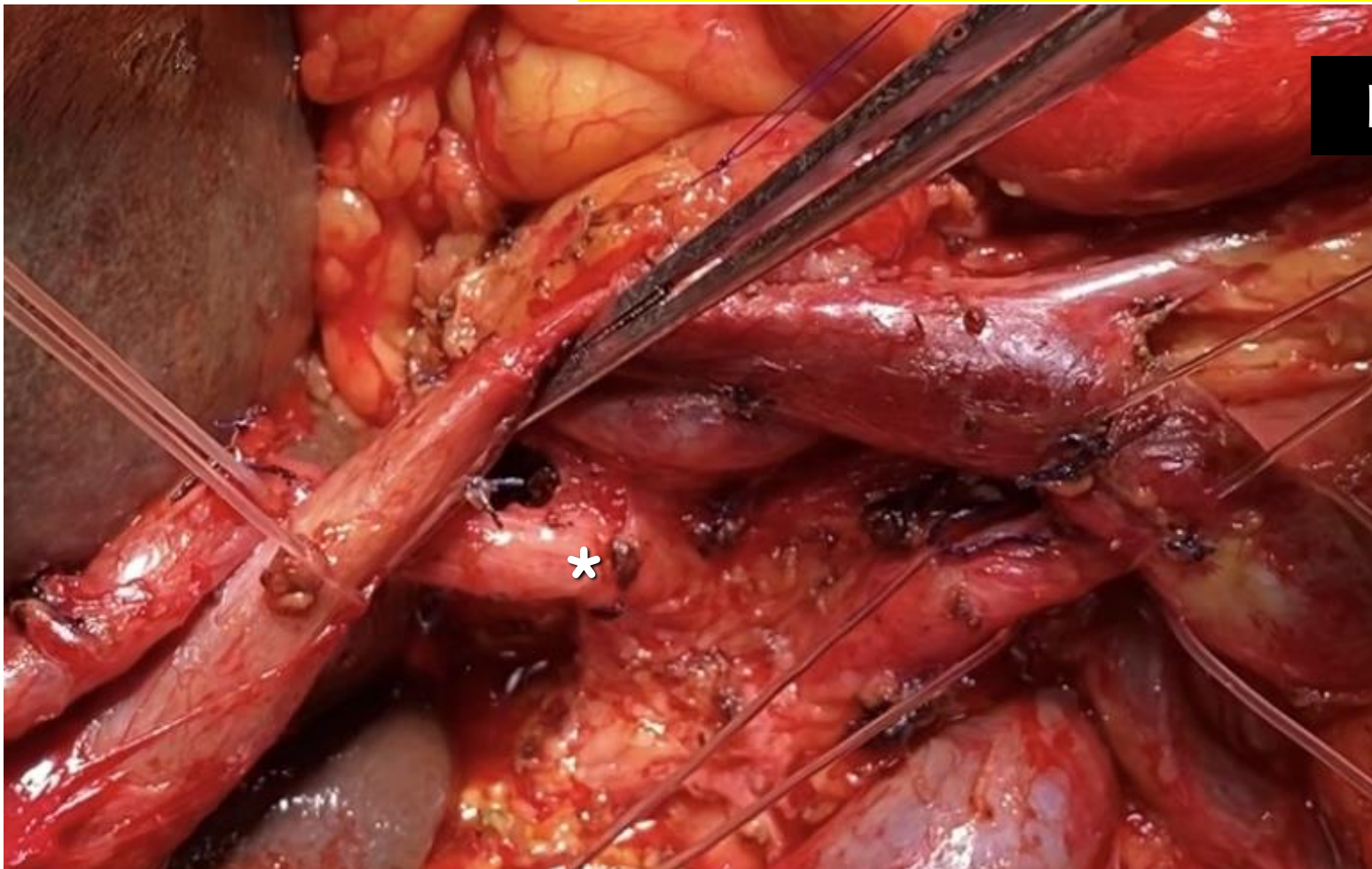

**RATIONAL**

**1. CIRCUMFERENTIAL DISSECTION OF SMV/PV**

# TOTAL MESOPANCREAS EXCISION

□ Common hepatic artery lymph nodes 8a, 8p



**RATIONAL**

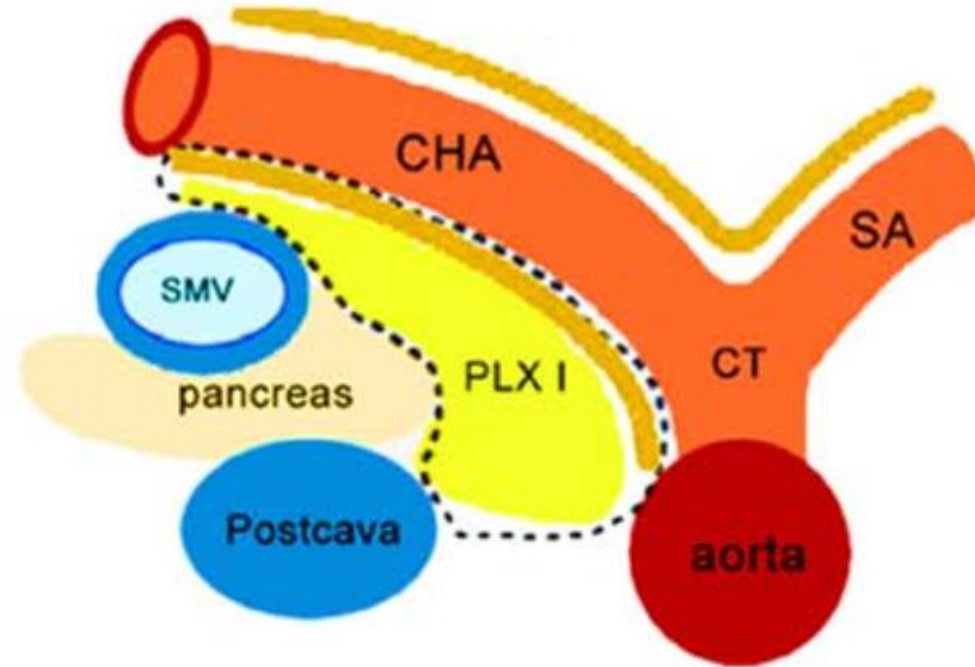
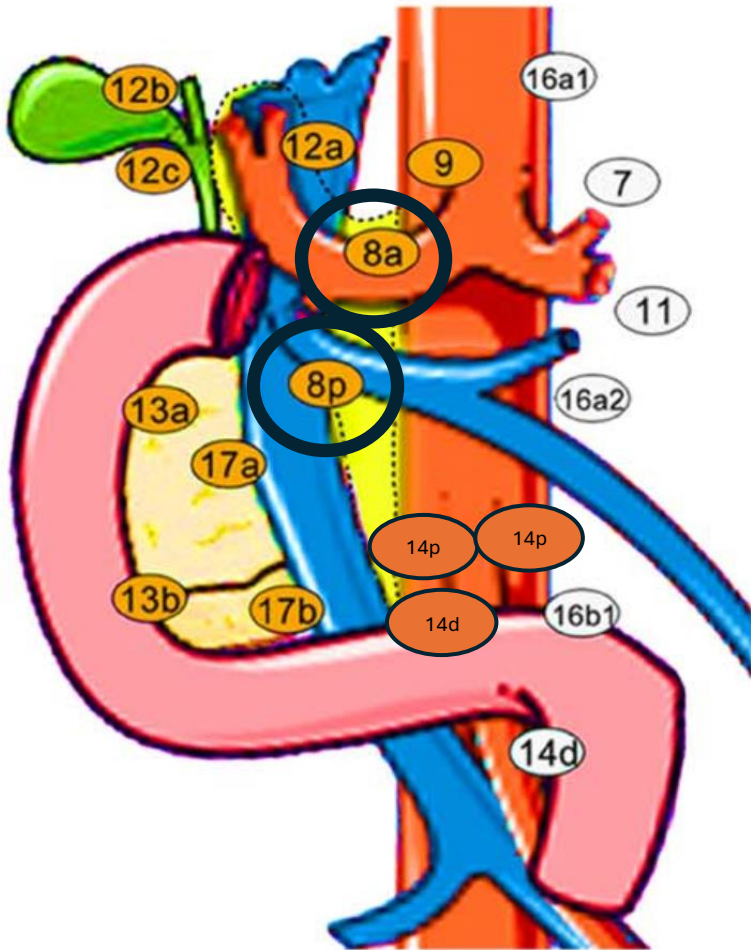
**2. HEMICIRCUMFERENTIAL DISSECTION OF CHA**

# COMMON HEPATIC ARTERY LYMPH NODES

□8a

□8p

A

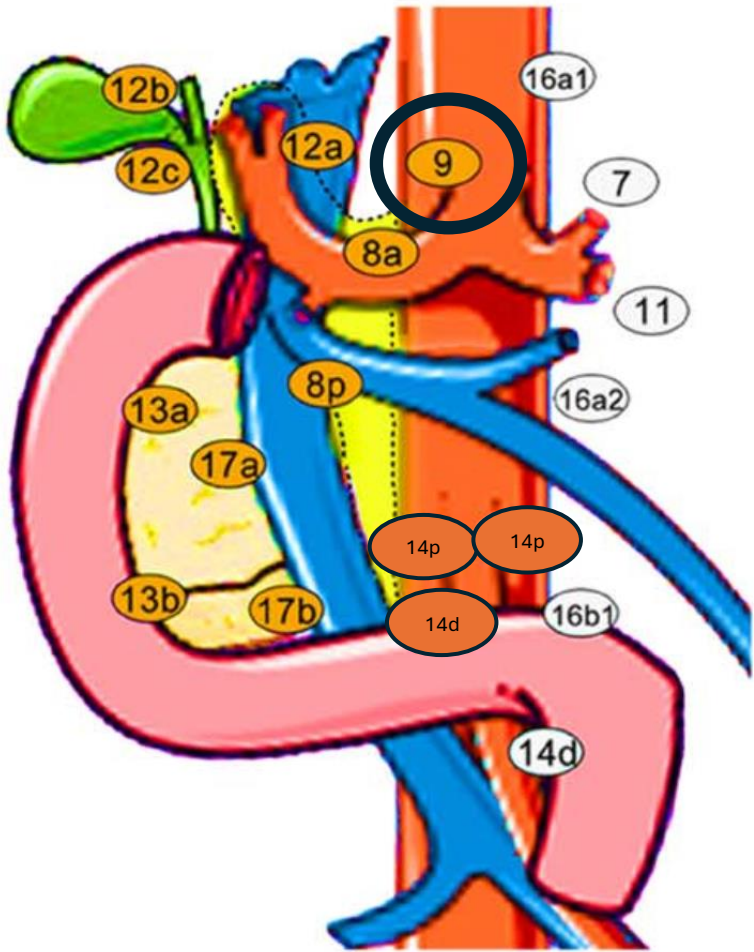


## 2. HEMICIRCUMFERENTIAL DISSECTION OF CHA

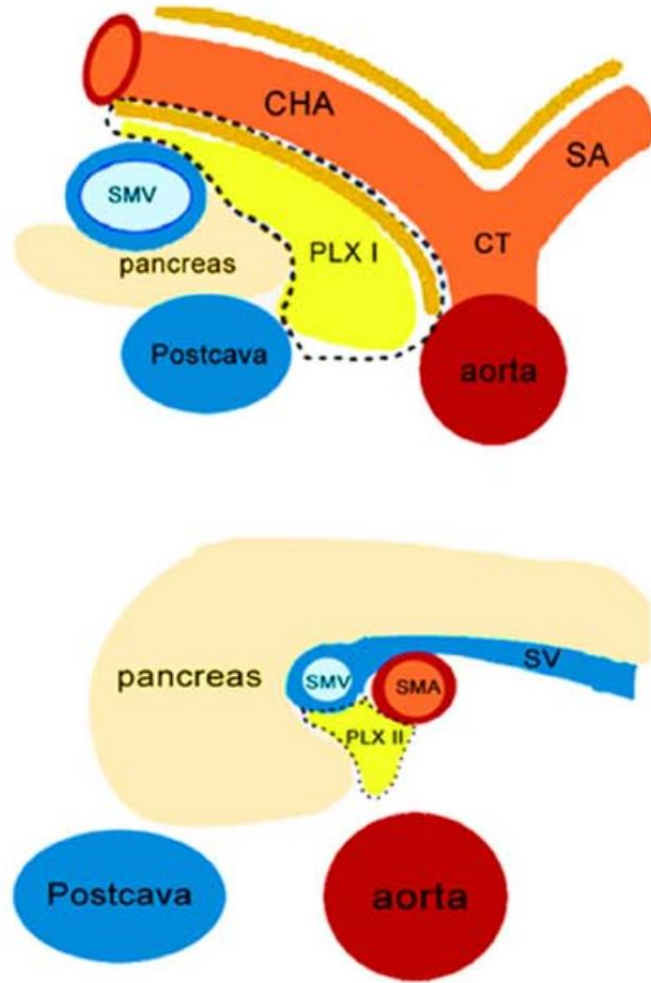
# CELIAC TRUNK LYMPH NODES

## ☐ Celiac trunk lymph nodes 9

A

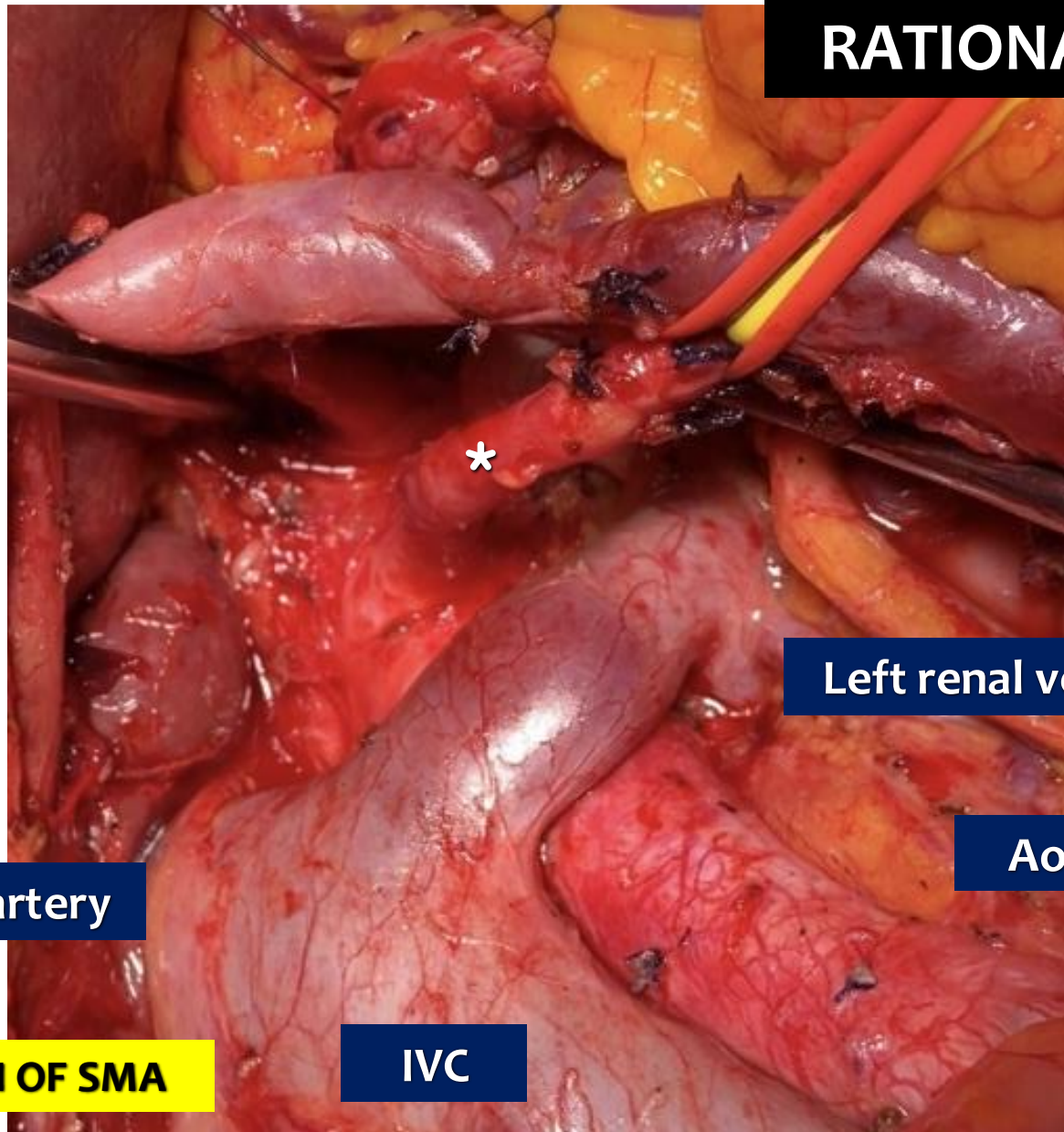
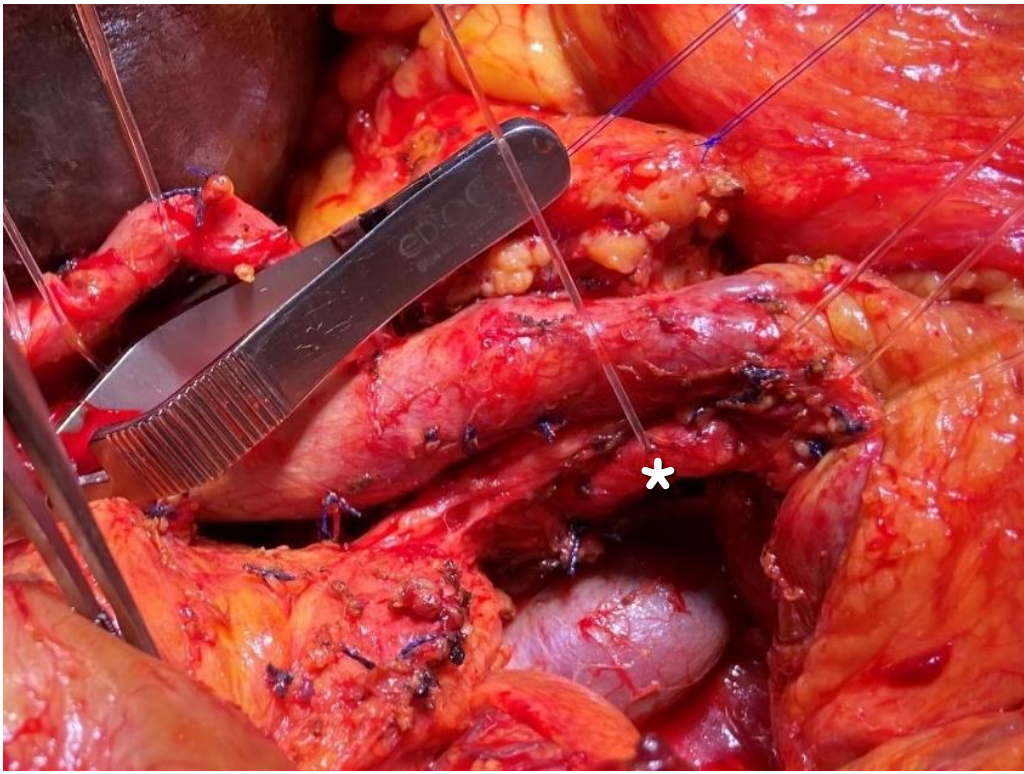


☐ 9



# TOTAL MESOPANCREAS EXCISION

**RATIONAL**



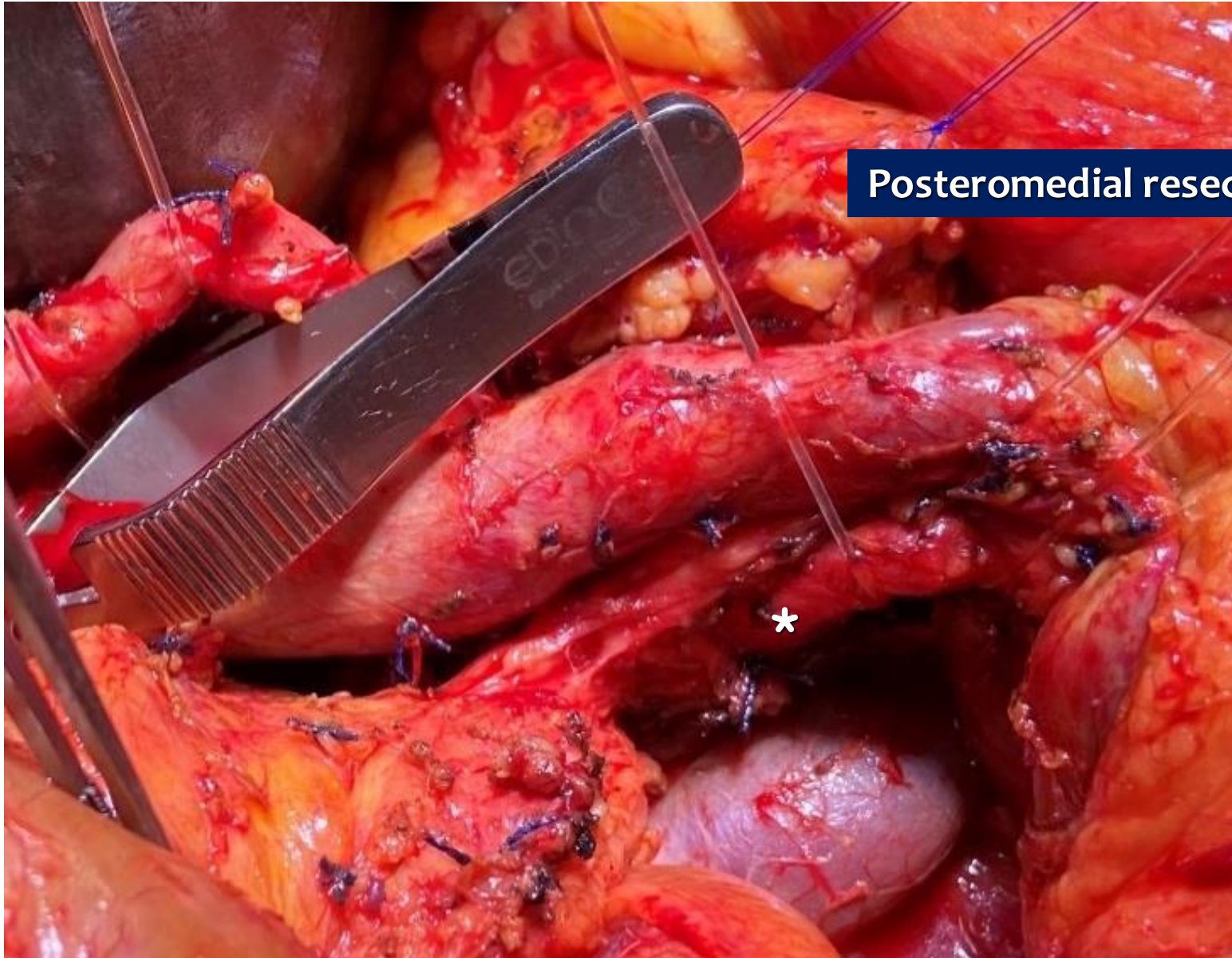**Superior mesenteric artery**

**Left renal vein**

**Aorta**

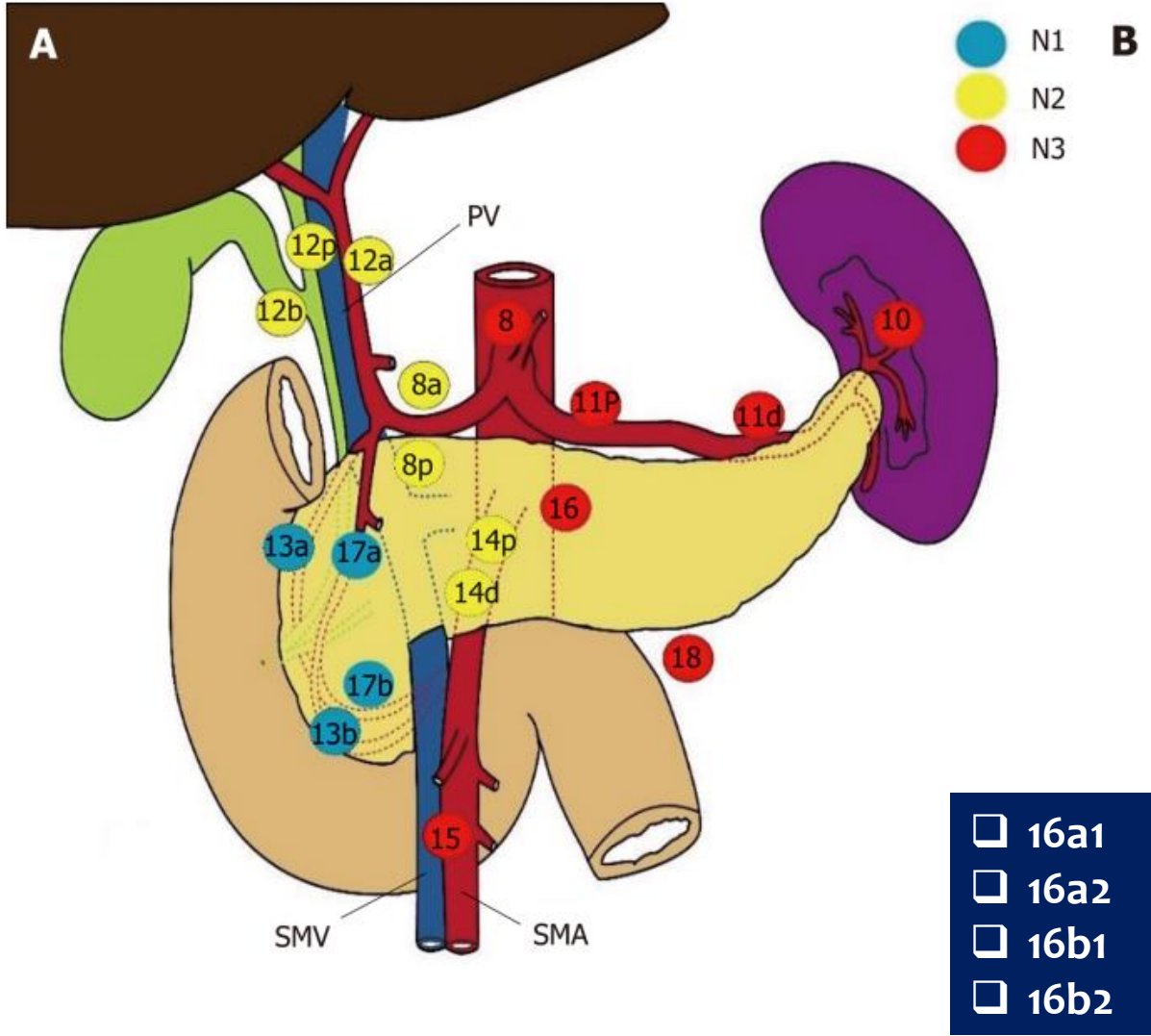
**3. HEMICIRCUMFERENTIAL DISSECTION OF SMA**

**IVC**

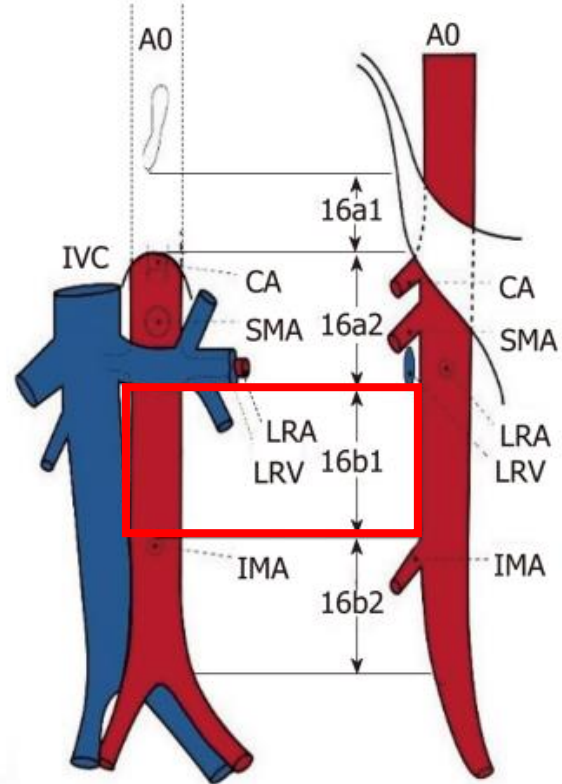


Posteromedial resection margin

# LYMPHATICS



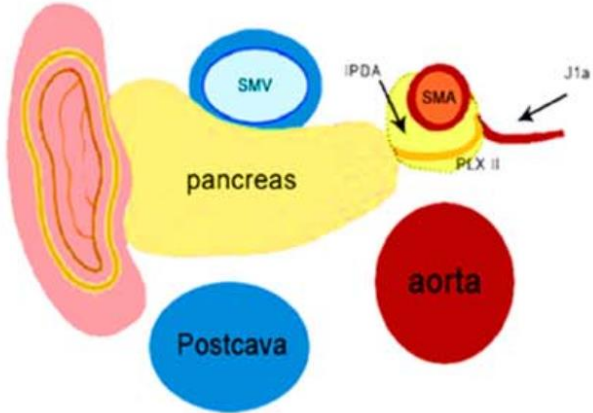
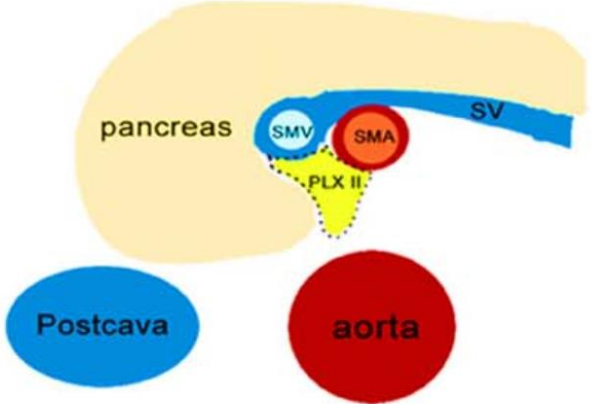
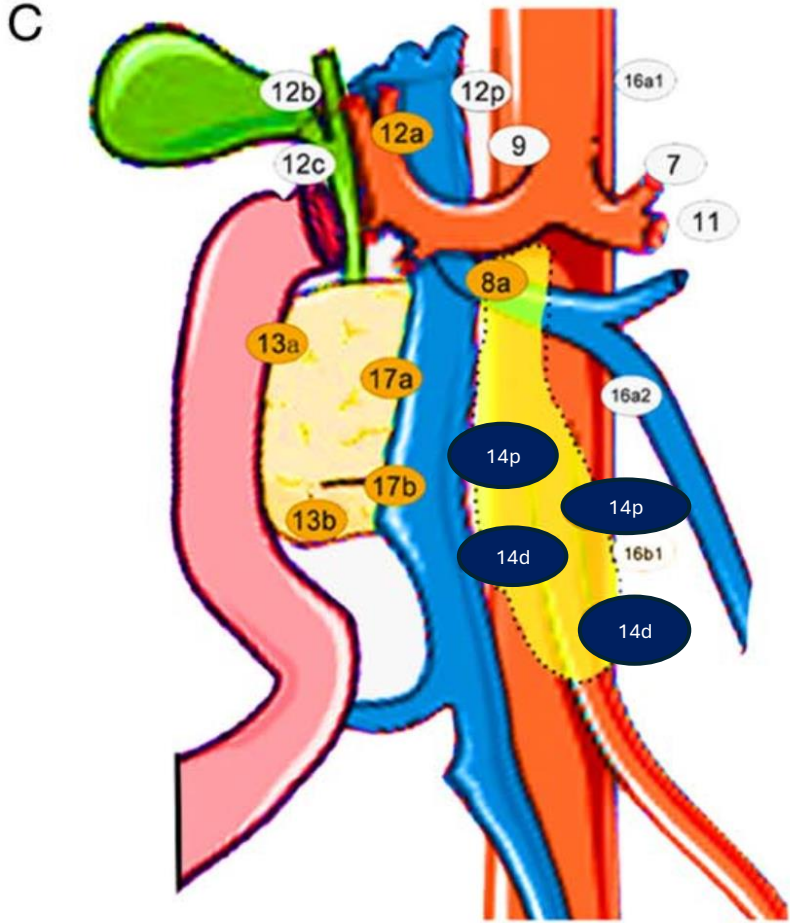
## □ 16b1 lymph nodes



# SUPERIOR MESENTERIC ARTERY LYMPH NODES

□14p

□14d



# STATE OF THE ART

## Pancreatoduodenectomy

Total mesopancreas excision'  
“Artery first”<sup>2</sup>

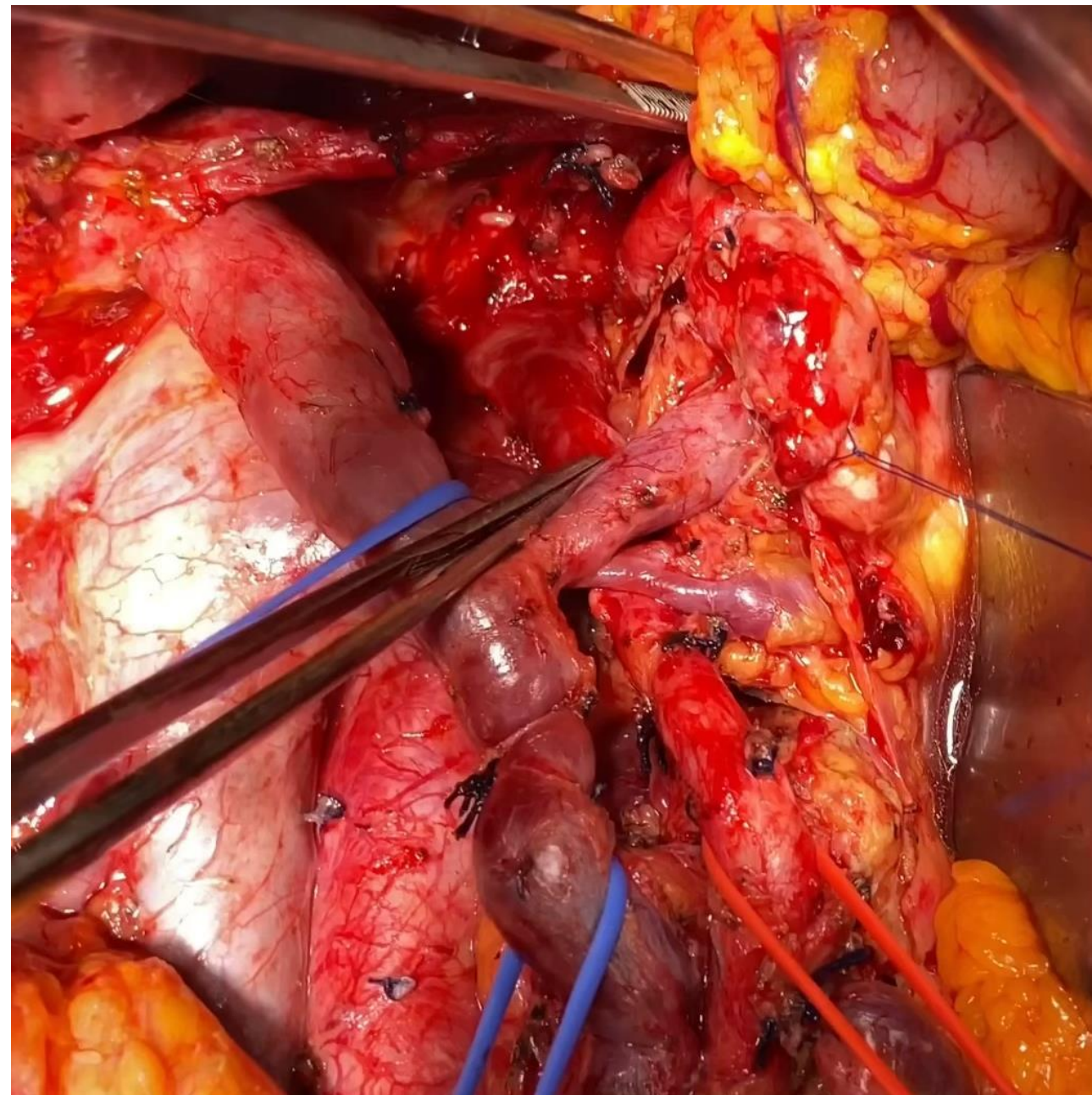
Level 3 dissection<sup>3</sup>

“Triangle operation”<sup>4</sup>

Extended resection<sup>5</sup>

+/- portal/SM vein

Liver metastasis



1. Fernandes ES, et al. Langenbecks Arch Surg 2021

2. Inoue Y, et al. J Gastrointest Surg 2018

3. Niesen W, et al. Ann Gastroenterol Surg. 2019

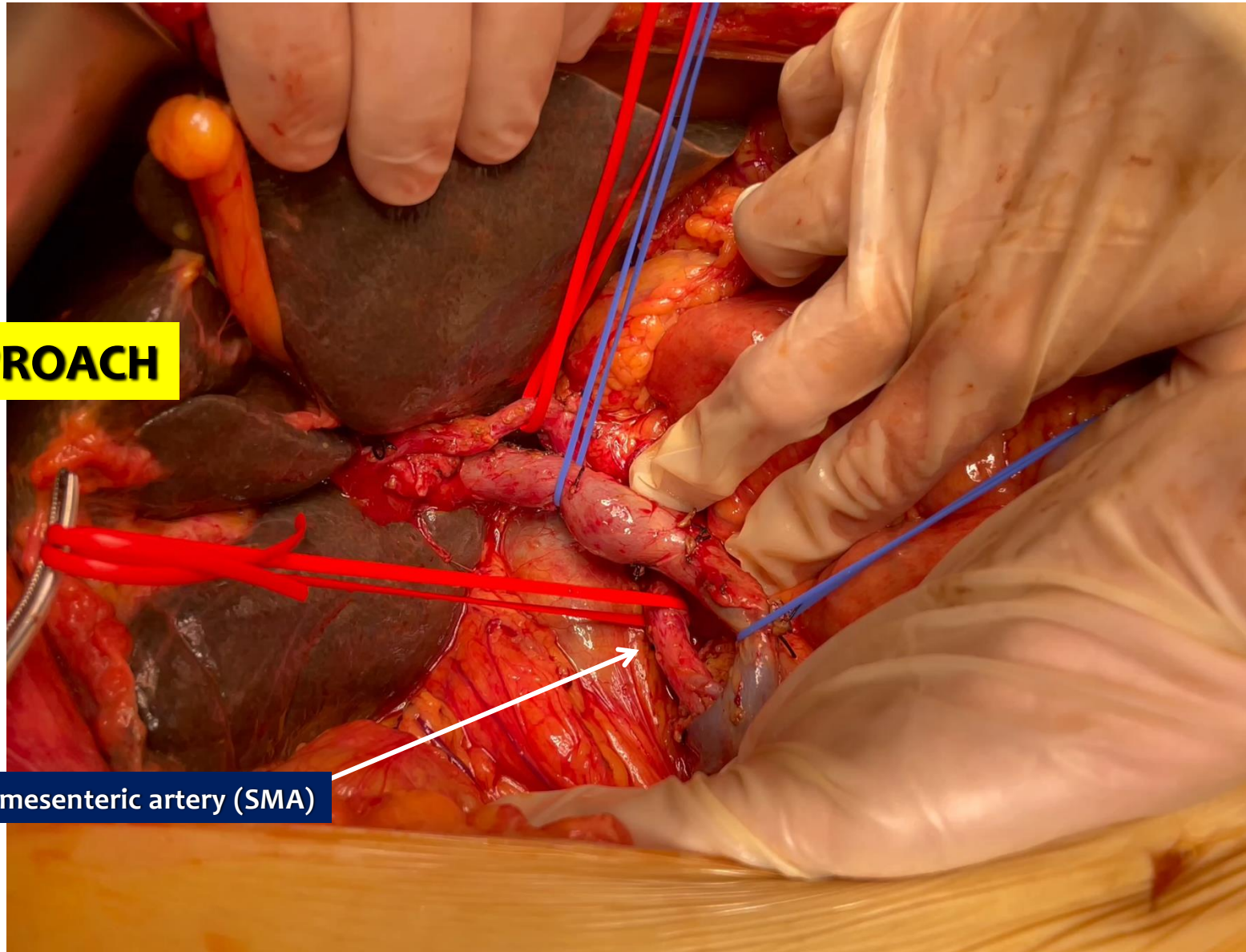
4. Hackert T, et al. HPB 2017

5. Fernandes ES, et al. J Gastrointest Oncol 2023

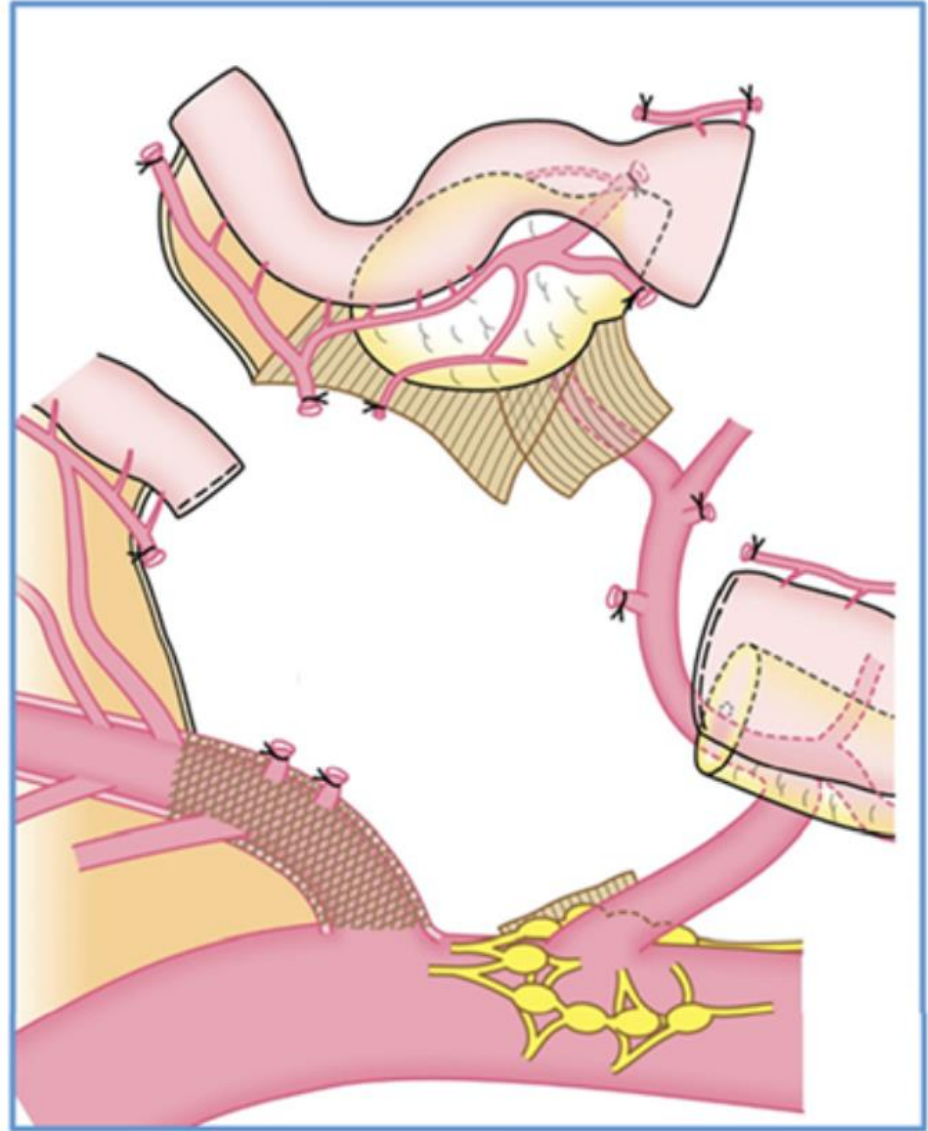
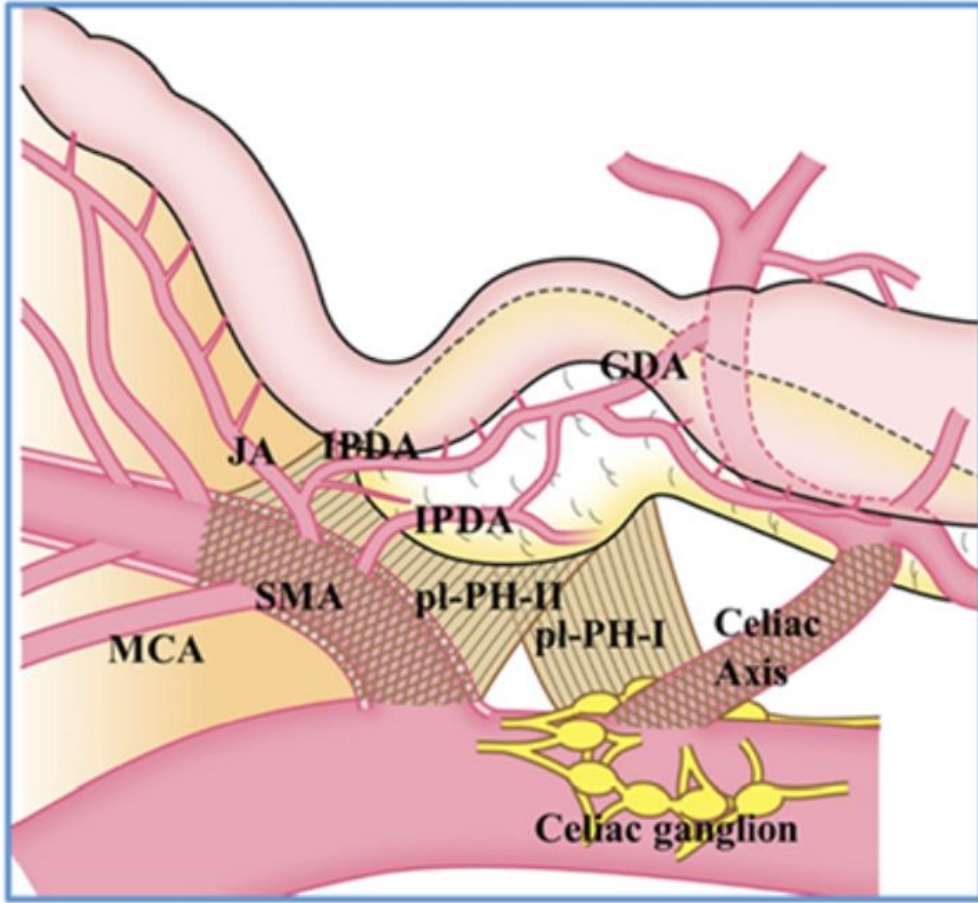
6. Torres OJ, Zurich and Cape Town

**ARTERY FIRST**

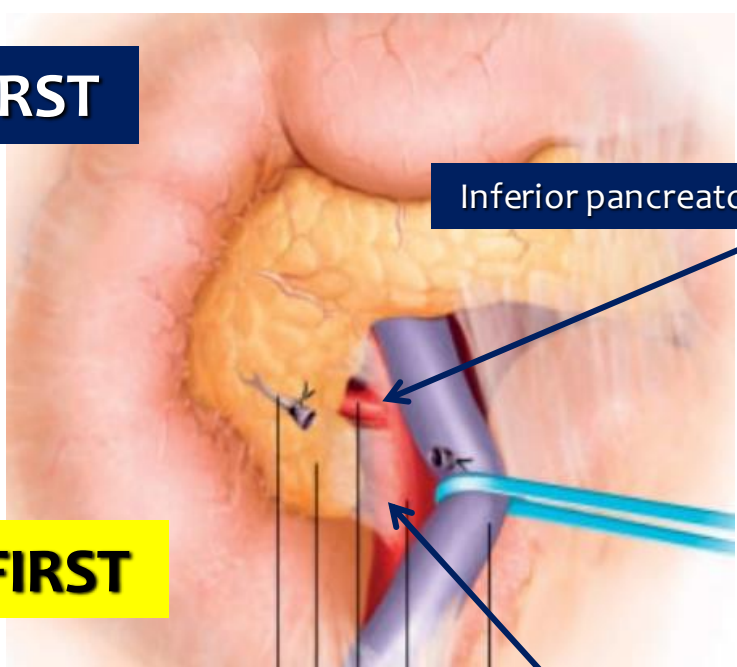
**POSTERIOR APPROACH**



**Superior mesenteric artery (SMA)**

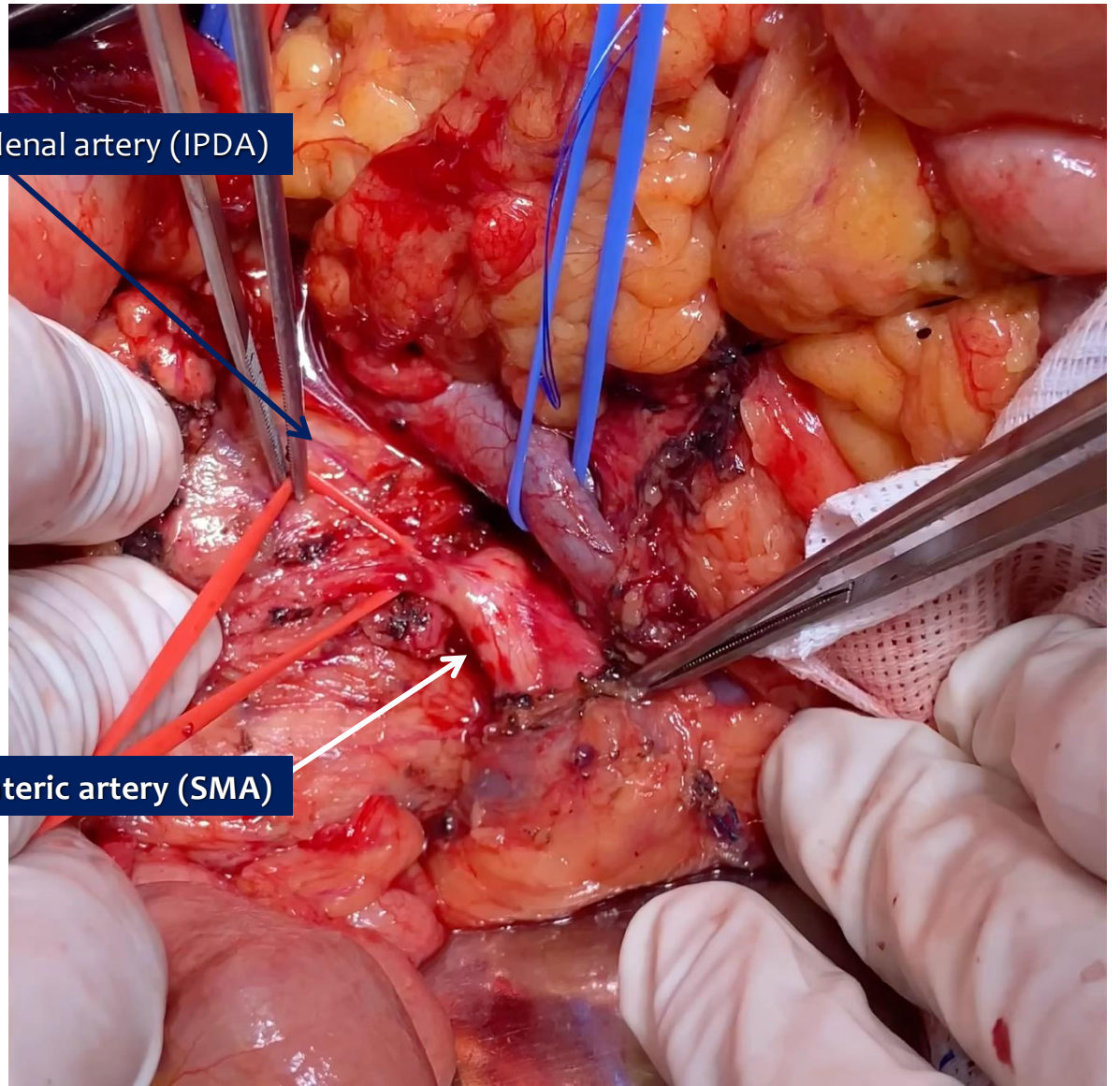
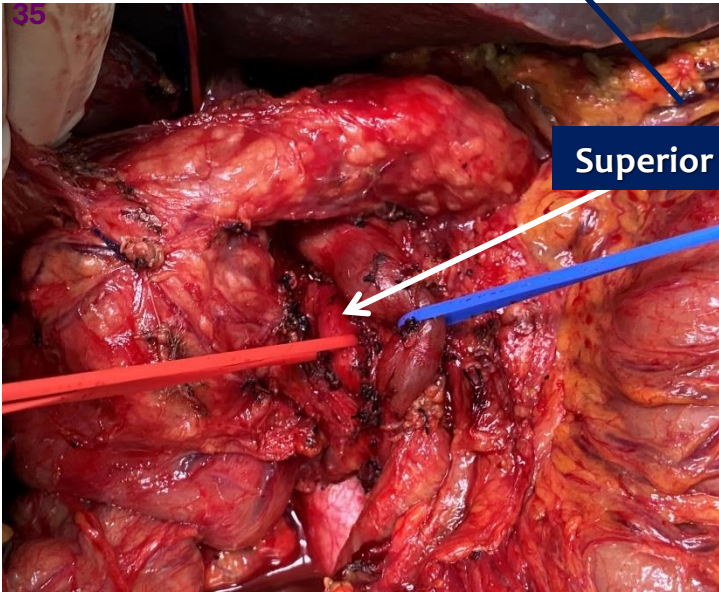


# ARTERY FIRST



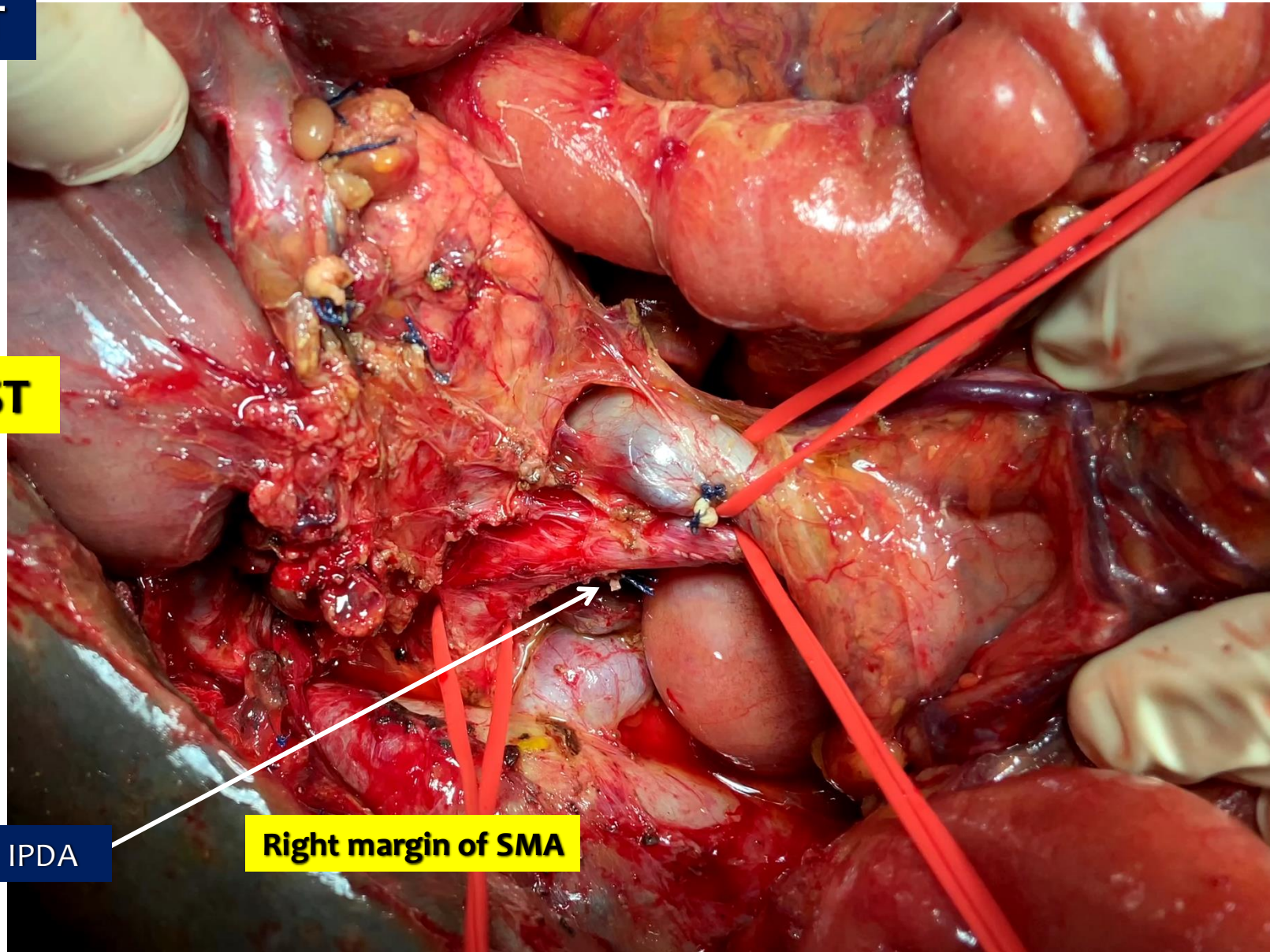
# UNCINATE FIRST

Pandanaboyana S, et al. Br J Surg 2012;99:1027-35



**ARTERY FIRST**

**UNCINATE FIRST**

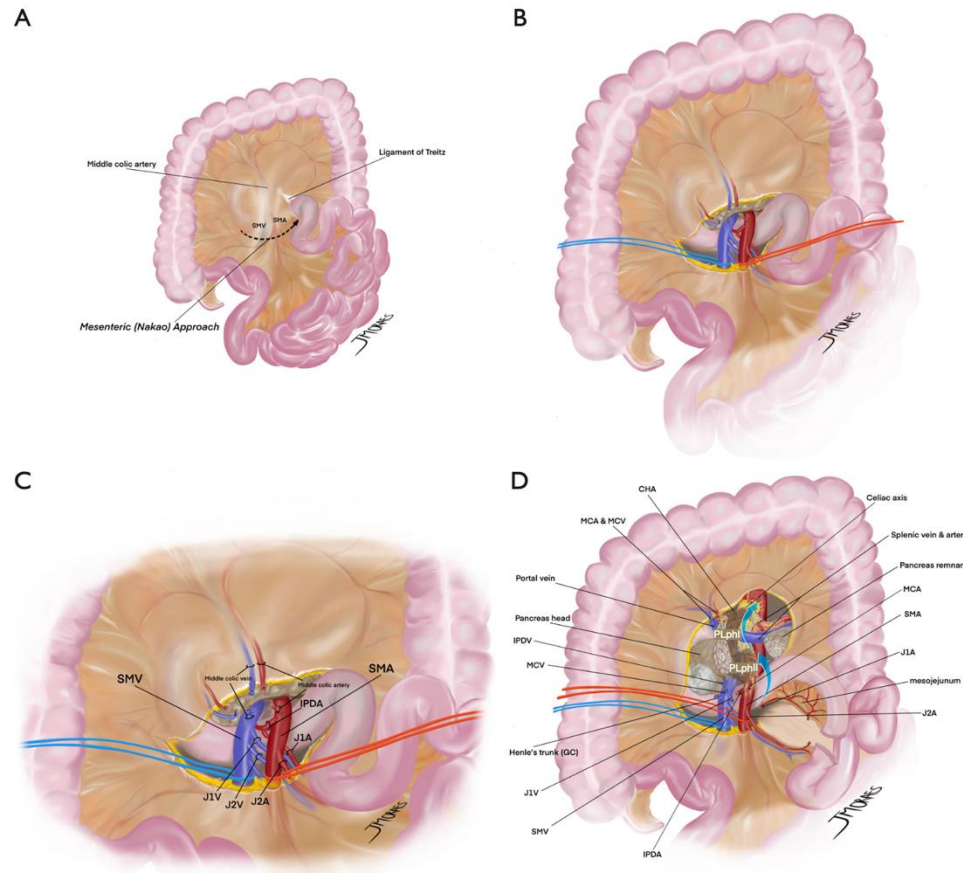


**IPDA**

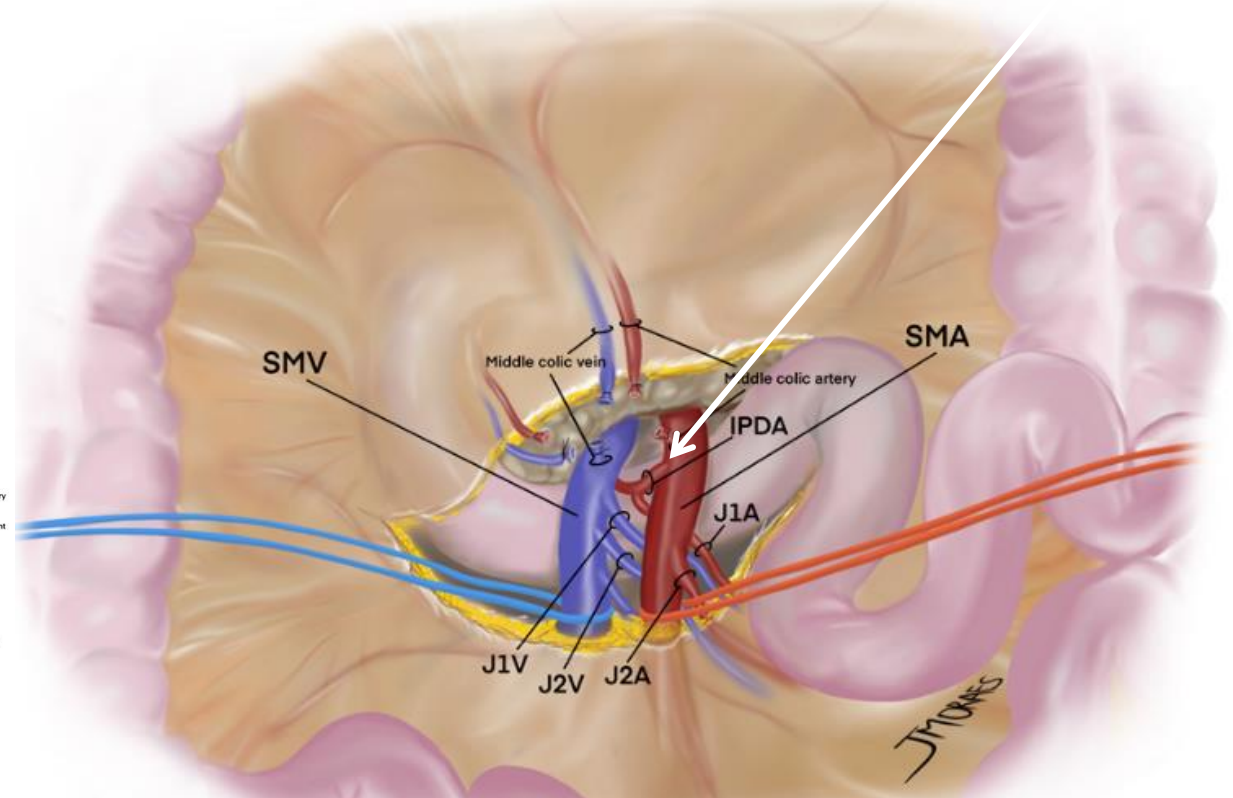
**Right margin of SMA**

## A more radical perspective on surgical approach and outcomes in pancreatic cancer – a narrative review

Eduardo de Souza M. Fernandes<sup>1,2,3</sup>, Felipe Pedreira T. de Mello<sup>1,2</sup>, Eduardo Pinho Braga<sup>1</sup>, Gabrielle Oliveira de Souza<sup>1</sup>, Ronaldo Andrade<sup>1,2</sup>, Leandro Savatone Pimentel<sup>1,2</sup>, Camila Liberato Girão<sup>1,2</sup>, Munique Siqueira<sup>1,2</sup>, José Maria A. Moraes-Junior<sup>6,7</sup>, Romulo Varella de Oliveira<sup>4</sup>, Nicolas Goldaracena<sup>5</sup>, Orlando Jorge M. Torres<sup>6,7</sup>

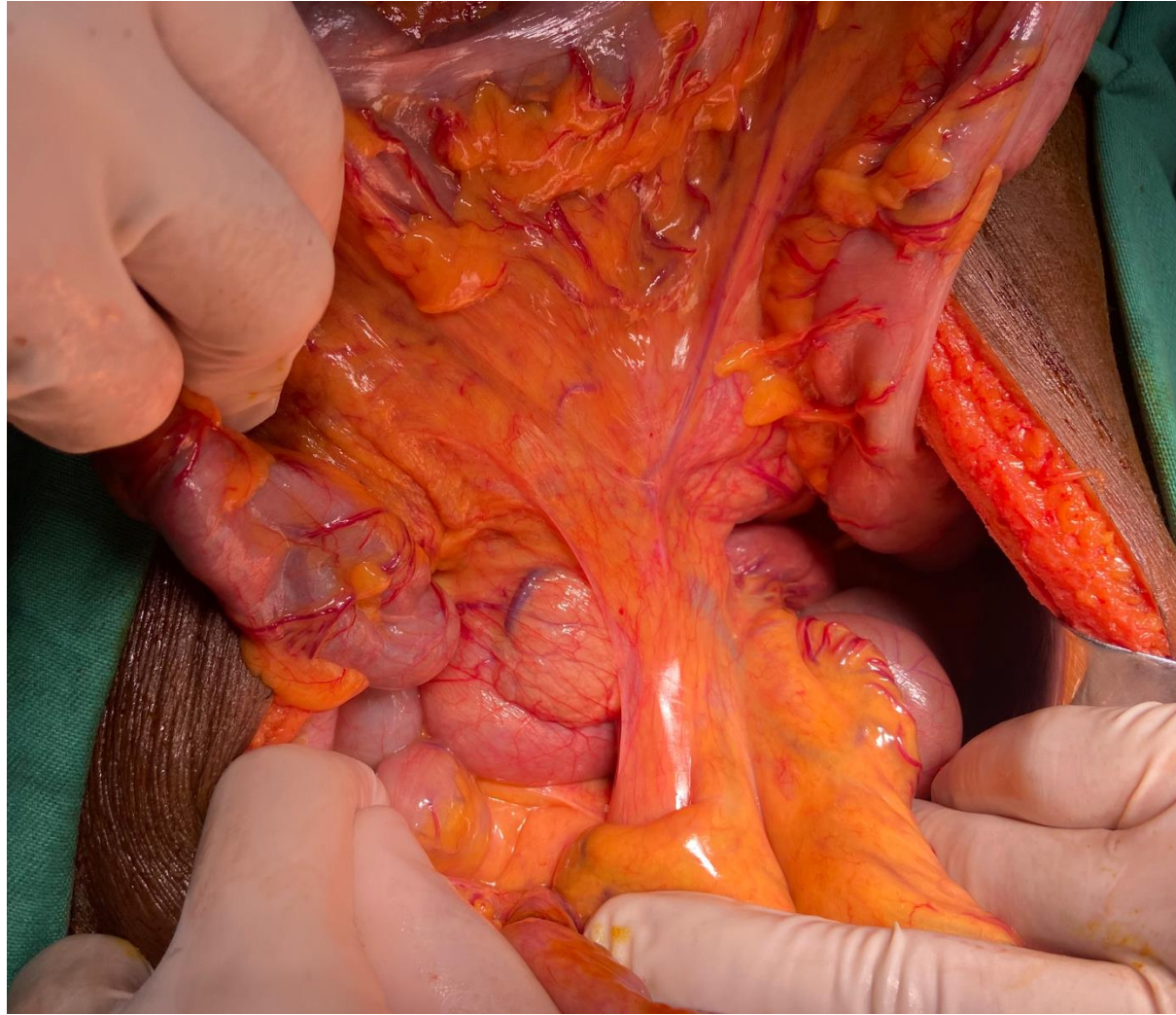


Inferior pancreatoduodenal artery (IPDA)



**MESENTERIC APPROACH**

# ARTERY FIRST

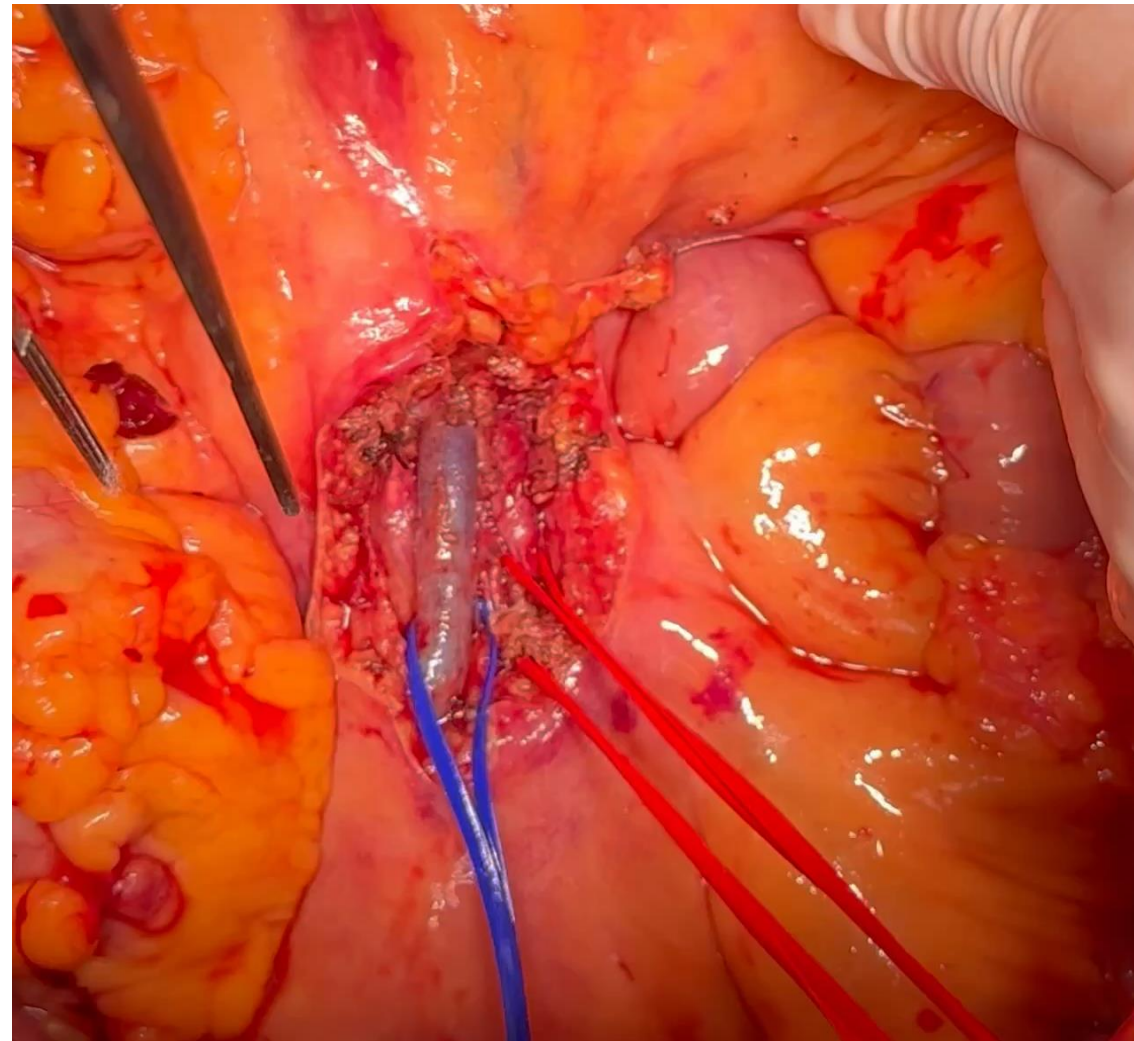
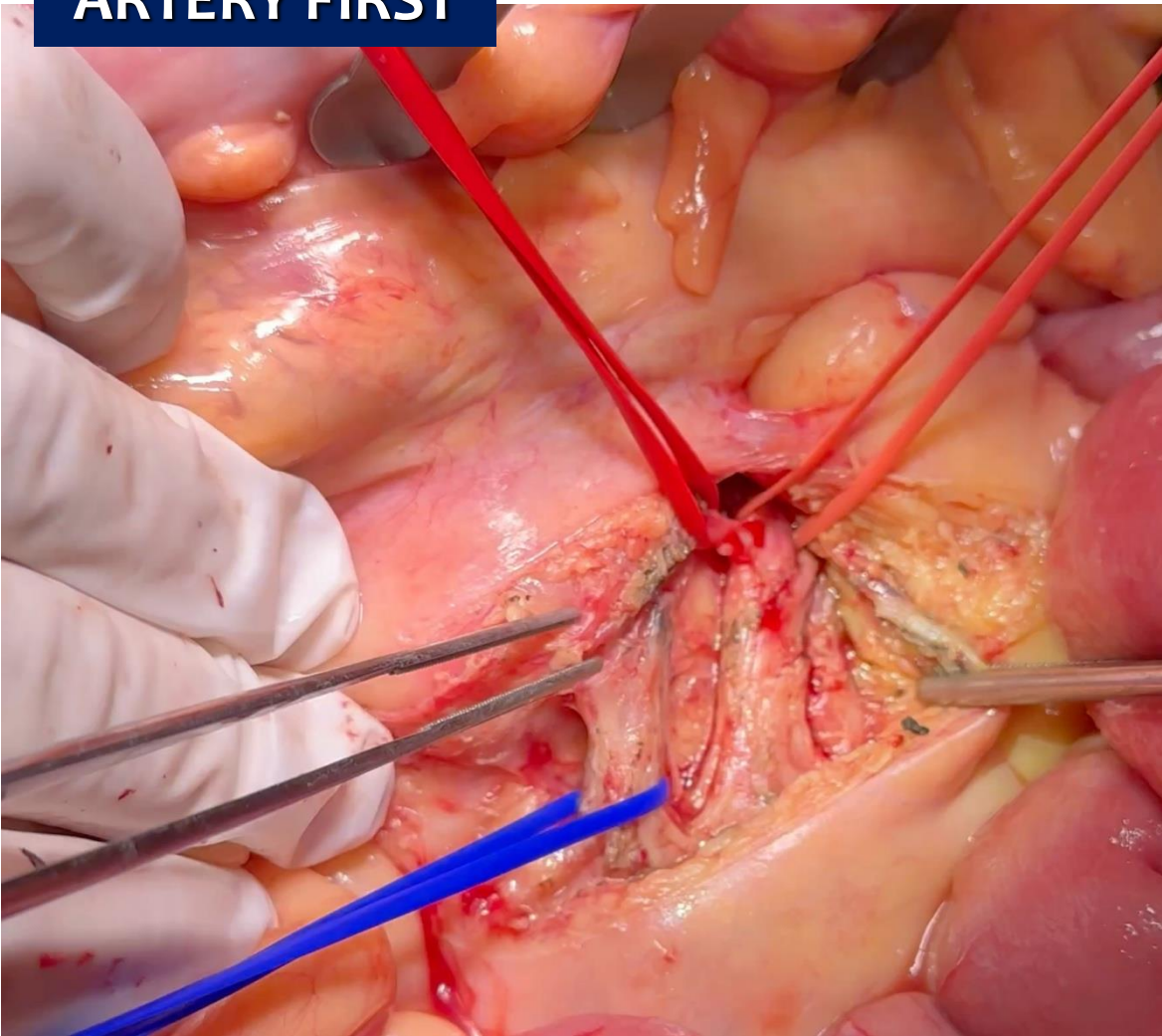


Infracolic approach

**MESENTERIC APPROACH**

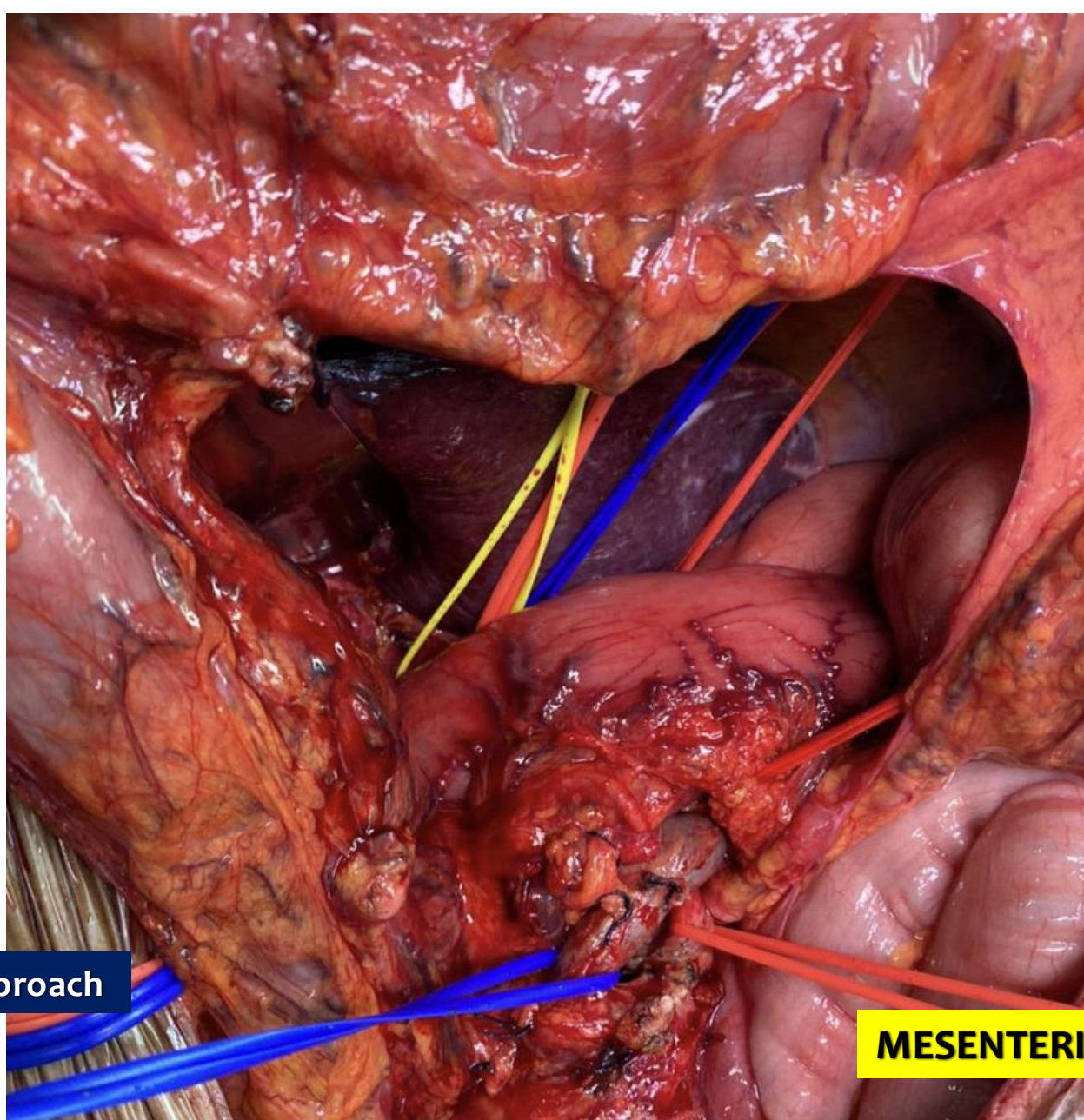
**ARTERY FIRST**

**INFRACOLIC APPROACH**



**MESENTERIC APPROACH**

# ARTERY FIRST



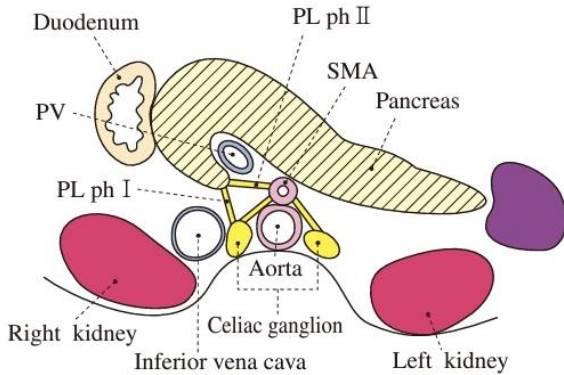
Infracolic approach

MESENTERIC APPROACH

# Classification of Pancreatic Carcinoma

Japan Pancreas Society  
Fourth English Edition

Kanehara & Co., Ltd.



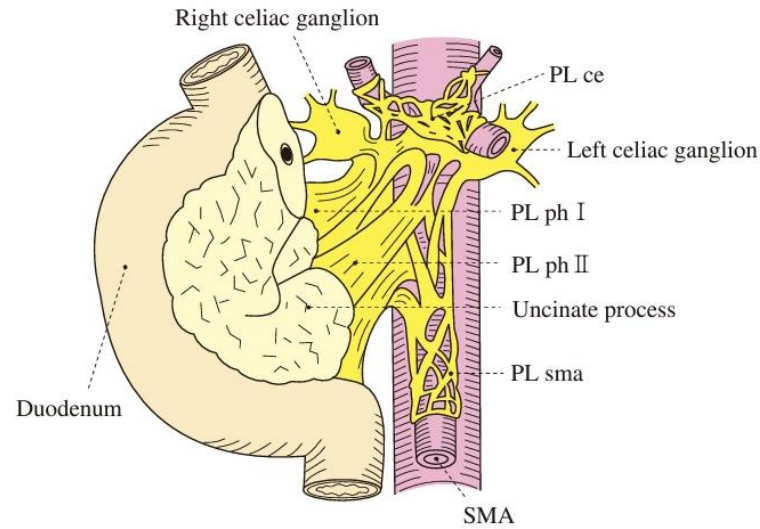
**Fig. 3a** Pancreatic nerve plexuses  
(cross-sectional diagram)

PLph I: pancreatic head nerve plexus I

PLsma: superior mesenteric nerve plexus

PLhdl: hepatoduodenal ligament nerve plexus

PLce: celiac plexus

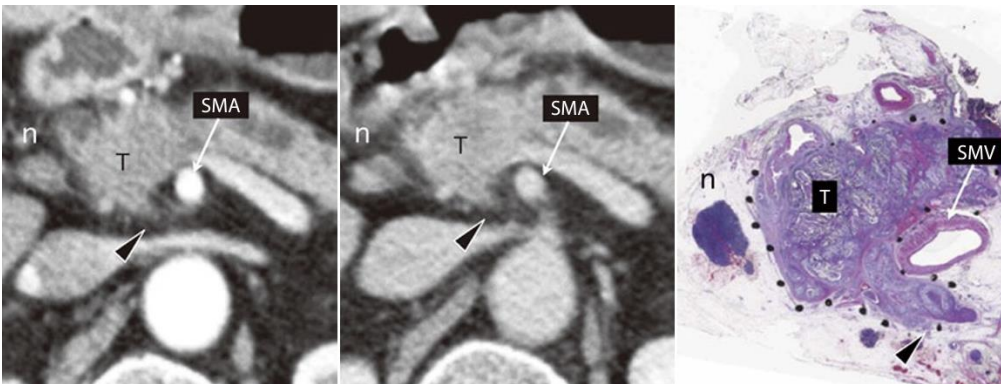


**Fig. 3b** Extrapancreatic nerve plexuses

PLph II: pancreatic head nerve plexus II


PLcha: common hepatic artery nerve plexus

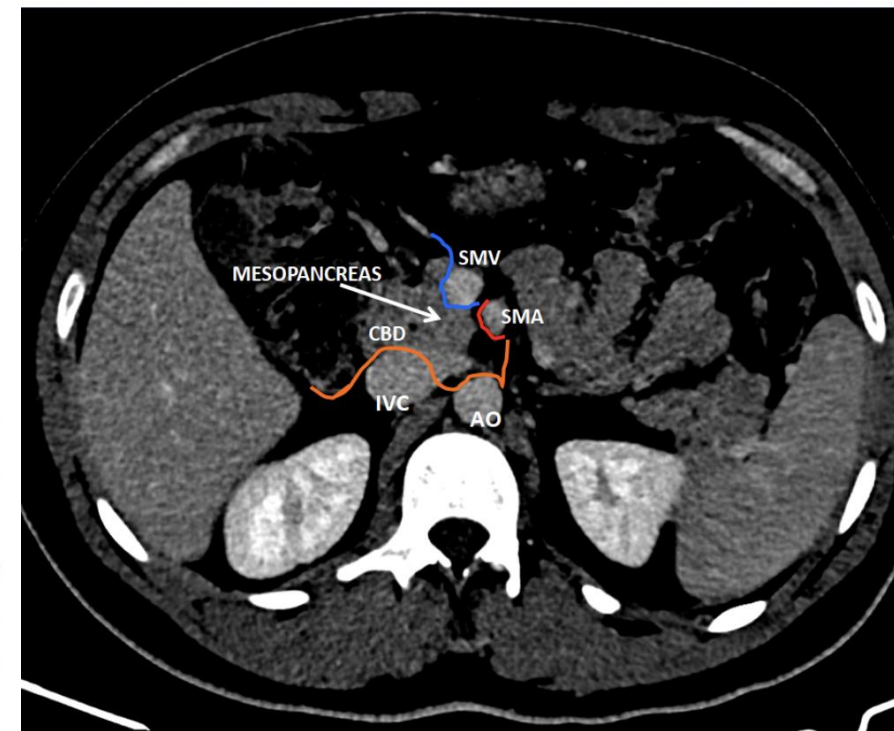
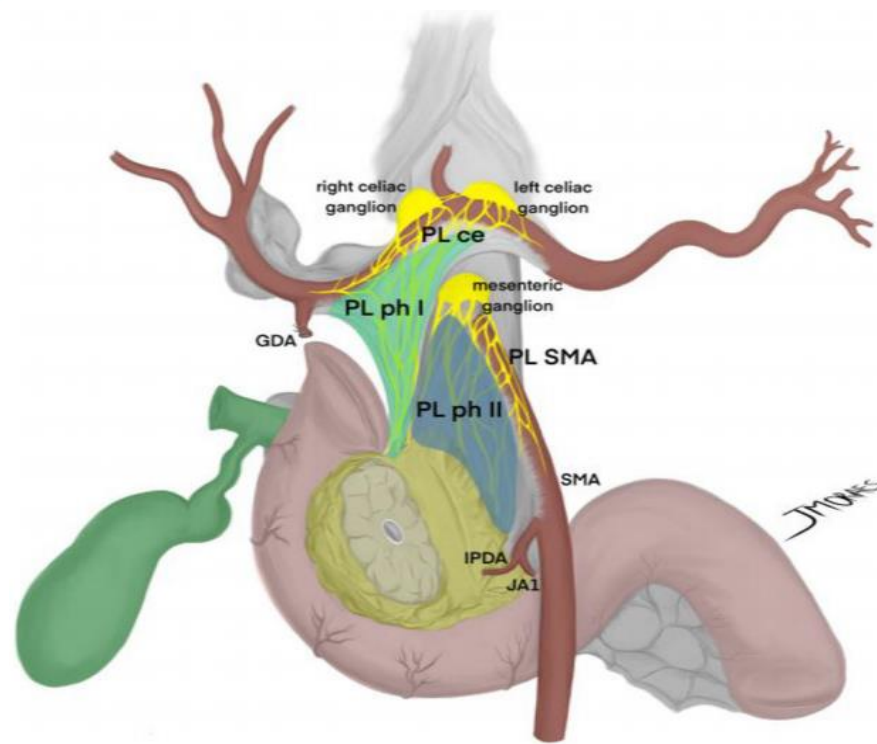
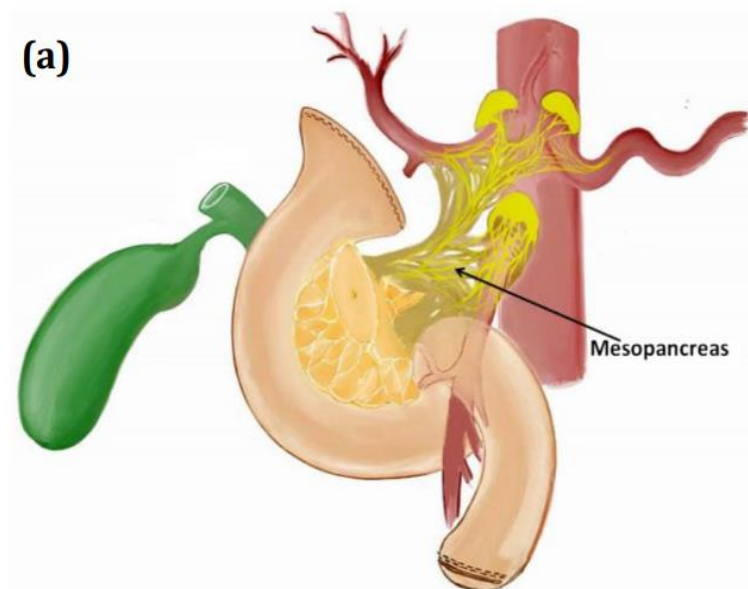
PLspa: splenic artery nerve plexus





## What do surgeons need to know about the mesopancreas

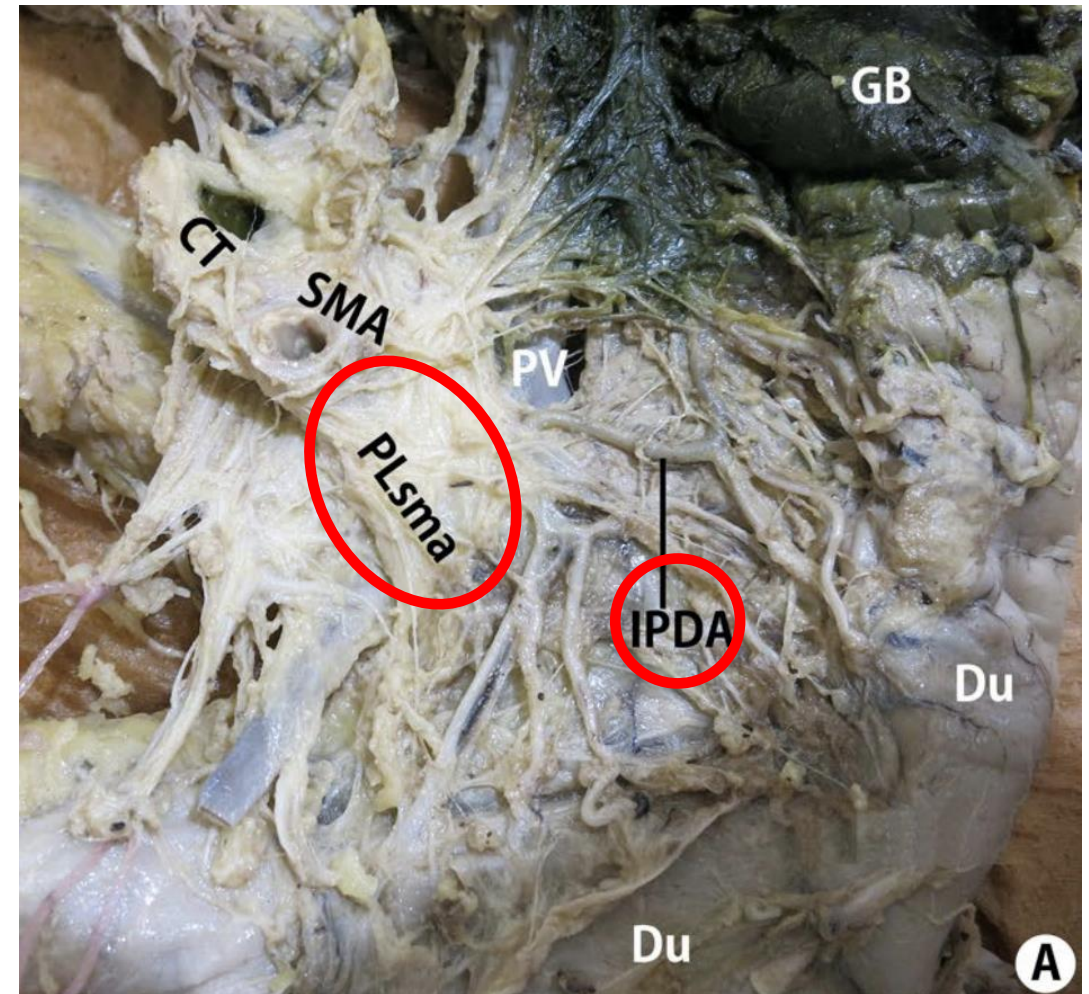
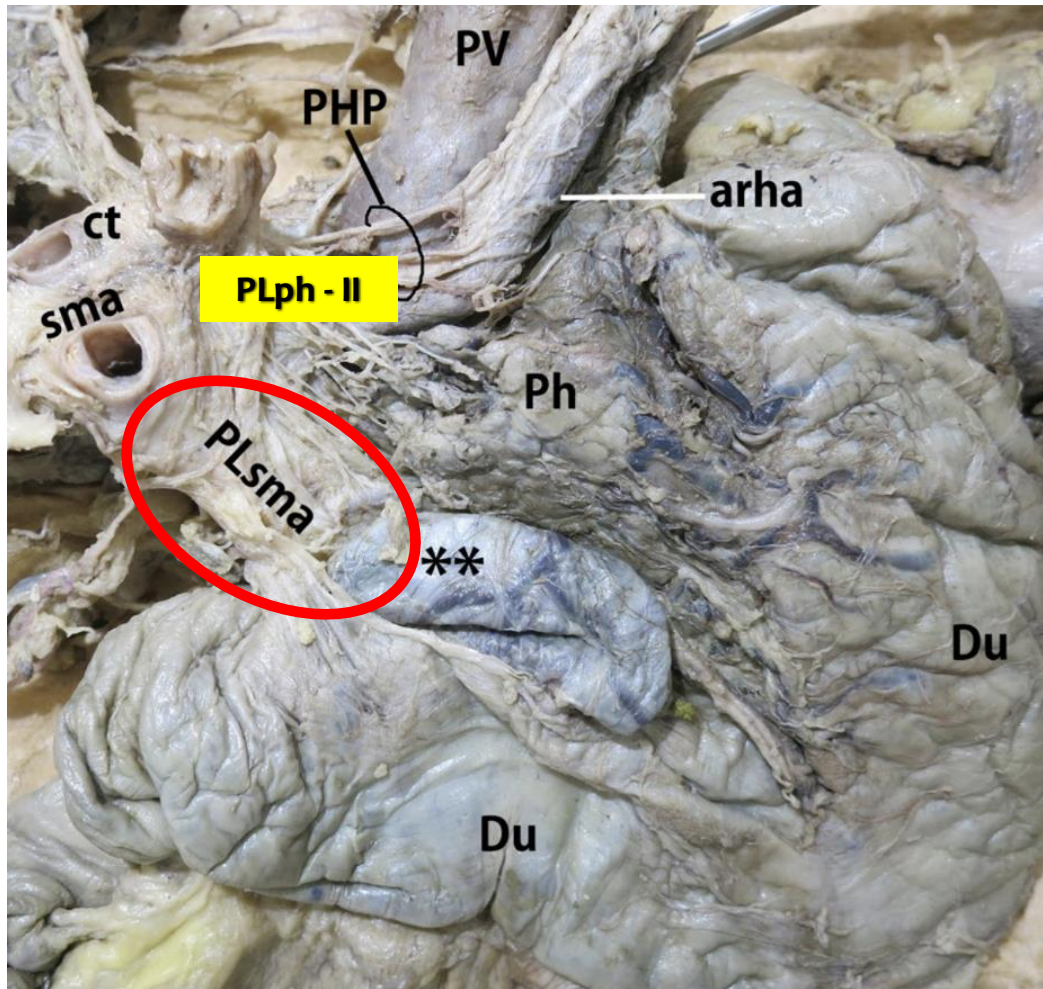
Eduardo de Souza M. Fernandes<sup>1,2</sup> · Oliver Strobel<sup>3,4</sup> · Camila Girão<sup>1,2</sup> · Jose Maria A. Moraes-Junior<sup>5,6</sup> · Orlando Jorge M. Torres<sup>5,6</sup> 



**PANCREATIC HEAD PLEXUS (pIPH)**



# The mesopancreas and **pancreatic head plexus** morphological, developmental, and clinical perspectives



**Table 3** Advantages of the artery-first approach (SHARMA) [35]

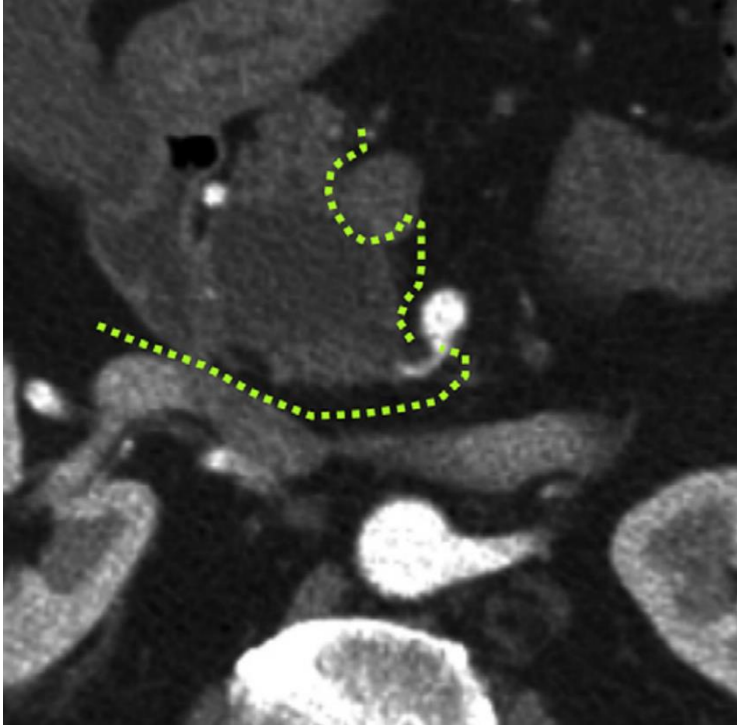
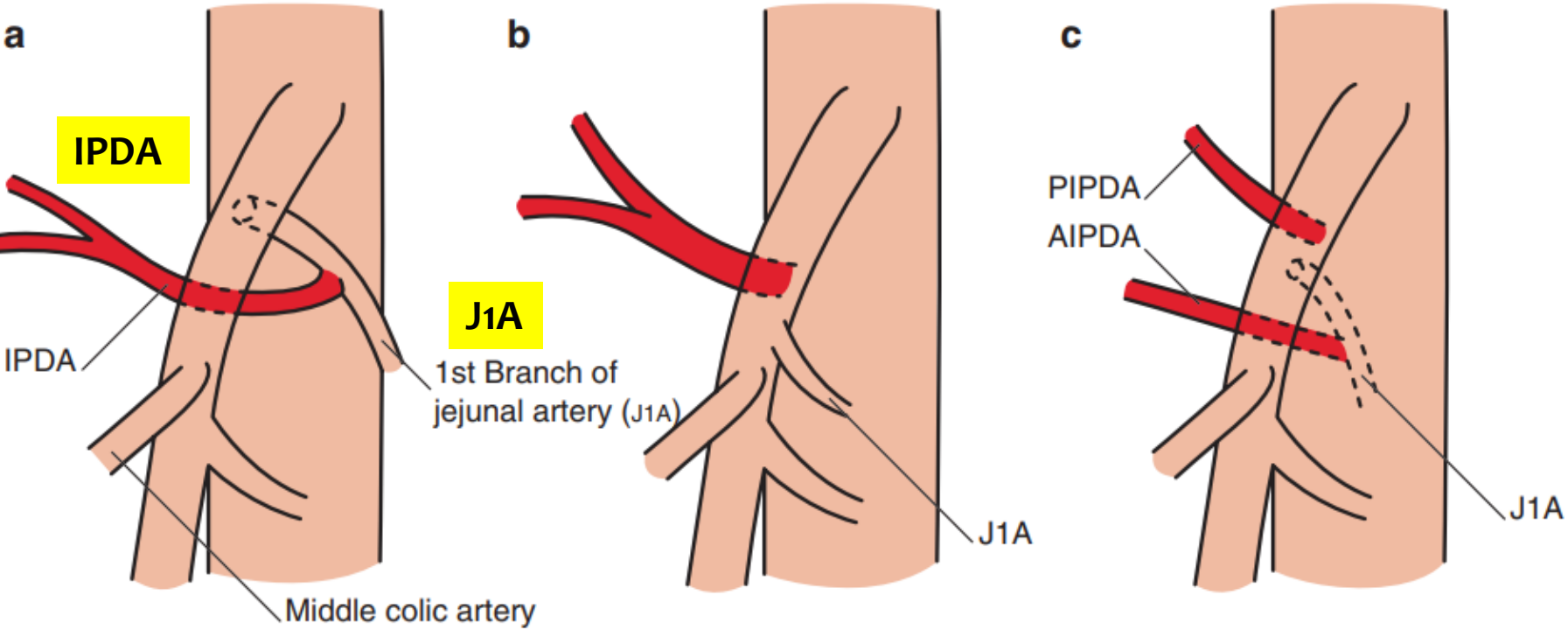
- 
1. Resection without breaching the tumor extension plane, thereby minimizing cell spillage
  2. Increases curative (R0) resection, decreases local recurrence
  3. Complete resection of peripancreatic retroperitoneal tissue around the plexuses
  4. Increased lymph nodal clearance
  5. Early assessment of non-resectability (SMA involvement), avoiding useless R2 resections
  6. Better delineation of SMA and identification of RHA anomalies
  7. Easier en bloc resection and reconstruction of SMV-PV by “no touch” technique
  8. Reduced need for graft substitutions
  9. Reduced operative time and blood loss (early ligation of IPDA/JA1)
- 

**PANCREATIC HEAD PLEXUS (PL ph)**

**ARTERY FIRST**

# ARTERIES

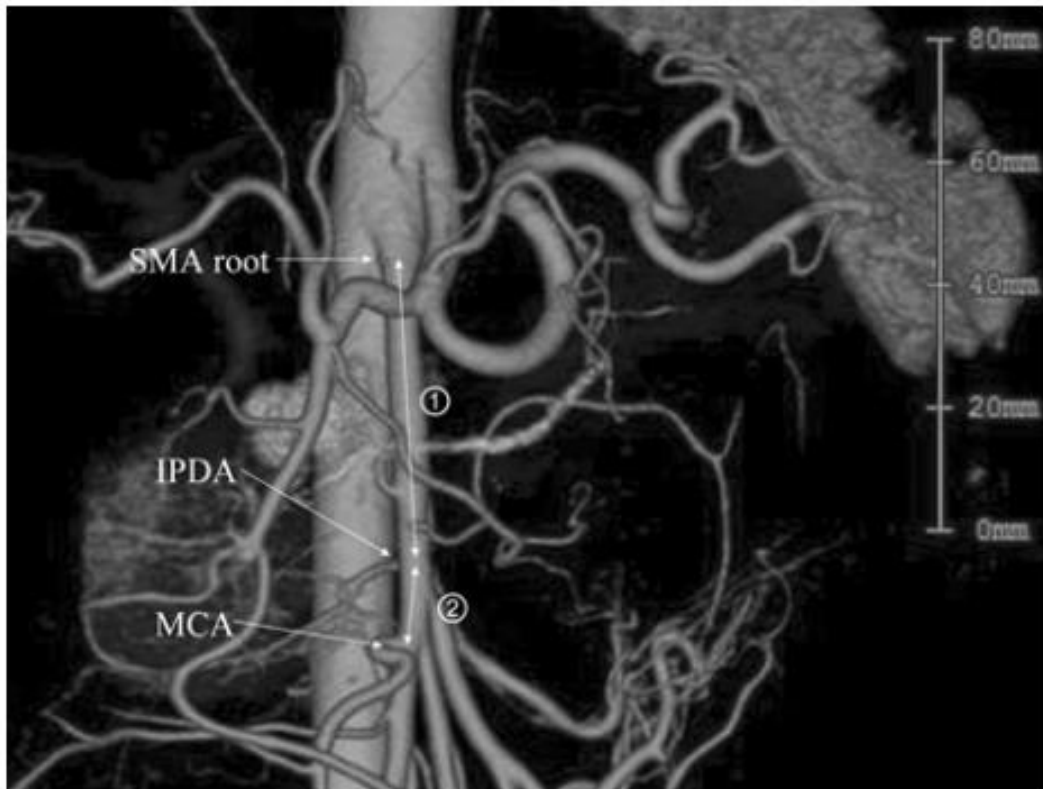
# INFERIOR PANCREATODUODENAL ARTERY (IPDA)



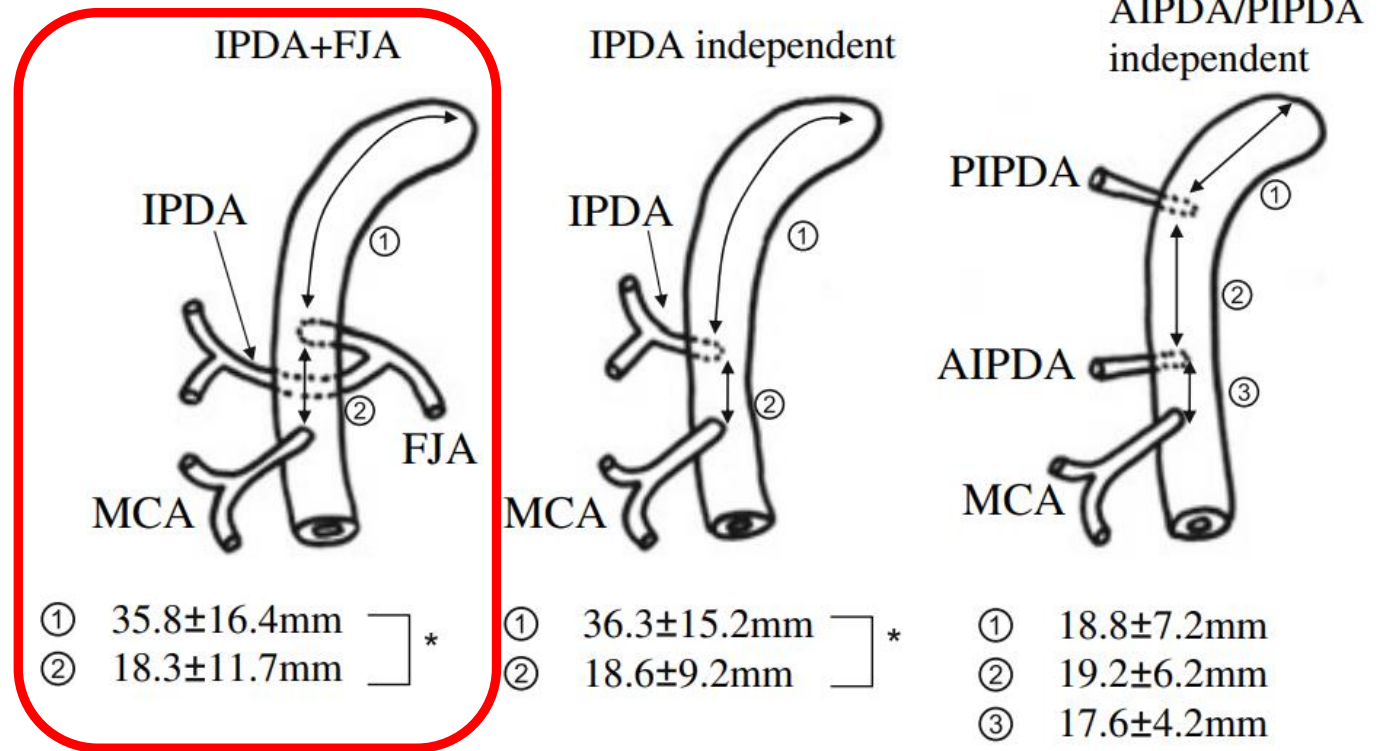
# Common trunk

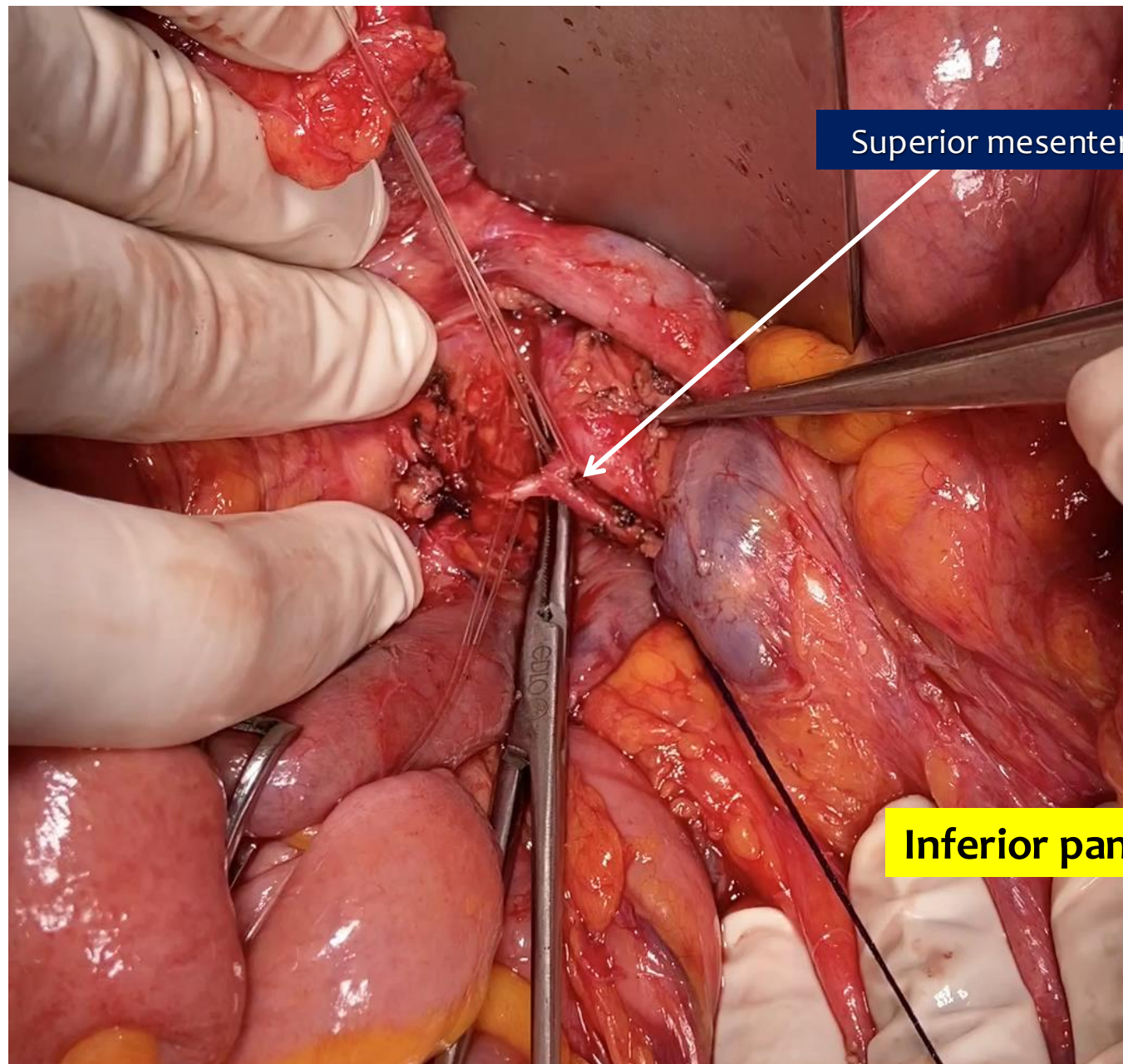
# EPICENTRO DA DUODENOPANCREATECTOMIA

**Three-dimensional models of arteries constructed using multidetector-row CT images to perform pancreatoduodenectomy safely following dissection of the inferior pancreaticoduodenal artery**



**INFERIOR PANCREATODUODENAL ARTERY (IPDA)**





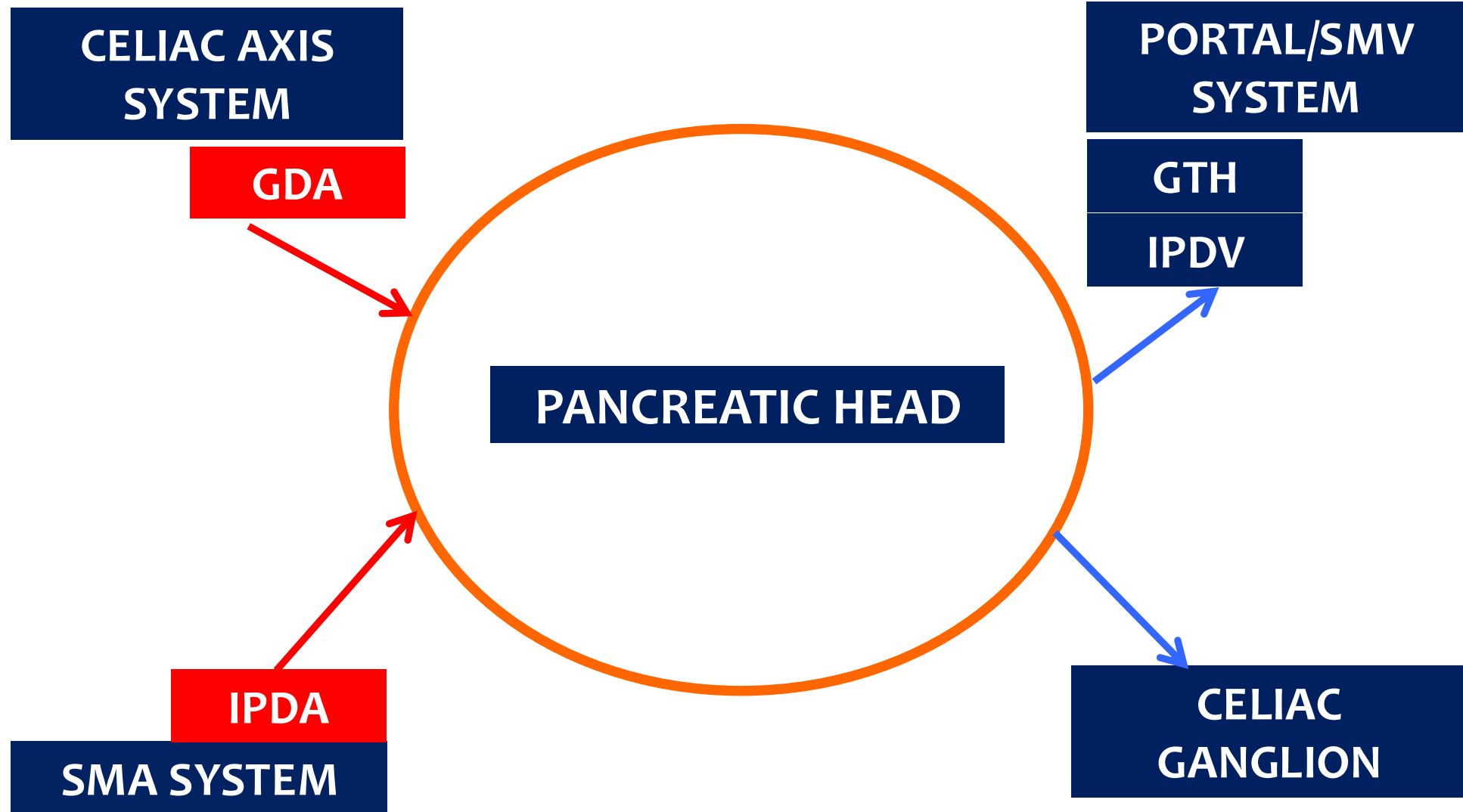
Superior mesenteric artery

**IPDA**

**J1A**

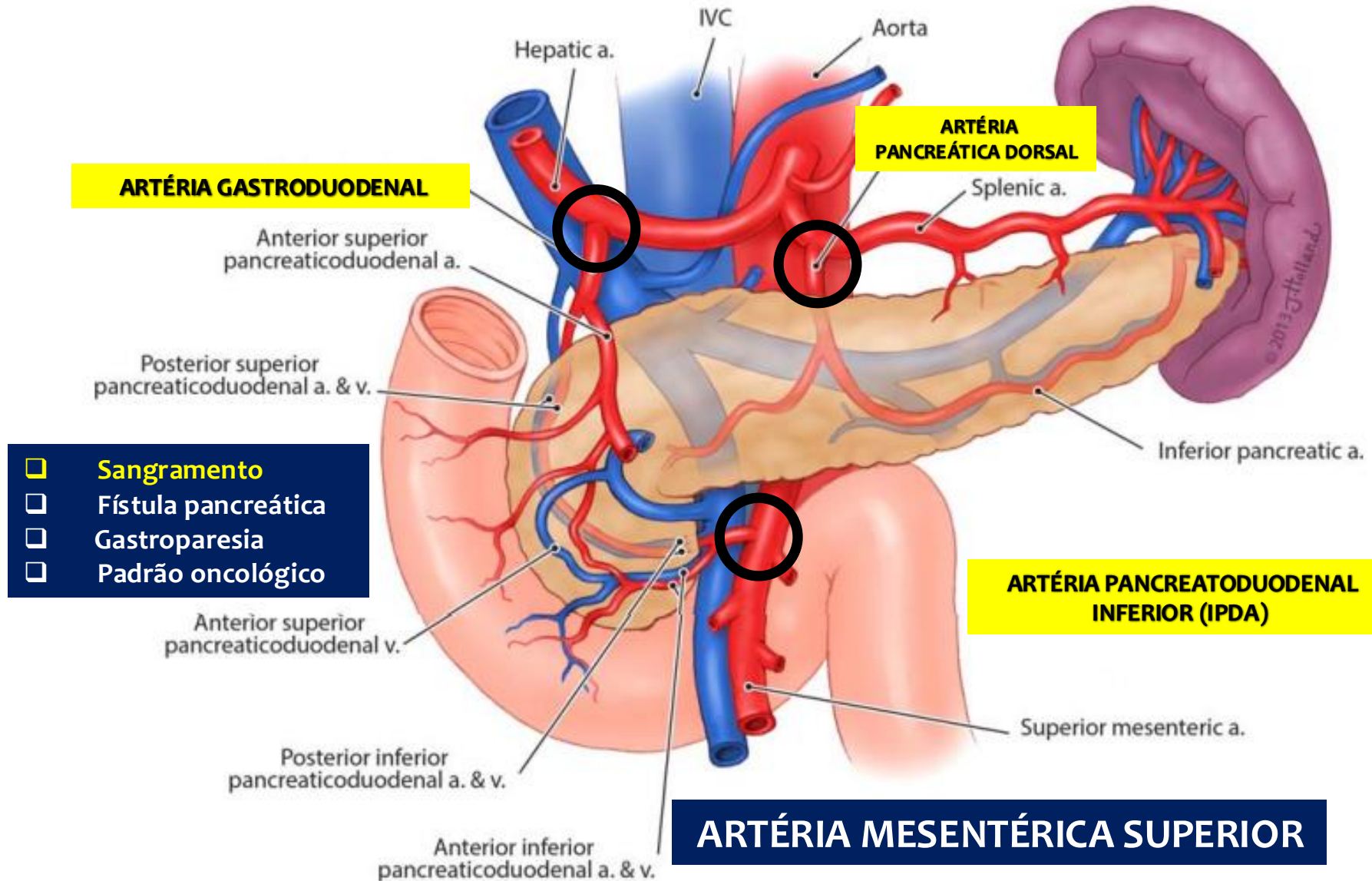
Inferior pancreaticoduodenal artery

# CENTRAL VASCULAR LIGATION



# ARTERIES

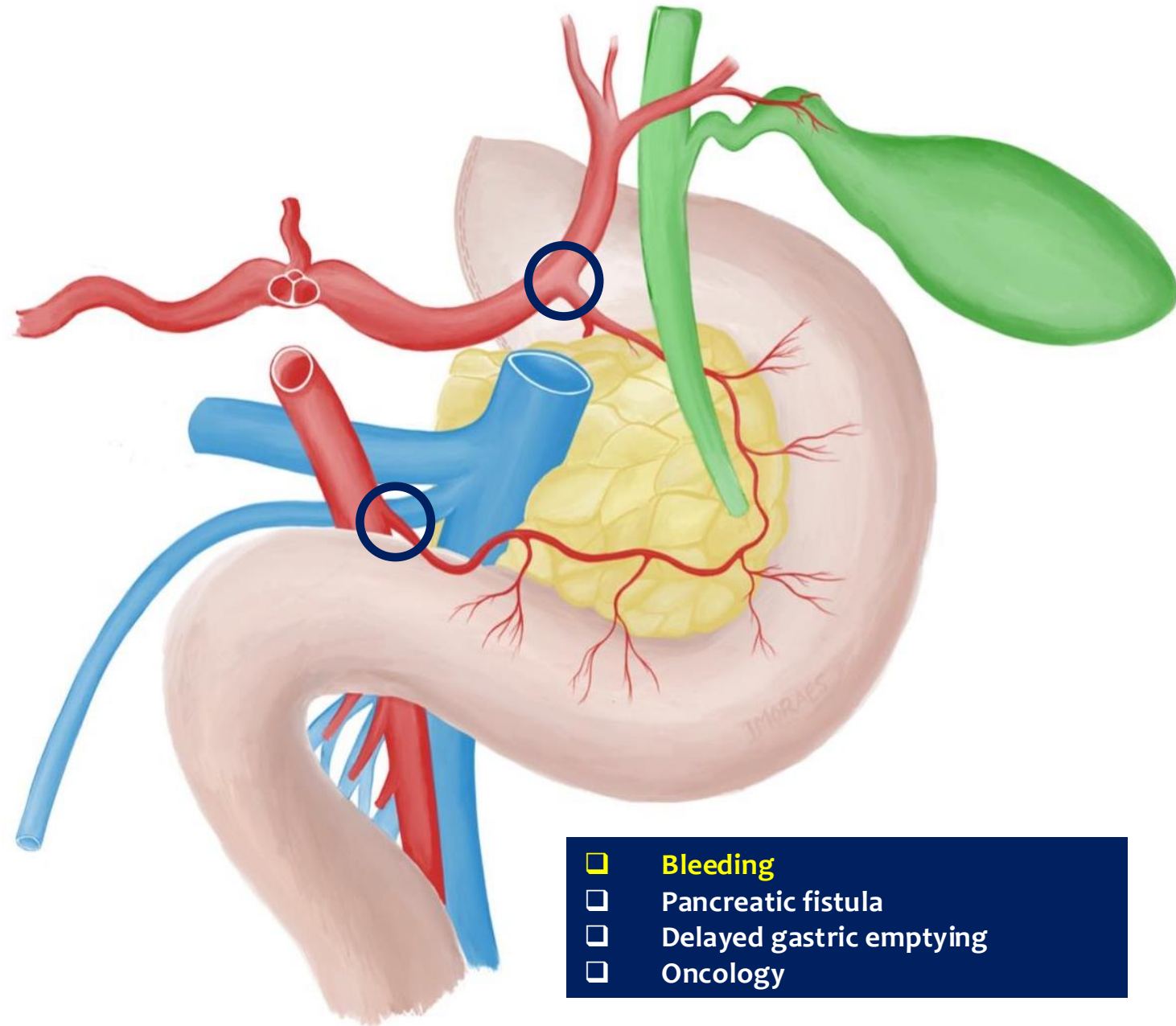
# TRONCO CELÍACO



# ARTERY FIRST APPROACH

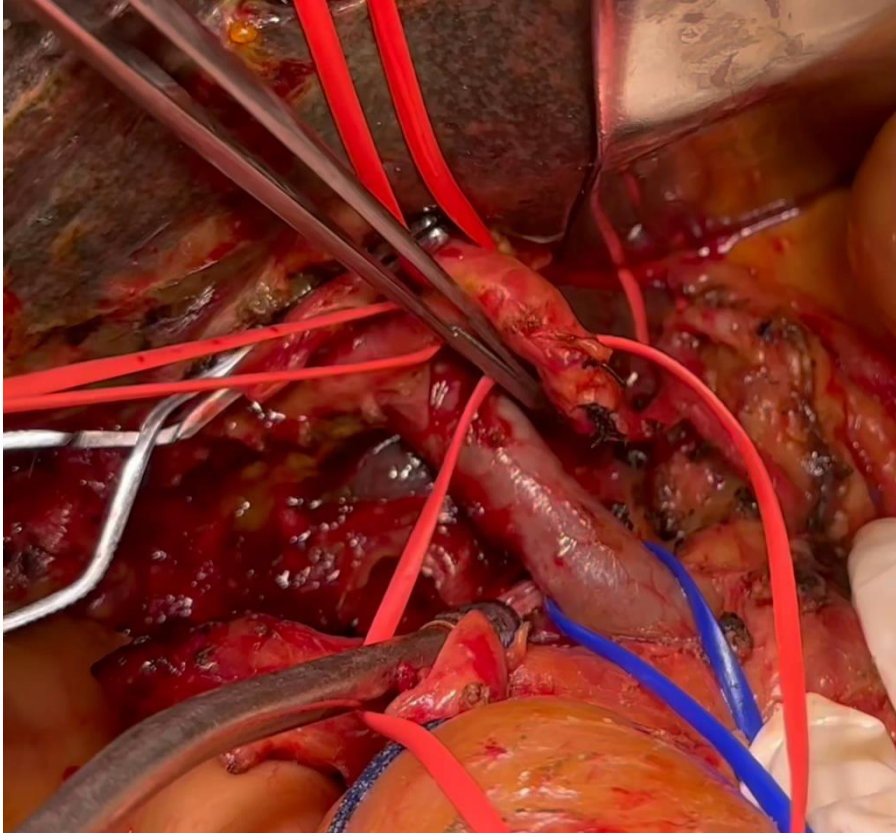
**Table 3** Advantages of the artery-first approach (SHARMA) [35]

1. Resection without breaching the tumor extension plane, thereby minimizing cell spillage
2. Increases curative (R0) resection, decreases local recurrence
3. Complete resection of peripancreatic retroperitoneal tissue around the plexuses
4. Increased lymph nodal clearance
5. Early assessment of non-resectability (SMA involvement), avoiding useless R2 resections
6. Better delineation of SMA and identification of RHA anomalies
7. Easier en bloc resection and reconstruction of SMV-PV by “no touch” technique
8. Reduced need for graft substitutions
9. Reduced operative time and blood loss (early ligation of IPDA/JA1)

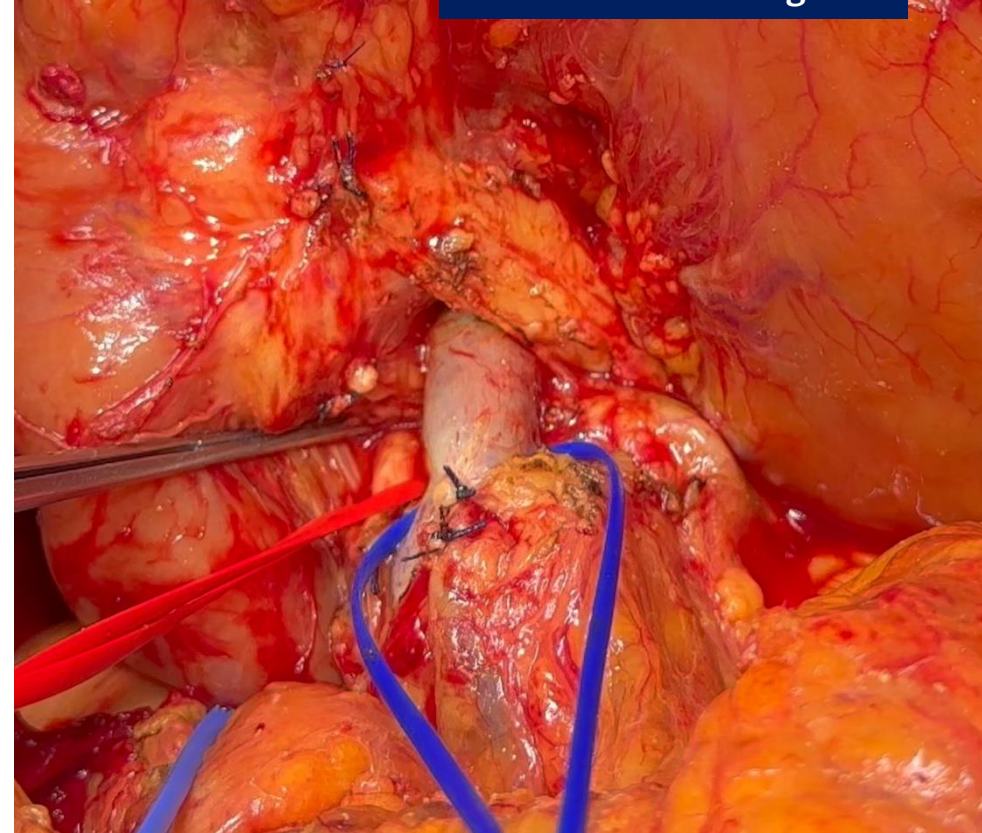


## CONTROLE VENOSO

- Sangramento
- Fístula pancreática
- Gastroparesia
- Padrão oncológico



PORTAL VEIN CONTROL

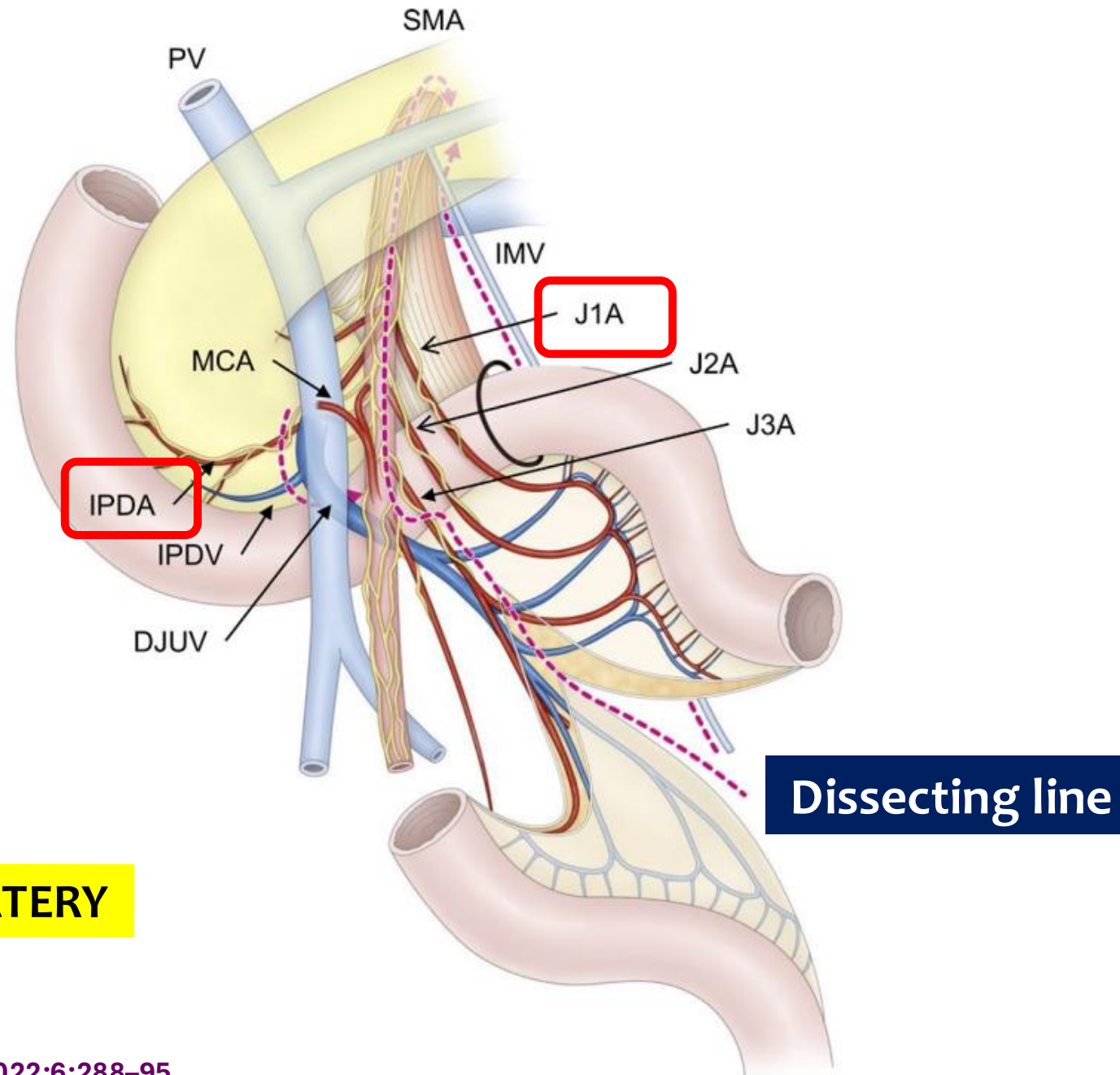


SUPERIOR MESENTERIC VEIN CONTROL

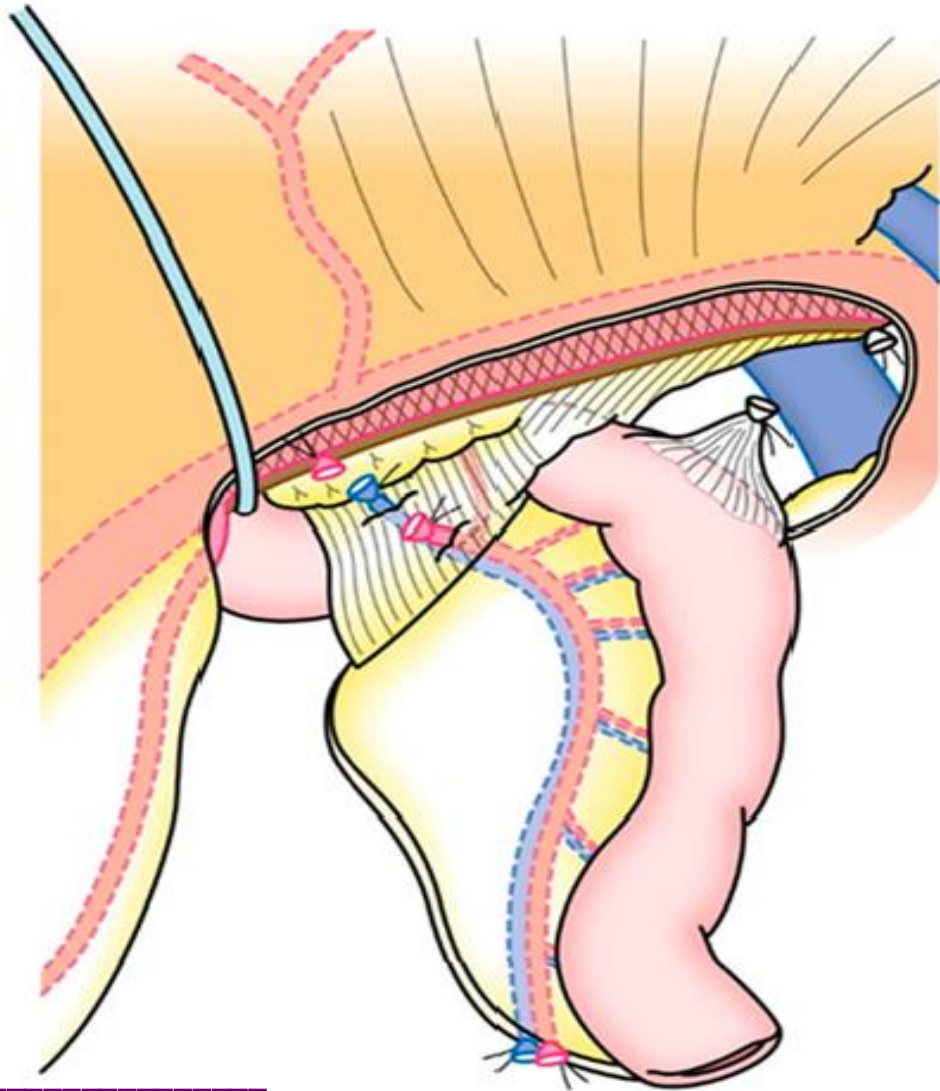
# MESOPANCREAS

## IPDA

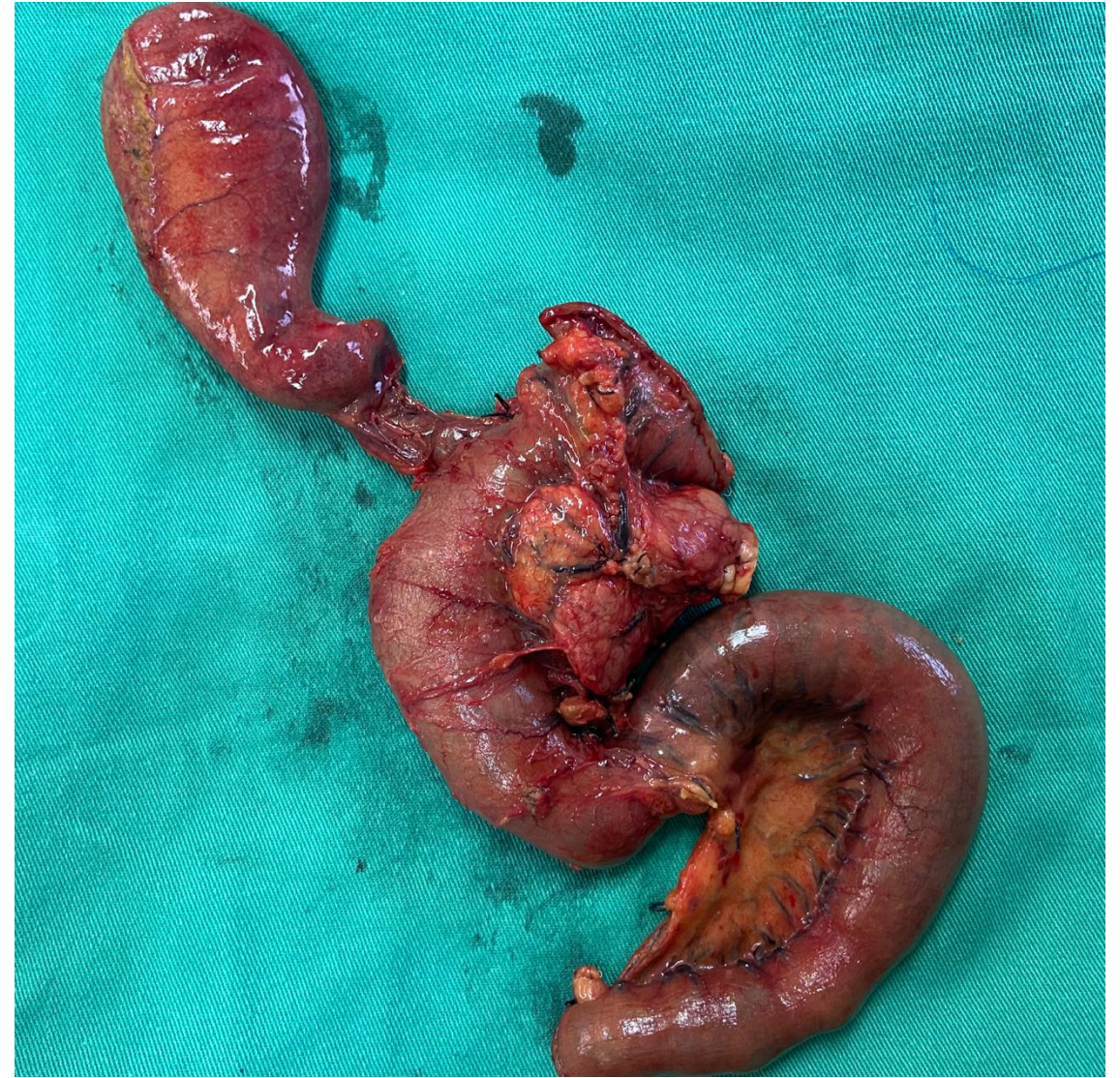## FIRST JEJUNAL ARTERY



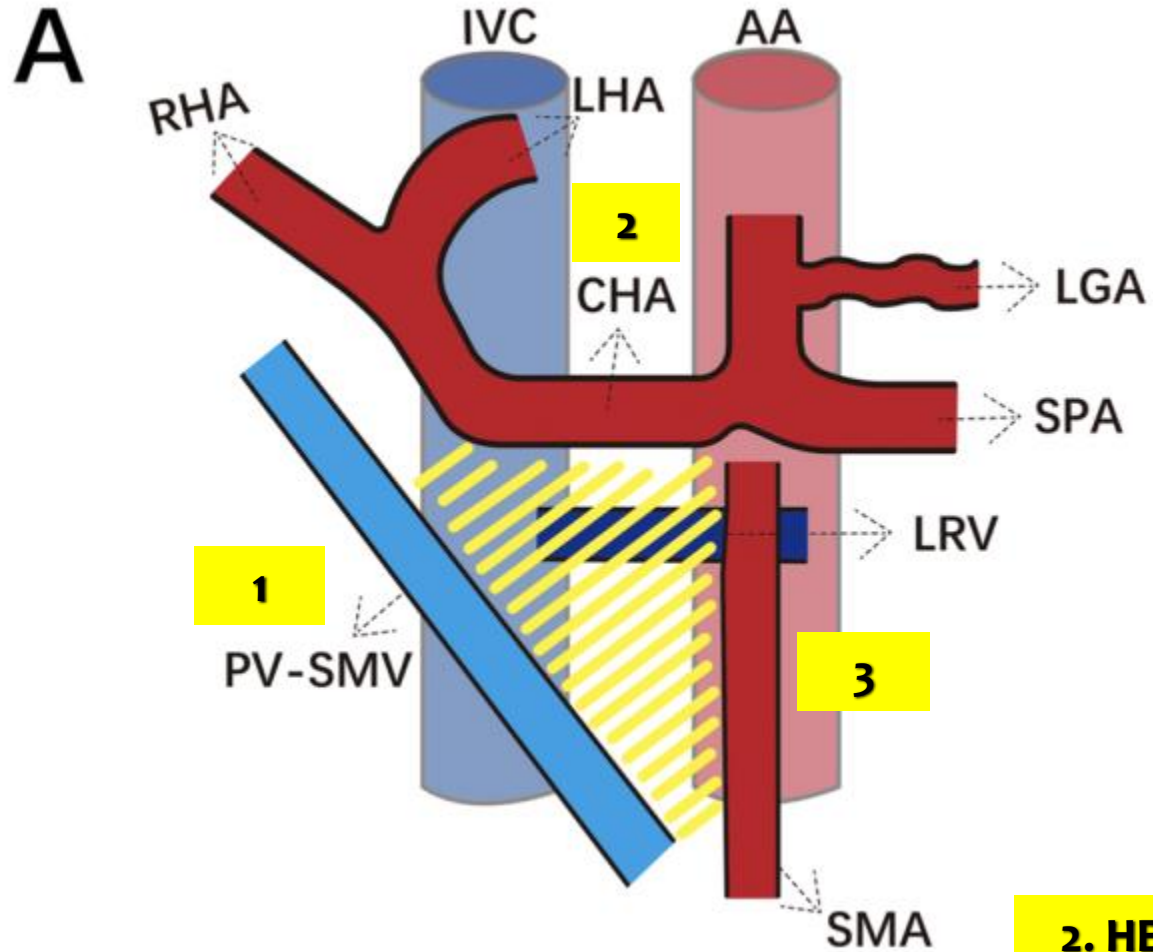
# FIRST JEJUNAL ARTERY



Inoue Y, et al. J Gastrointest Surg 2016



# TRIANGLE OPERATION

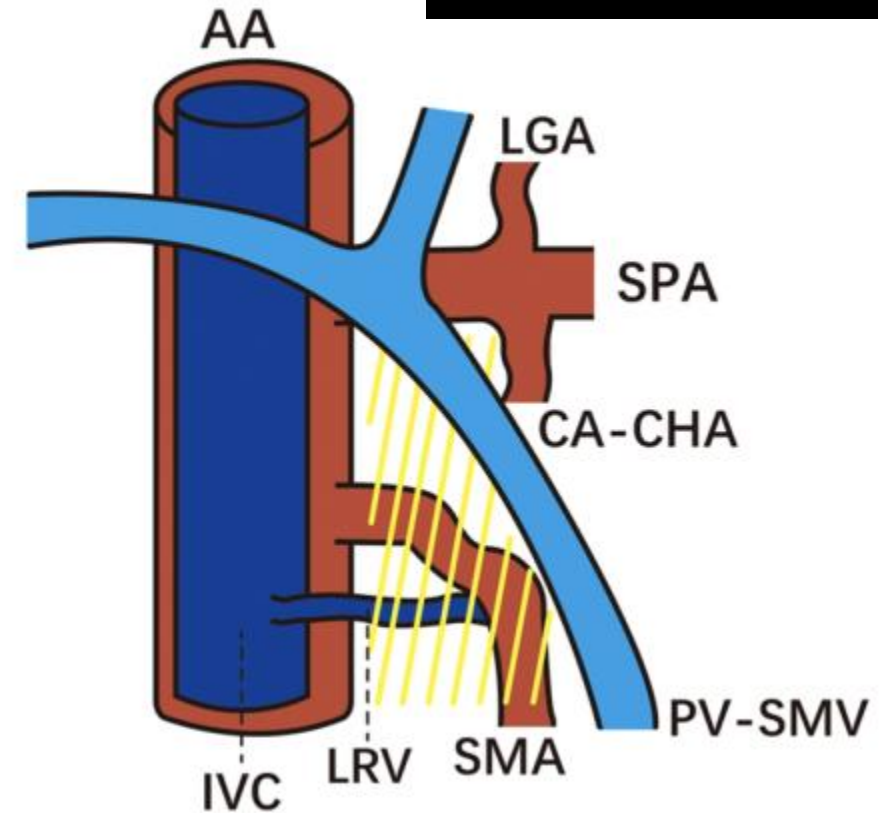


**2. HEMICIRCUMFERENTIAL DISSECTION OF CHA**

**1. CIRCUMFERENTIAL DISSECTION OF SMV/PV**

**B**

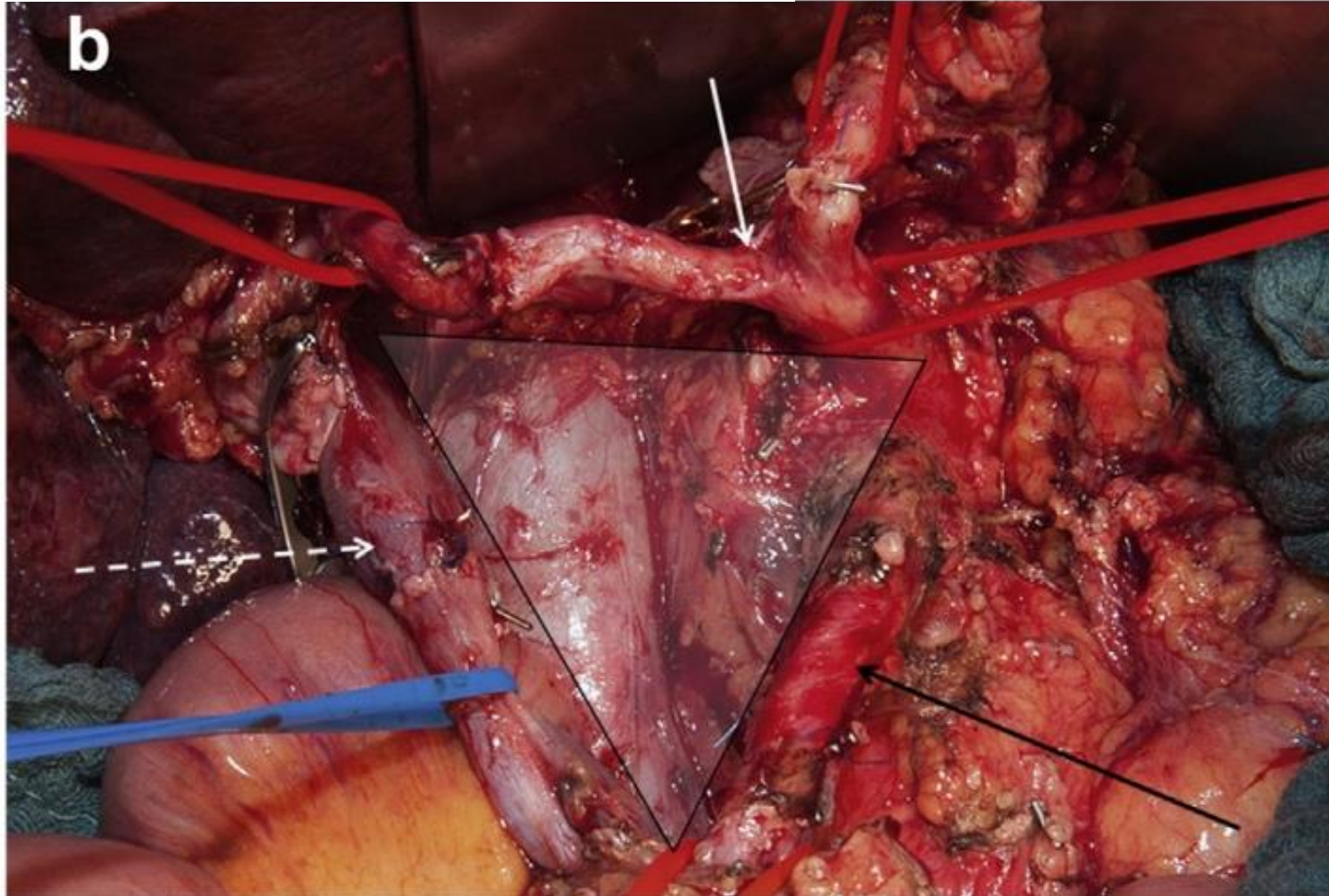
**RATIONAL**



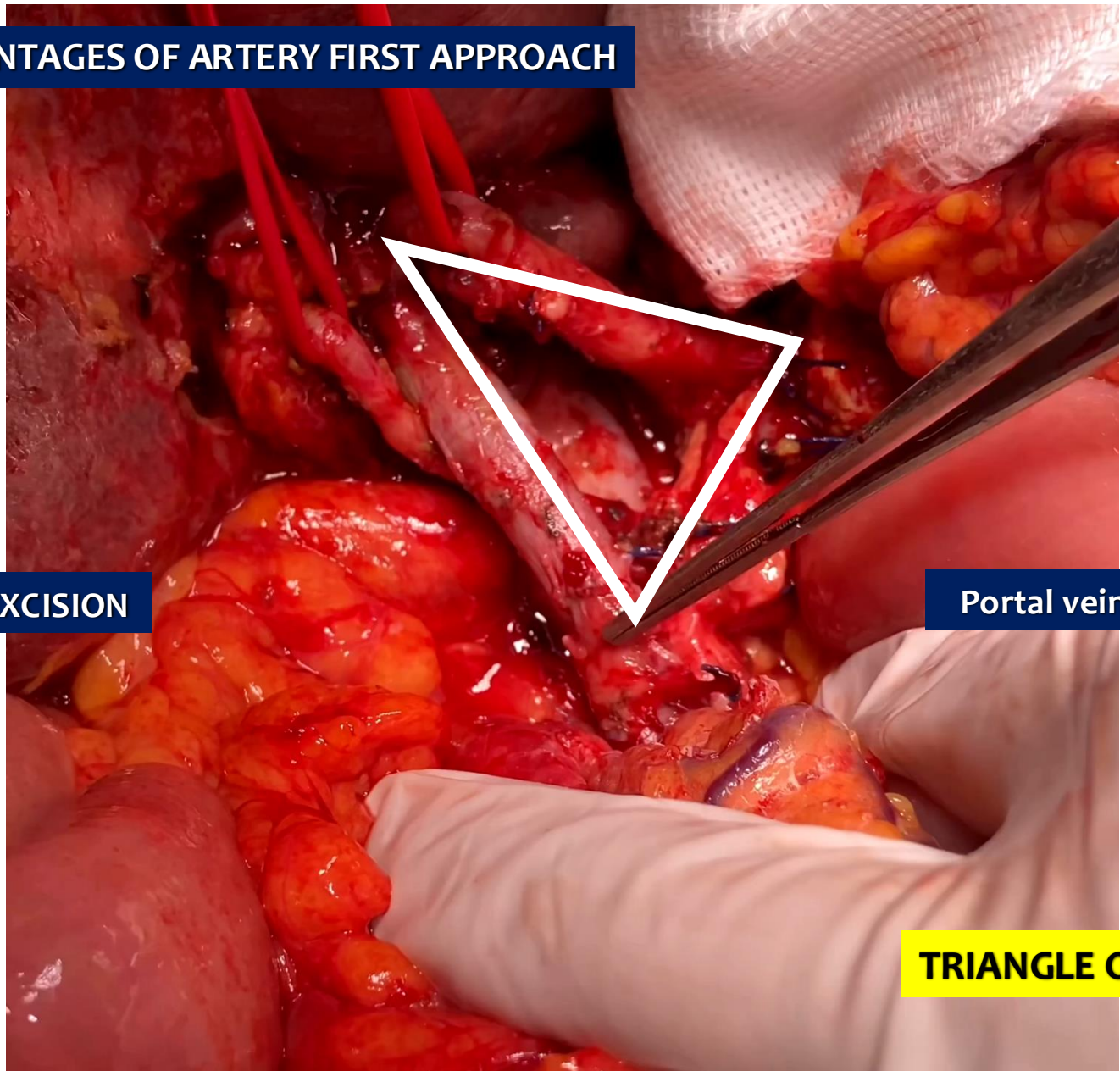
**3. HEMICIRCUMFERENTIAL DISSECTION OF SMA**

ORIGINAL ARTICLE

**The TRIANGLE operation – radical surgery after neoadjuvant treatment for advanced pancreatic cancer: a single arm observational study**



**ADVANTAGES OF ARTERY FIRST APPROACH**

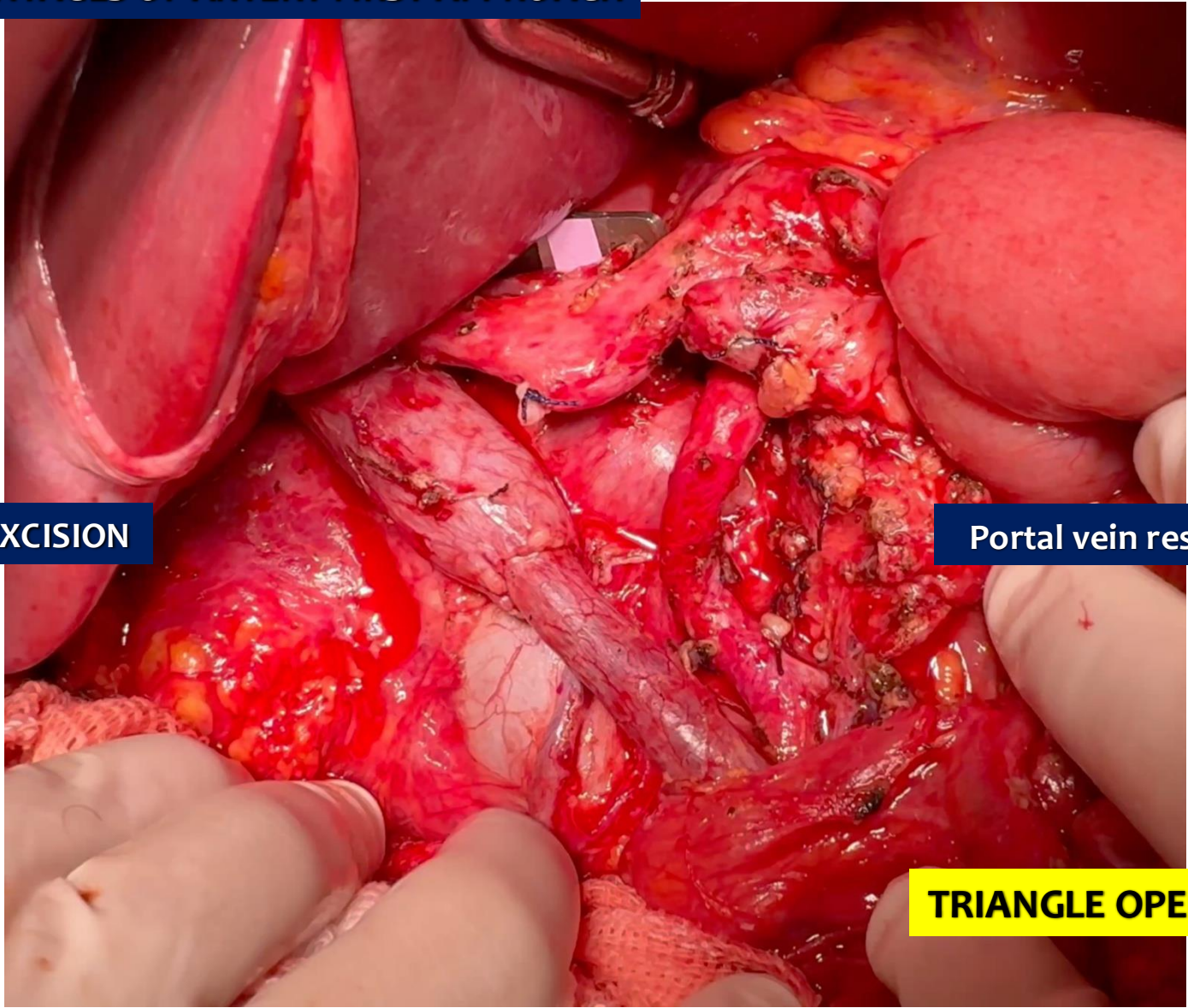


**TOTAL MESOPANCREAS EXCISION**

**Portal vein resection**

**TRIANGLE OPERATION**

**ADVANTAGES OF ARTERY FIRST APPROACH**



**TOTAL MESOPANCREAS EXCISION**

**Portal vein resection**

**TRIANGLE OPERATION**

# Patterns of Recurrence After Resection of Pancreatic Ductal Adenocarcinoma

## A Secondary Analysis of the ESPAC-4 Randomized Adjuvant Chemotherapy Trial

**ESPAC-4**

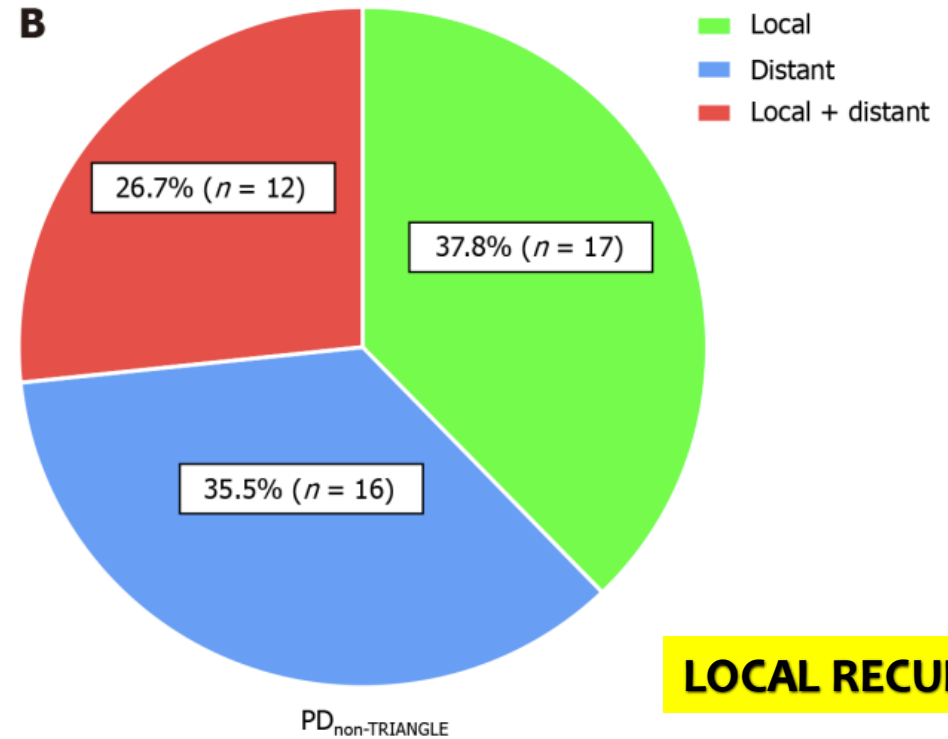
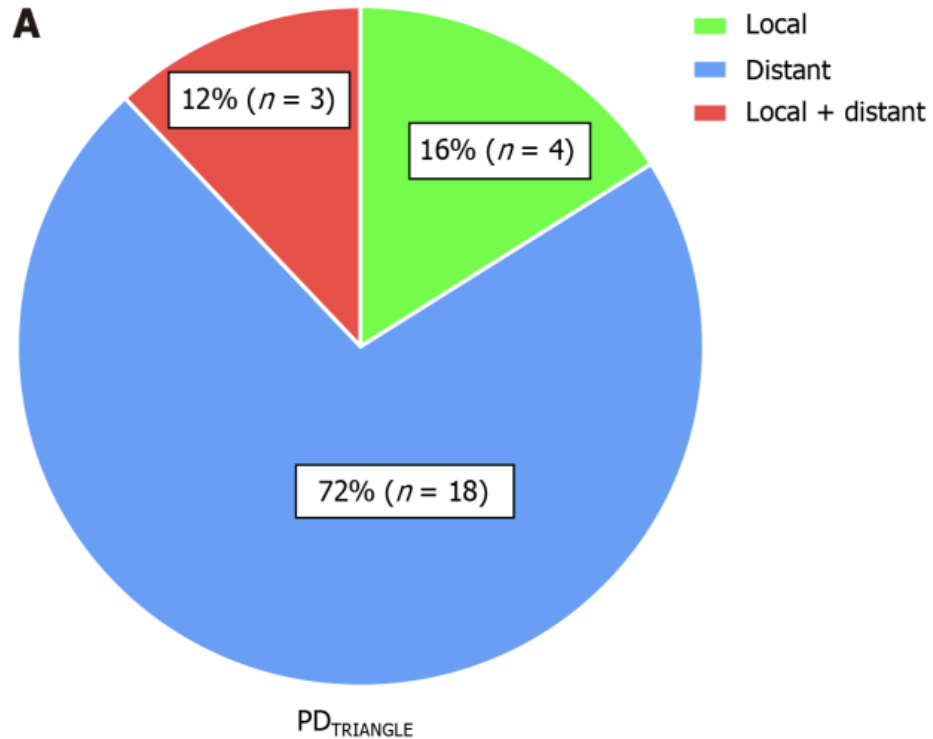
**Table 2. Sites of First Recurrence and Median Overall Survival From Surgery and Median Survival After Diagnosis of Recurrence by Site**

Site of Recurrence	No.	Median (95% CI)		
		Recurrence-Free Survival, mo	Survival After Recurrence, mo	Overall Survival, mo
Local only	238	13.57 (12.61-14.06)	9.36 (8.08-10.48)	24.83 (22.96-27.863)
Local and distant recurrence	48	11.99 (10.28-15.83)	8.11 (5.22-11.79)	23.82 (17.48-28.32)
Distant only	193	11.14 (10.05-12.32)	9.23 (7.82-11.43)	20.61 (18.12-23.80)

**Total: 730**  
**Recorrência 479 (65.6%)**  
**Local 238 (479): 49.7%**  
**Distante 193 40.3%**  
**Simultânea 48: 10.0%**

**DOENÇA RESIDUAL**

# TRIANGLE OPERATION



**LOCAL RECURRENCE**

**Table 3** Advantages of the artery-first approach (SHARMA) [35]

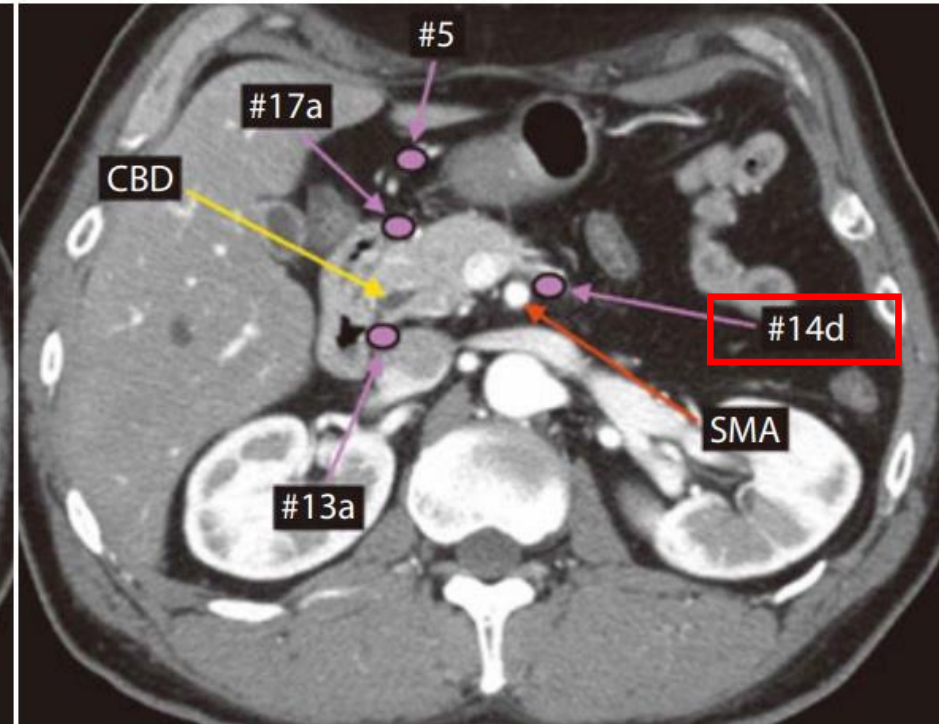
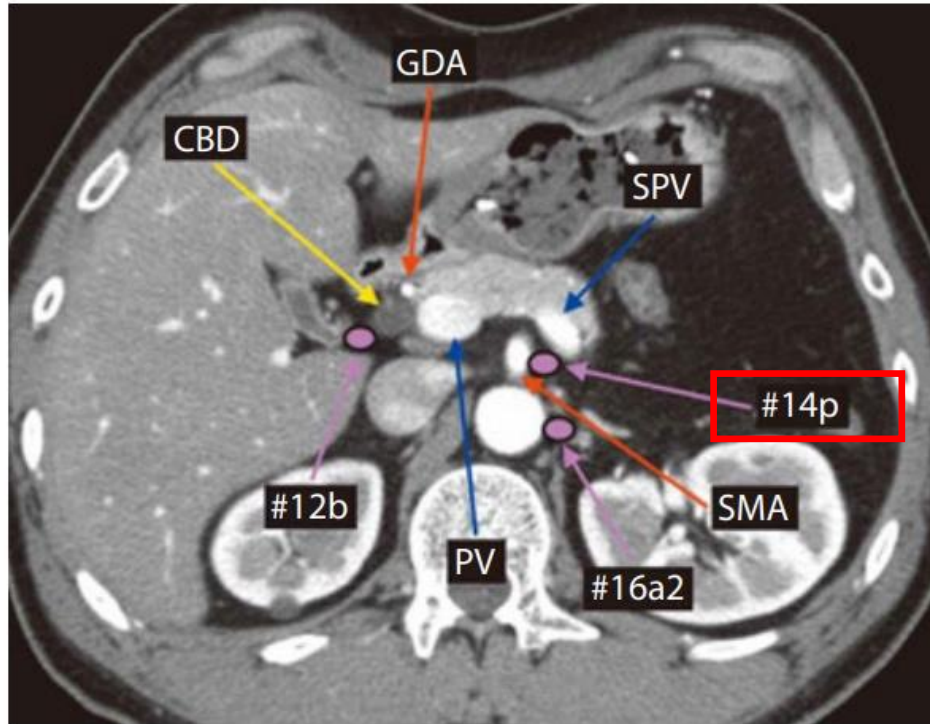
- 
1. Resection without breaching the tumor extension plane, thereby minimizing cell spillage
  2. Increases curative (R0) resection, decreases local recurrence
  3. Complete resection of peripancreatic retroperitoneal tissue around the plexuses
  4. Increased lymph nodal clearance
  5. Early assessment of non-resectability (SMA involvement), avoiding useless R2 resections
  6. Better delineation of SMA and identification of RHA anomalies
  7. Easier en bloc resection and reconstruction of SMV-PV by “no touch” technique
  8. Reduced need for graft substitutions
  9. Reduced operative time and blood loss (early ligation of IPDA/JA1)
- 

**LYMPH NODES**

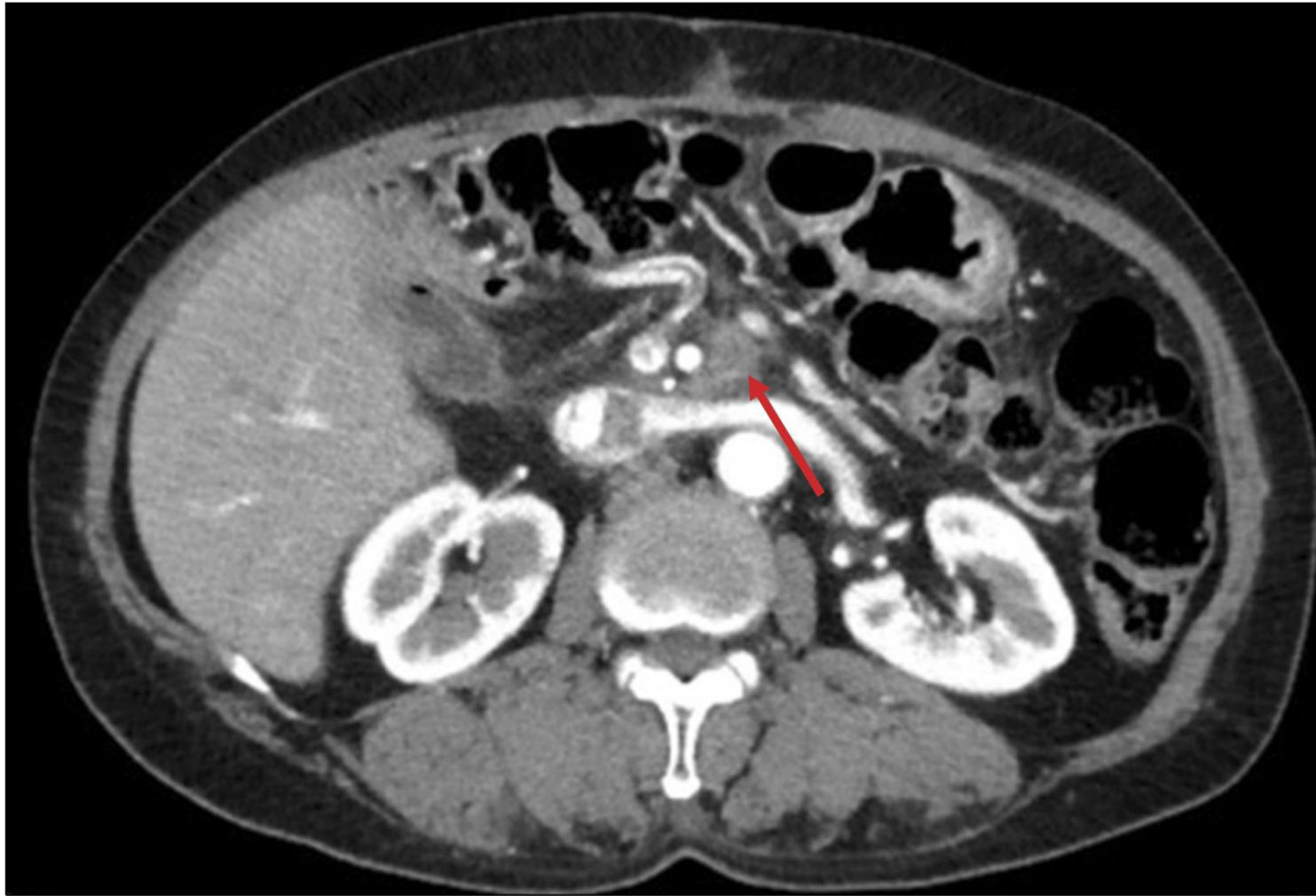**ARTERY FIRST**

# LYMPHADENECTOMY

# RIGHT SIDE OF SMA ?

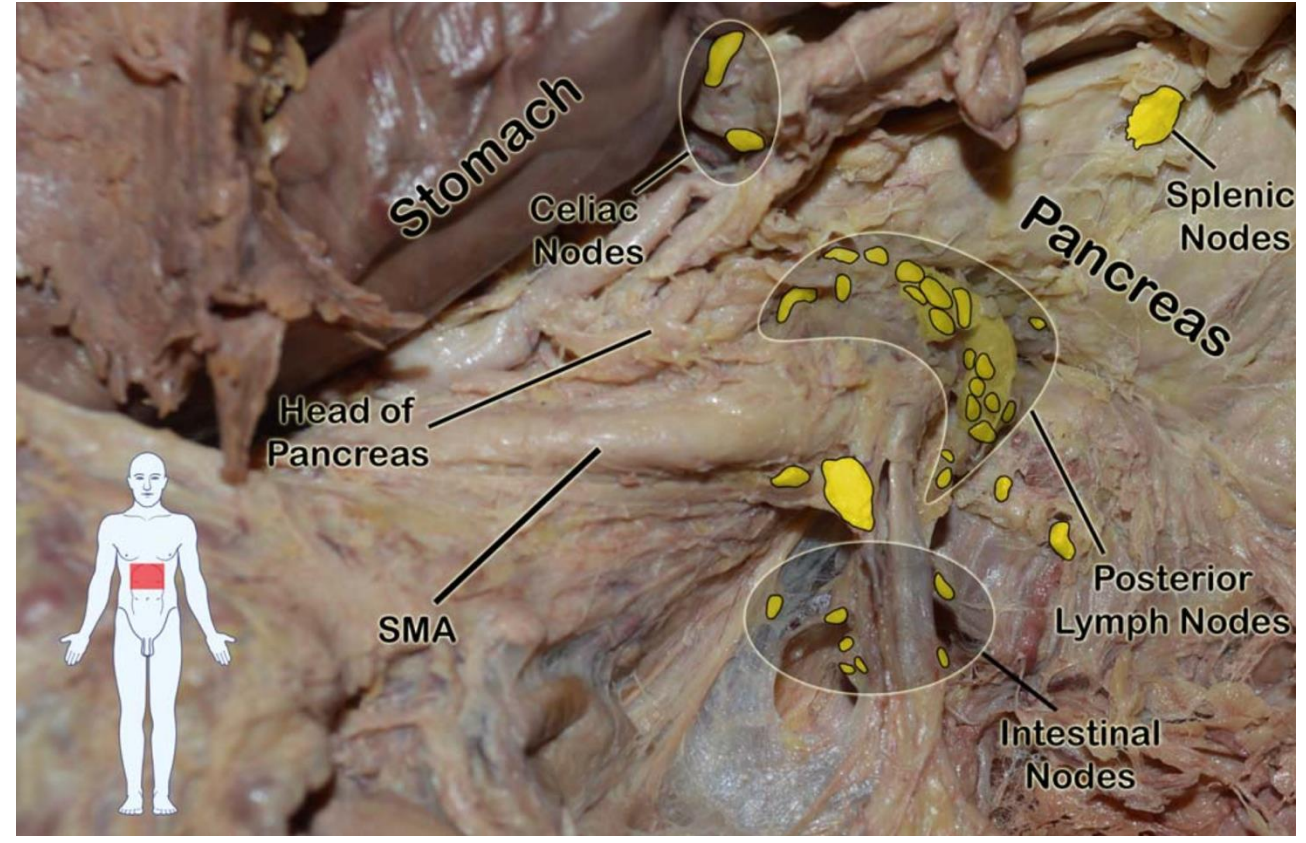
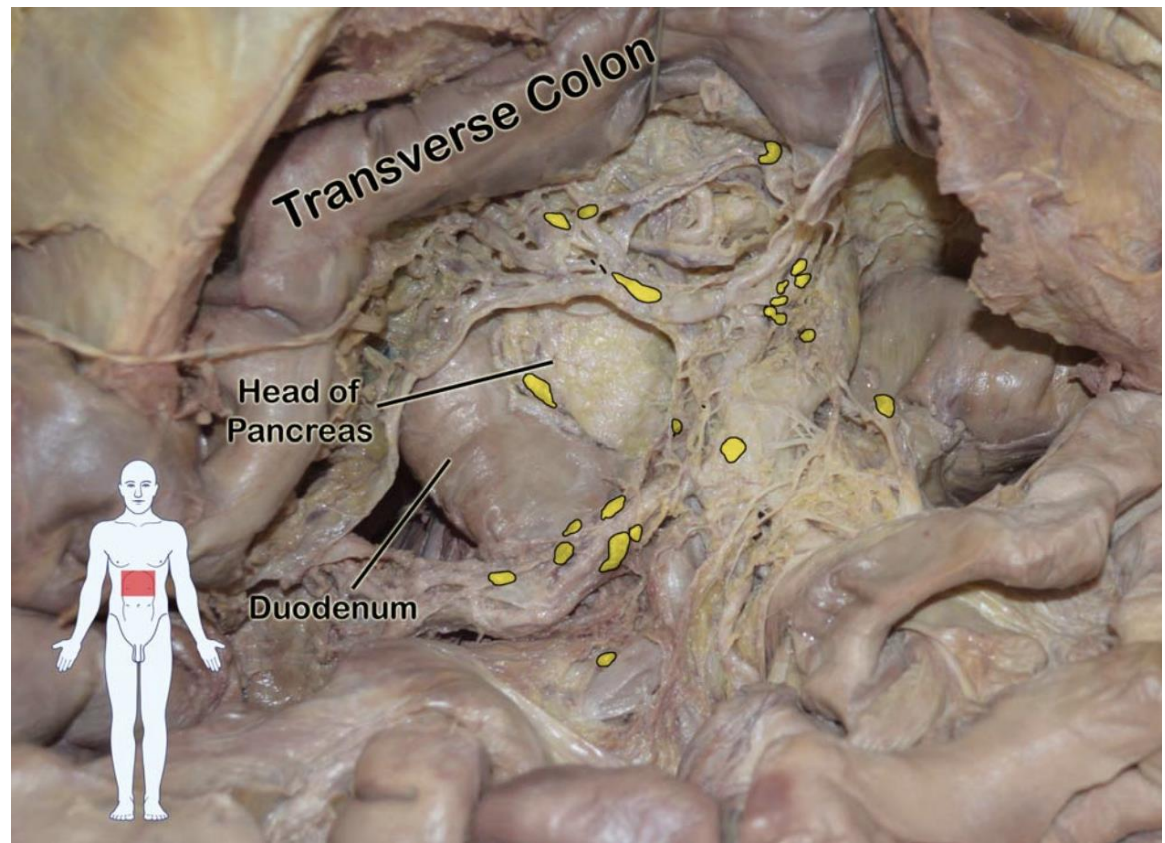


14p, 14d



**Fig. 1.** Nodal type local recurrence of pancreatic head cancer on the left side of SMA.

# LYMPHADENECTOMY





## Complete Lymphadenectomy Around the Entire Superior Mesenteric Artery Improves Survival in Artery-First Approach Pancreatoduodenectomy for T3 Pancreatic Ductal Adenocarcinoma

### ARTERY FIRST

**Table 2** Comparison of perioperative and oncological outcomes between the AFA-PD group and the conventional PD group

	AFA-PD group	Conventional PD group	<i>P</i>
	<i>n</i> = 45	<i>n</i> = 43	
Operative time, median (range), min	443 (390–497)	467 (414–530)	0.1312
Intraoperative blood loss, median (range), mL	811 (520–1150)	899 (720–1443)	<b>0.0210</b>
Transfusion, <i>n</i> (%)	19 (42.2)	22 (51.2)	0.5178
Portal vein resection, <i>n</i> (%)	12 (26.7)	13 (30.2)	0.8147
Postoperative complications, $\geq$ grade IIIa, <i>n</i> (%)	3 (6.7)	5 (11.6)	0.4794
Curative resection R0, <i>n</i> (%)	35 (77.8)	28 (65.1)	0.3423
No. harvested lymph nodes, median (range)	23 (14–37)	19 (12–22)	<b>0.0165</b>
No. harvested lymph nodes of #14p, median (range)	4 (2–5)	1 (0–3)	<b>&lt; 0.001</b>
No. harvested lymph nodes of #14d, median (range)	4 (2–5)	2 (0–3)	<b>0.0146</b>
Lymph node metastasis, <i>n</i> (%)	27 (60)	30 (69.8)	0.3376

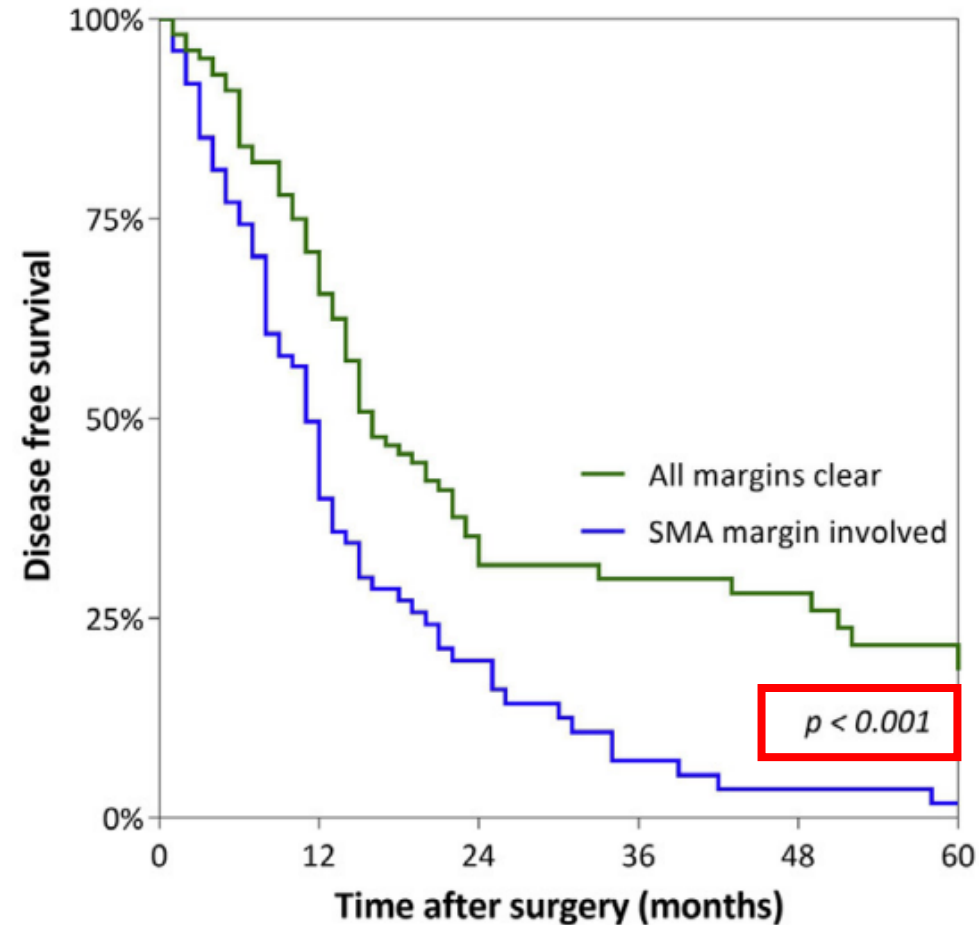
Bold values are statistically significant ( $p < 0.05$ )

AFA-PD - Artery first approach pancreatoduodenectomy

ORIGINAL ARTICLE

# Recurrence patterns of pancreatic cancer after pancreatoduodenectomy: systematic review and a single-centre retrospective study

**d - SMA margin clearance & disease free survival**





Contents lists available at ScienceDirect

International Journal of Surgery

journal homepage: [www.elsevier.com/locate/ijss](http://www.elsevier.com/locate/ijss)



Review

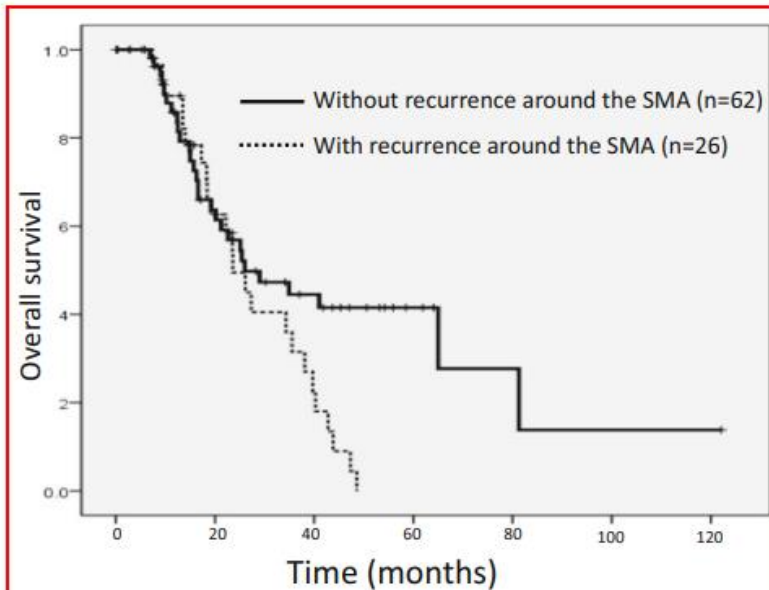
Superior mesenteric artery first approach can improve the clinical outcomes of pancreaticoduodenectomy: A meta-analysis



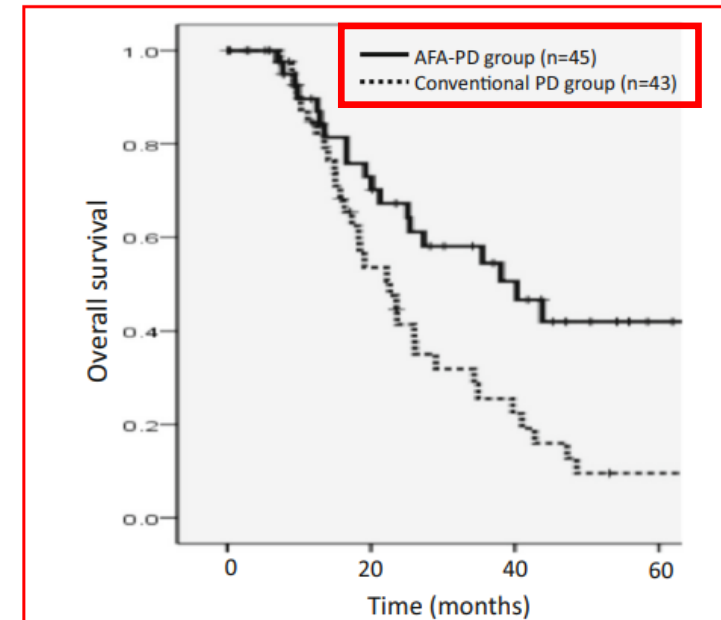
- Higher R0 resection rate ( $p < 0.001$ )
- Lower local recurrence rate ( $p < 0.0001$ )
- Higher overall survival:
  - 1-year  $p = 0.015$
  - 2-year  $p = 0.005$
  - 3-year  $p = 0.001$

Meta-analysis - 18 studies

## Complete Lymphadenectomy Around the Entire Superior Mesenteric Artery Improves Survival in Artery-First Approach Pancreatoduodenectomy for T3 Pancreatic Ductal Adenocarcinoma



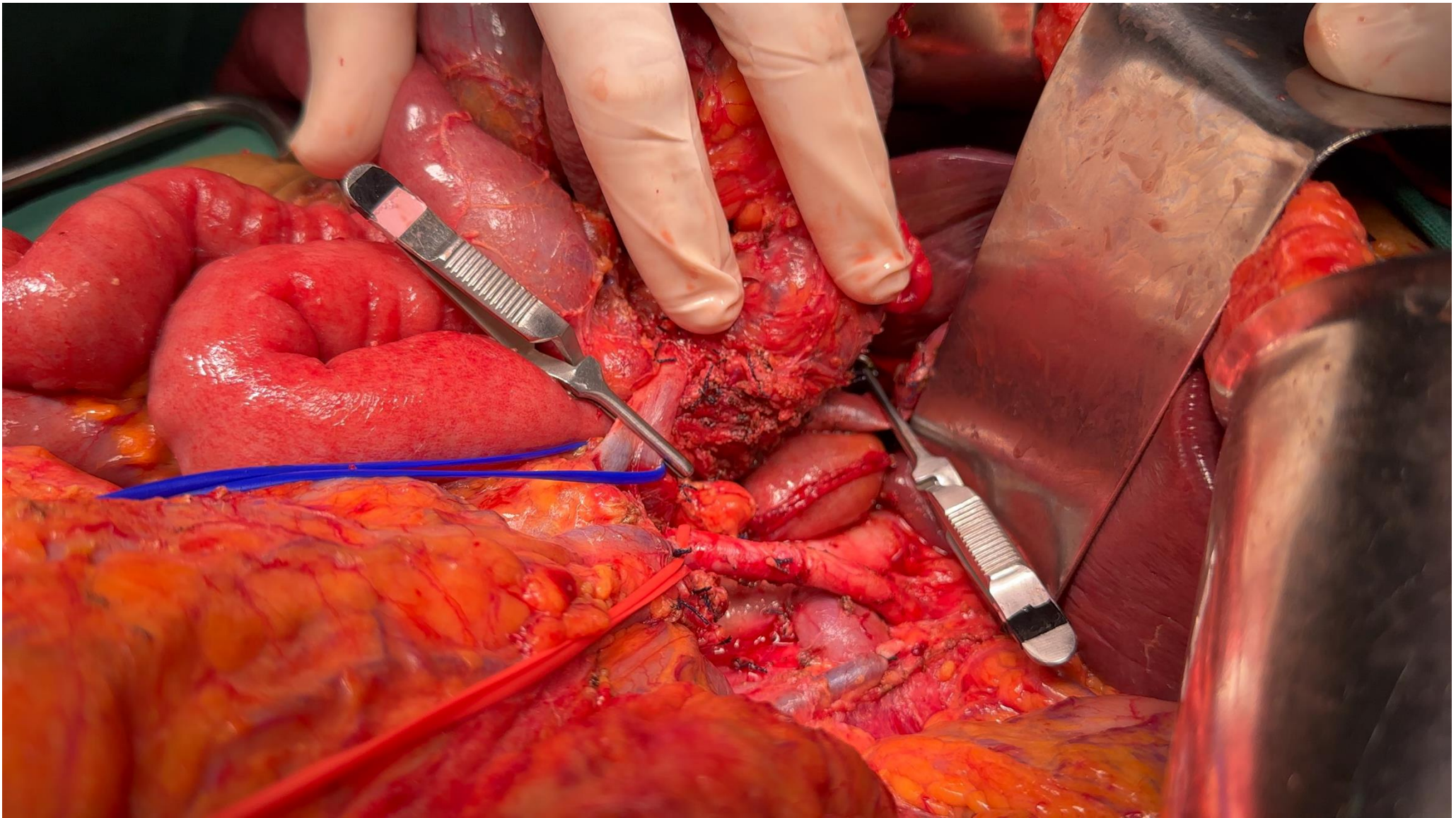
**Fig. 1** Overall survival according to recurrence around the SMA. The median survival was 23.6 months in patients with recurrence around the SMA and 26 months in patients without recurrence around the SMA ( $p = 0.0367$ ) SMA: superior mesenteric artery



**Fig. 2** Overall survival according to the type of the surgery. The median survival was 40.3 months in the AFA-PD group and 22.6 months in the conventional PD group ( $p = 0.005$ ) AFA-PD: artery-first approach pancreatoduodenectomy

40.3 months vs 22.6 months ( $p = 0.005$ )

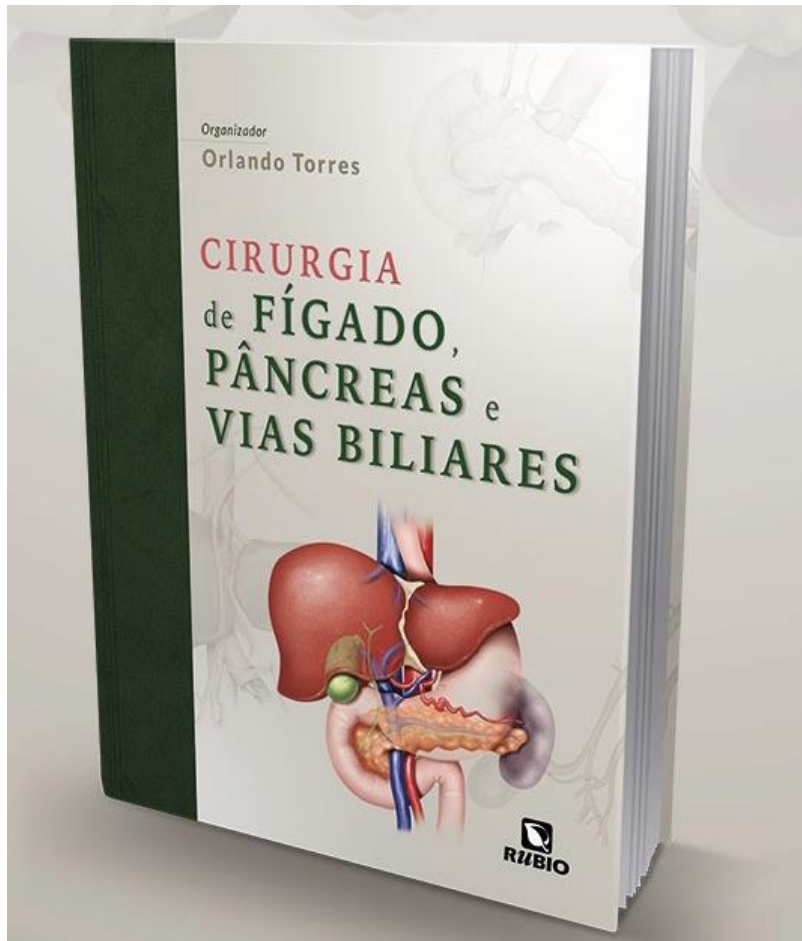
OVERALL SURVIVAL



**Portal vein/superior mesenteric vein resection/reconstruction**

## CONCLUSIONS

- ❑ Radical resection with adequate regional lymphadenectomy and radical resection around the large peri-pancreatic vessels is an important prerequisite for good oncological outcomes.
- ❑ High-quality radical surgery and modern adjuvant therapy, defined by lymph node resection and margin status, has a profound impact on survival.
- ❑ In modern pancreatic surgery, radical resections can be facilitated and achieved by several techniques, including **artery-first** approaches, a **level-3 dissection** around the arteries, the **TRIANGLE operation**, and extended resections, including **vascular resection**.



[www.drorlandotorres.com.br](http://www.drorlandotorres.com.br)

Obrigado!

## Lençóis Maranhenses



 [orlandotorres\\_gastrocirurgia](https://www.instagram.com/orlandotorres_gastrocirurgia)